



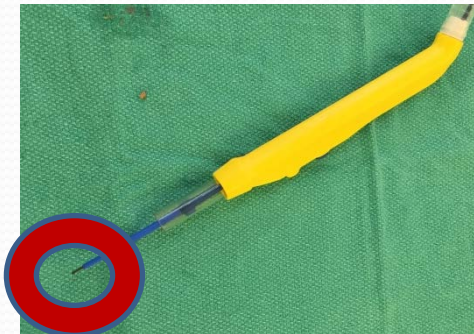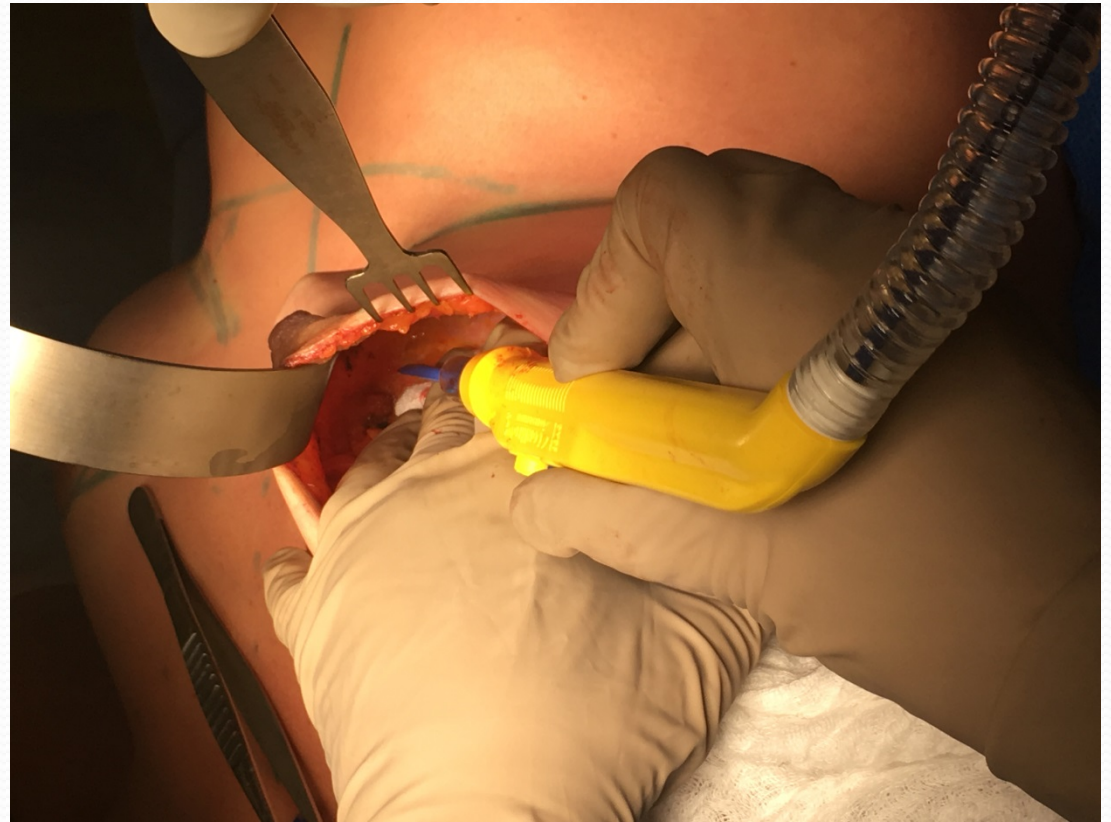
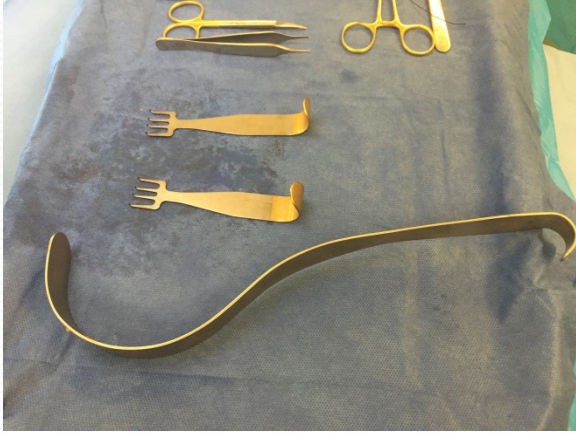
Elaine McKevitt

Oct 22 2016

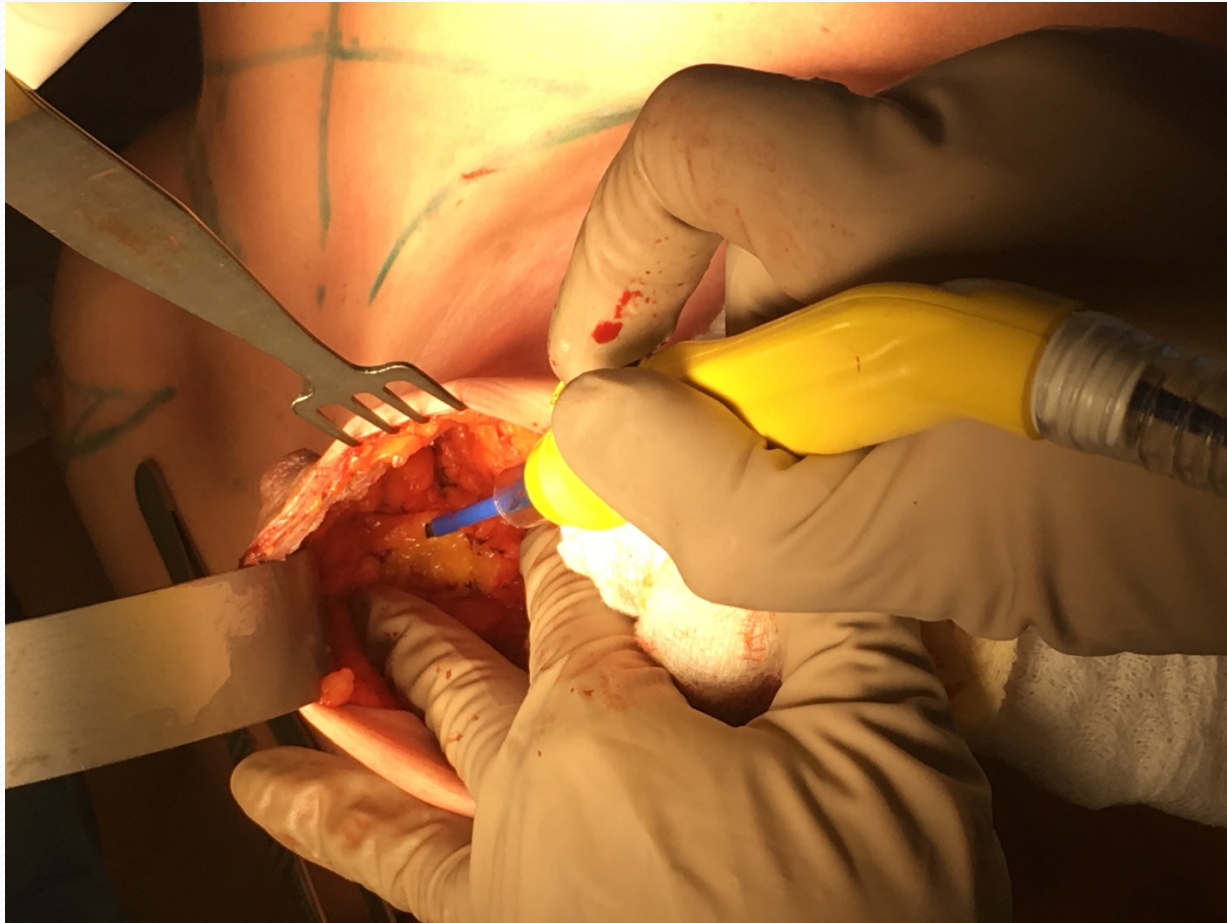Nipple Sparing Mastectomy

- Procedure:
 - Same procedure, same boundaries
 - but through a small incision
- Who?
 - Anticipate a clear margin
 - Reconstructive considerations
- Tips and Tricks

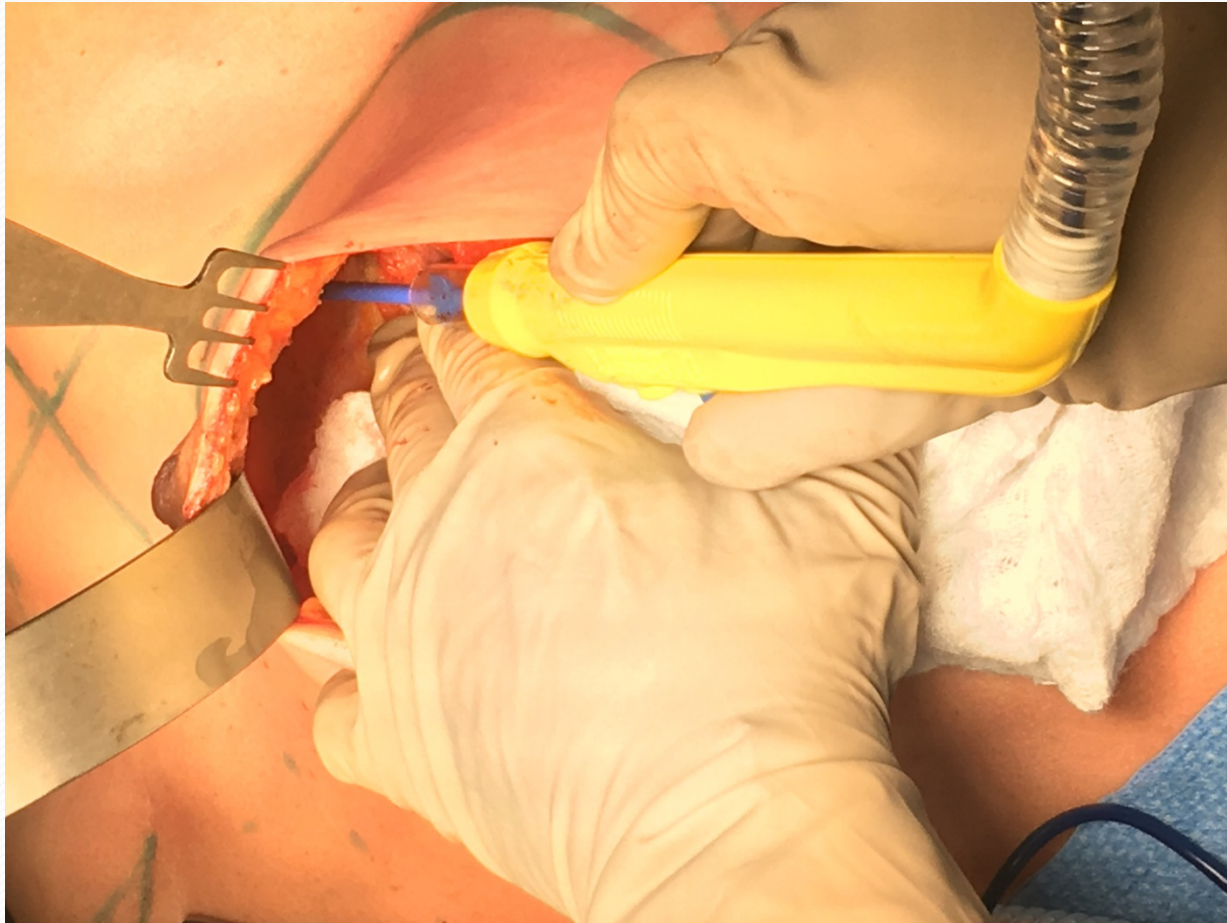Gentle with the flaps



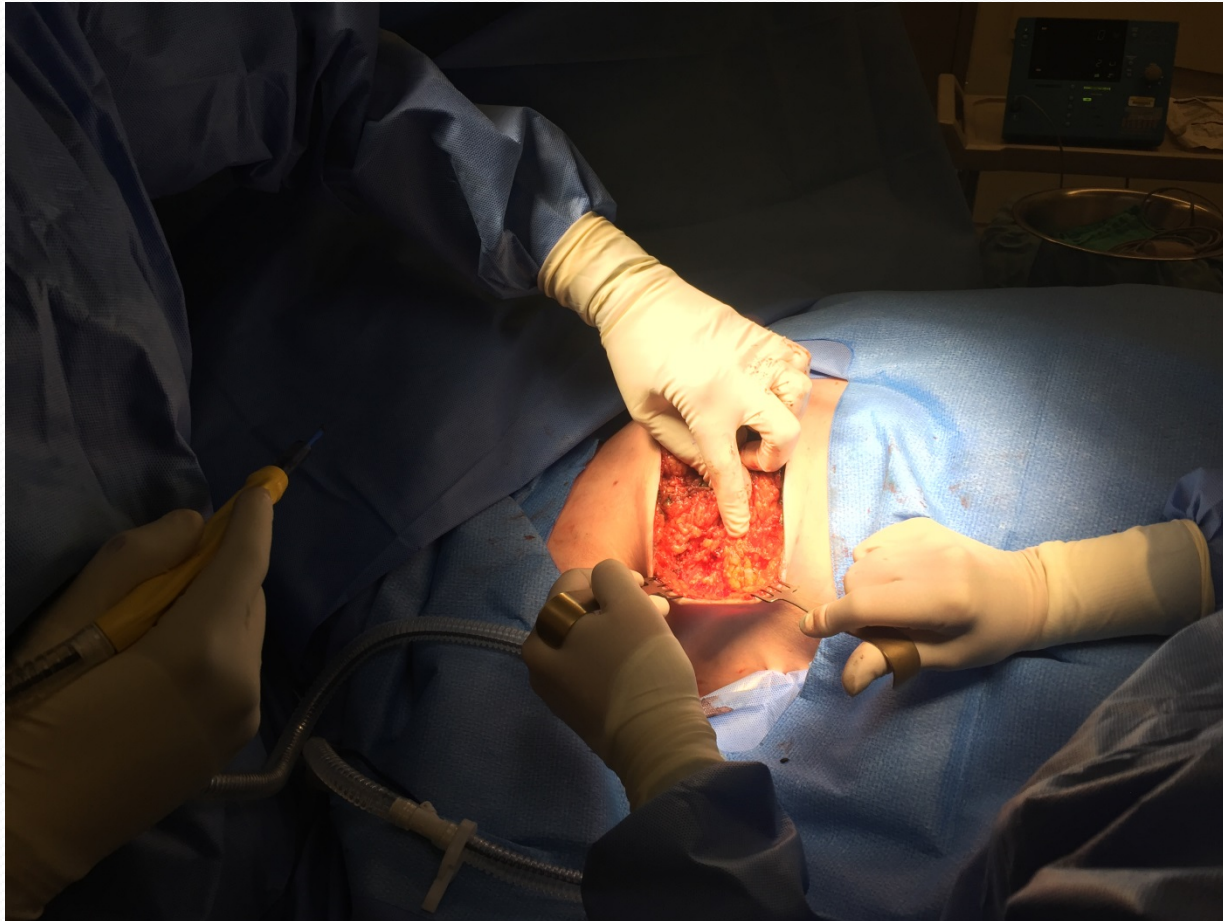1. Leave nipple ducts initially



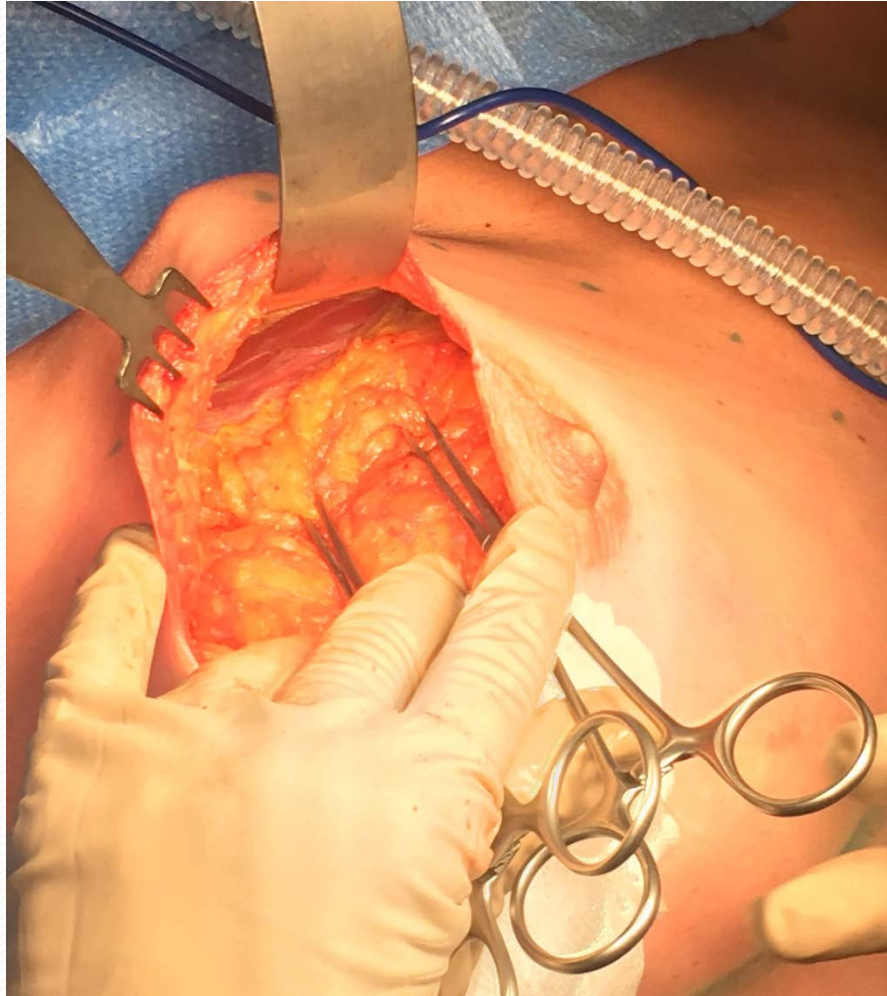2. Preserve the IMF



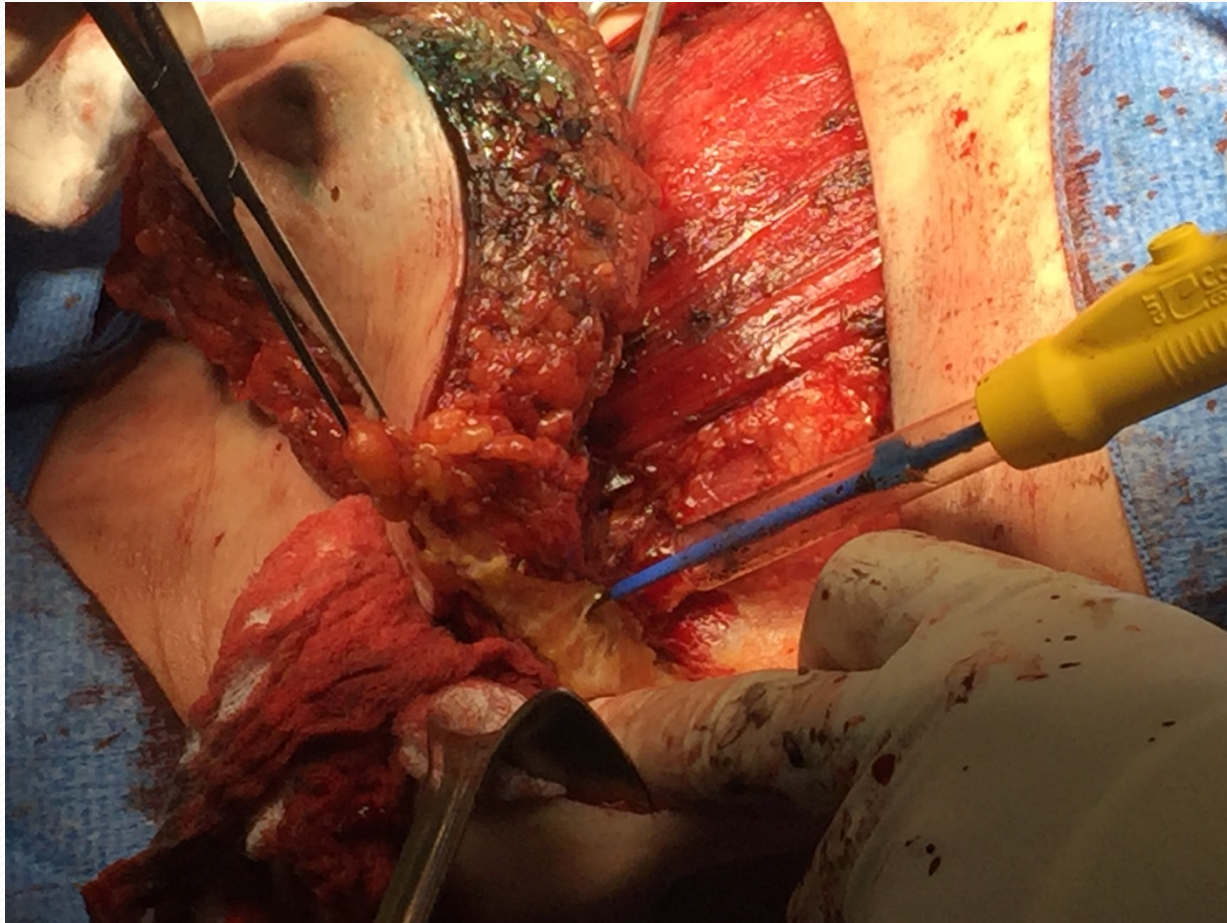
3. Define LOQ from above



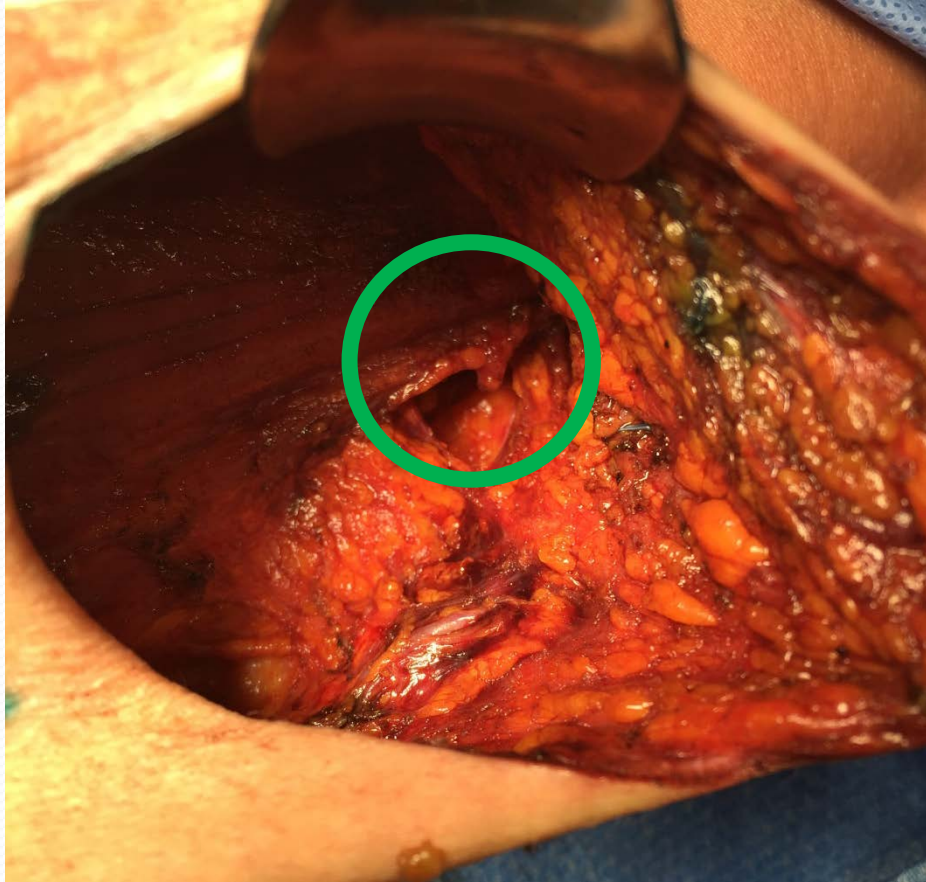
4. Remove the breast starting superior



5. There is a plane laterally

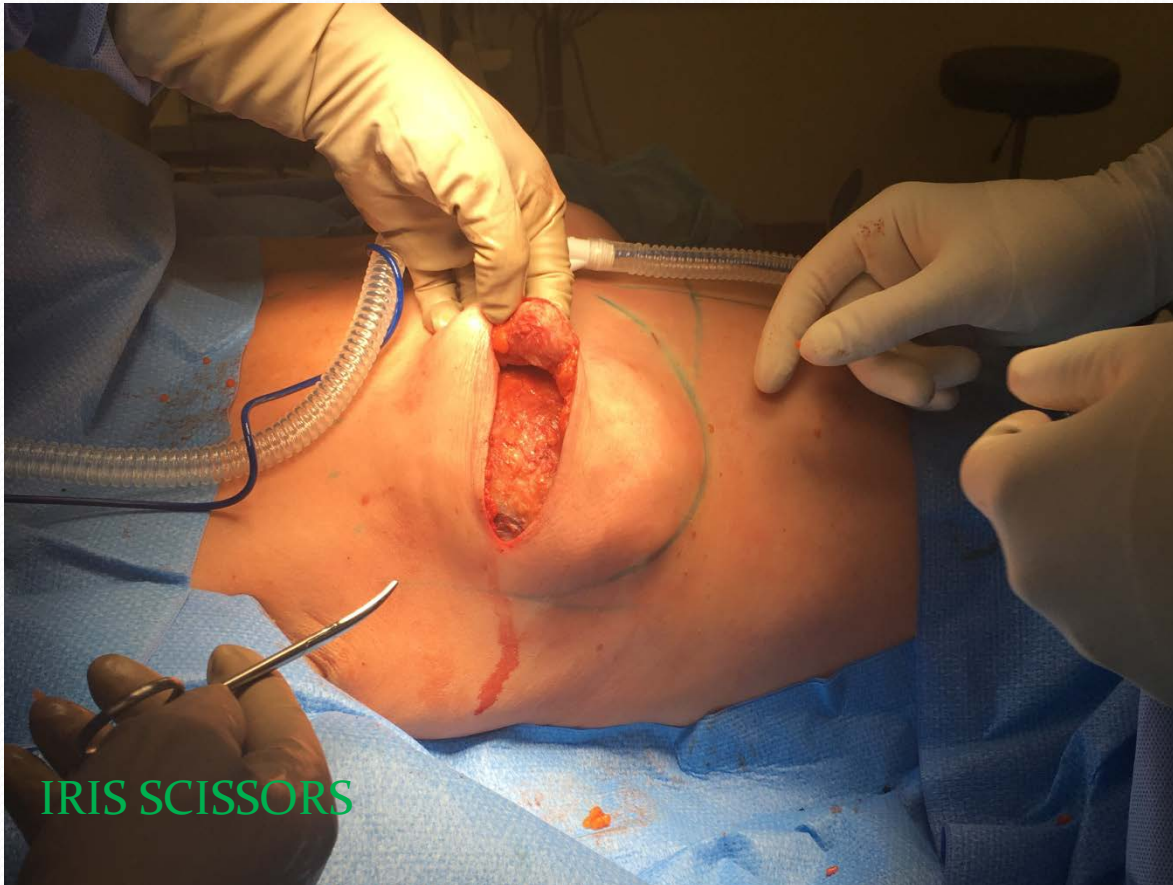

Axillary Procedure

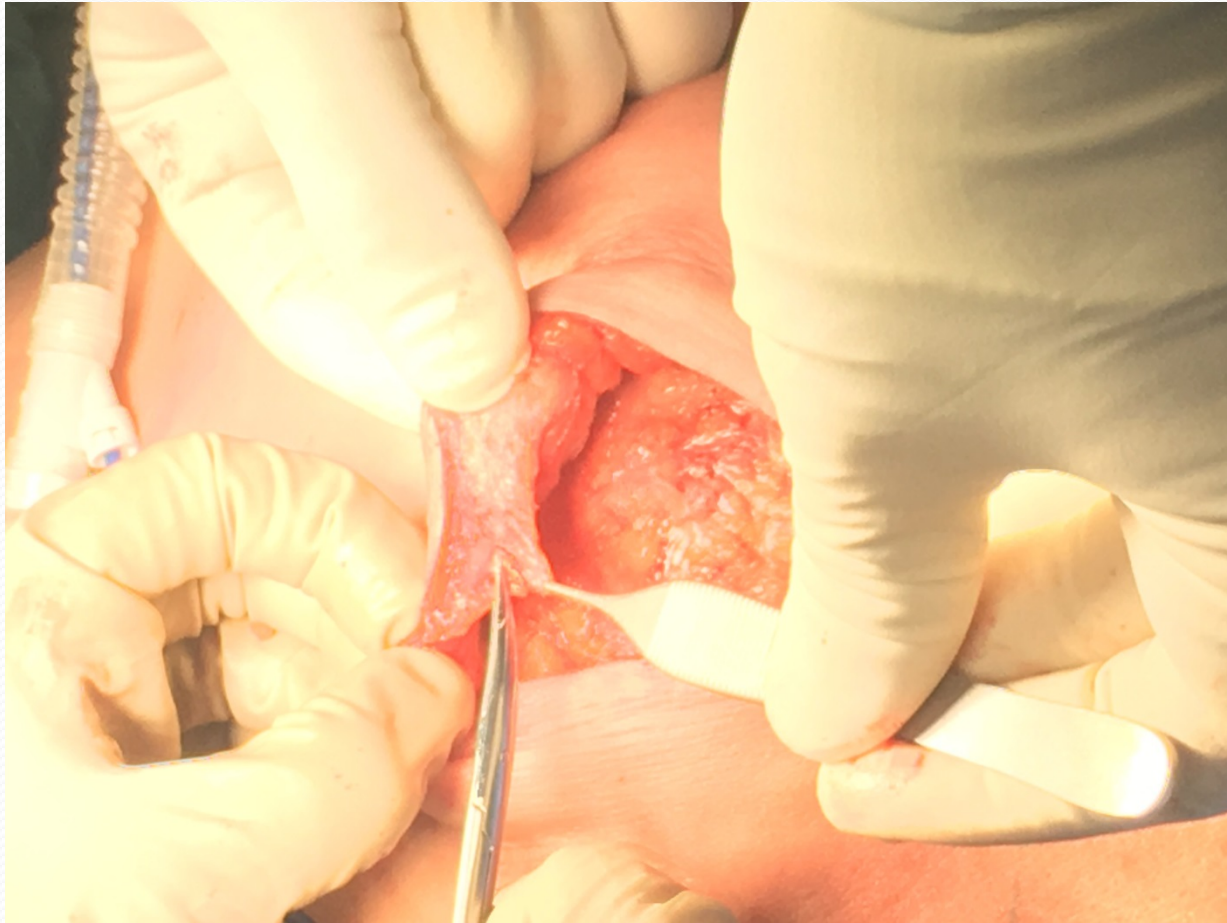

May need another incision in the axilla

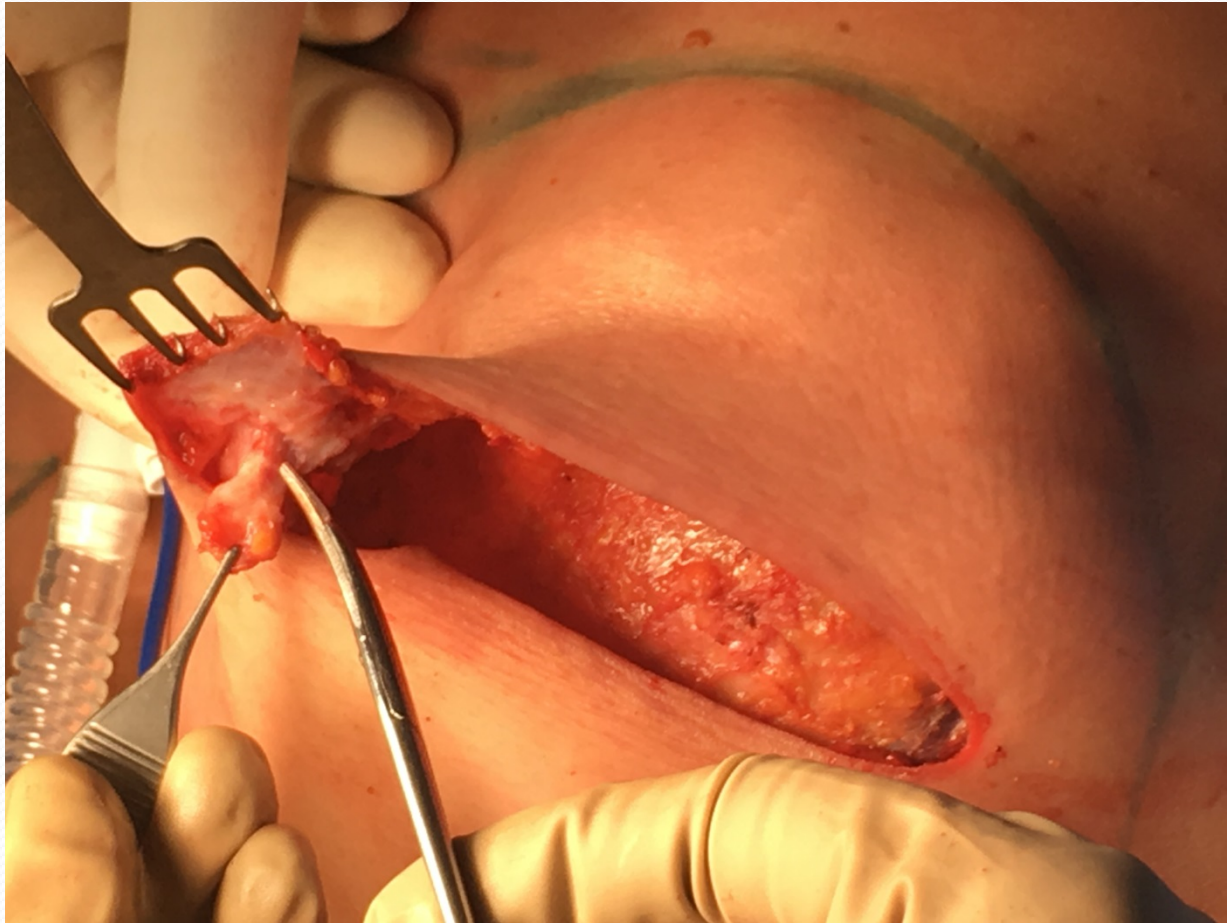
The nipple core



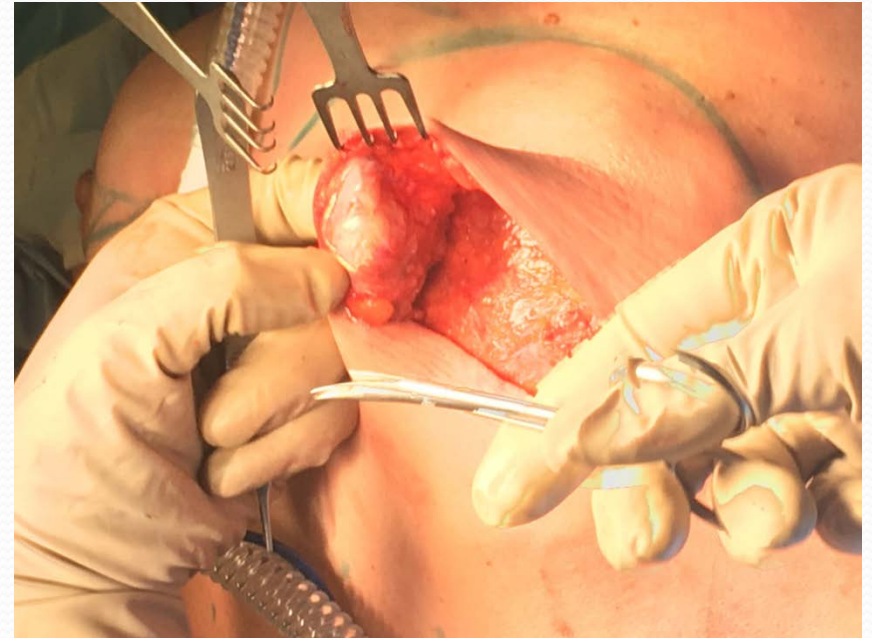
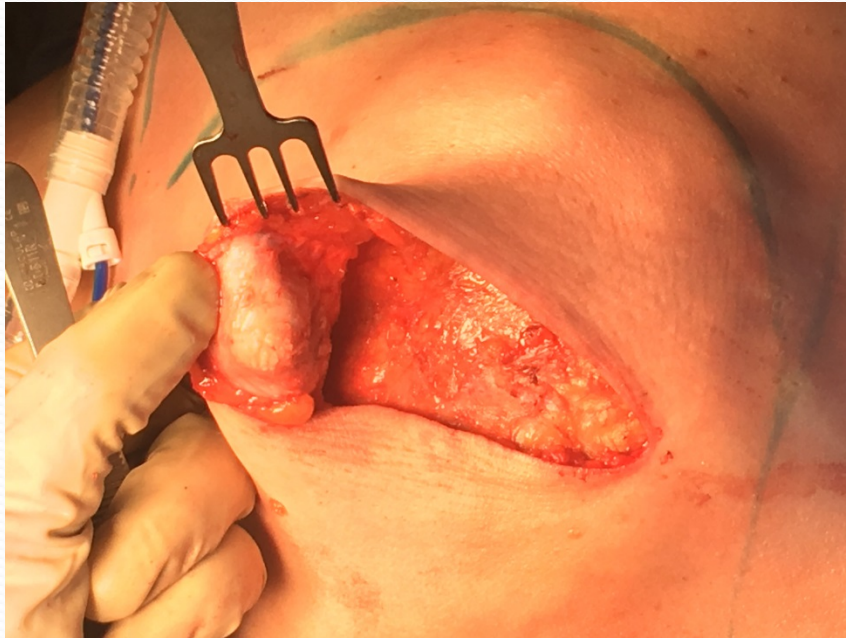
Divided under nipple during mastectomy



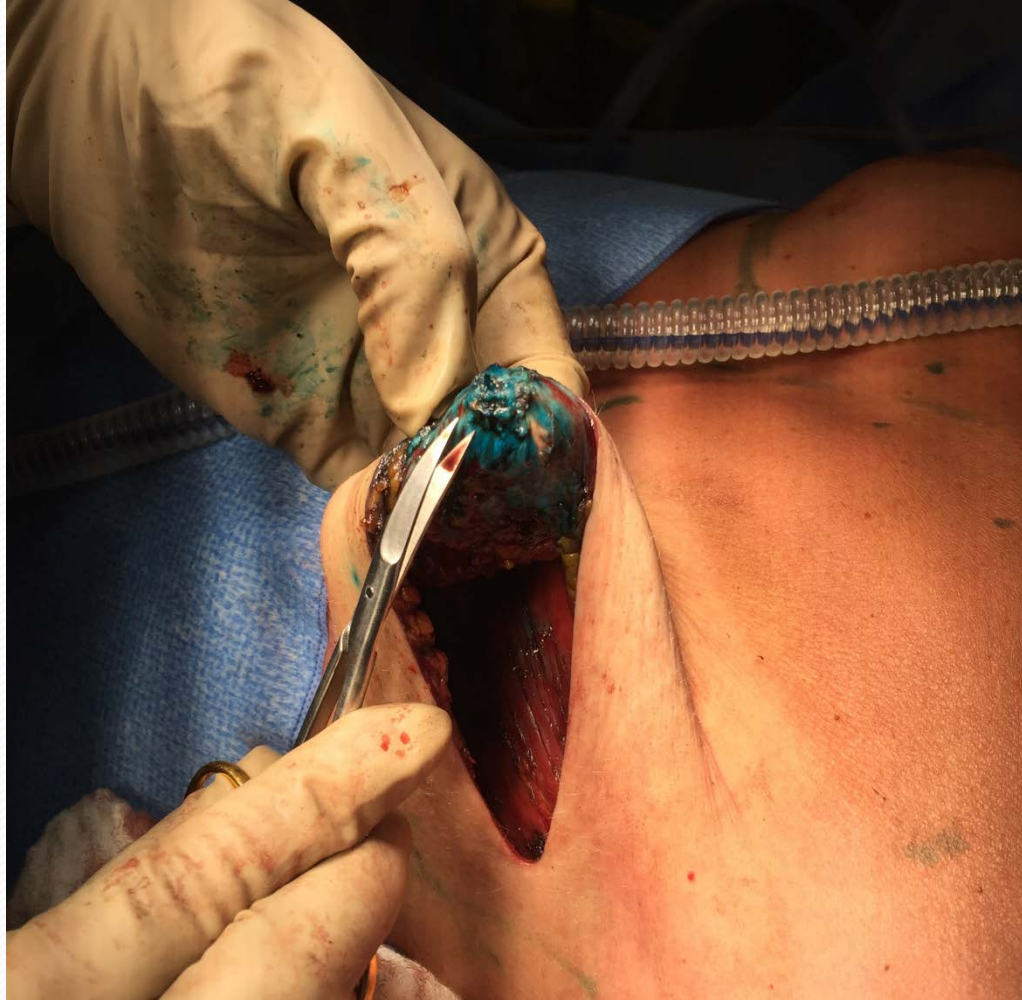Plane between ducts and skin



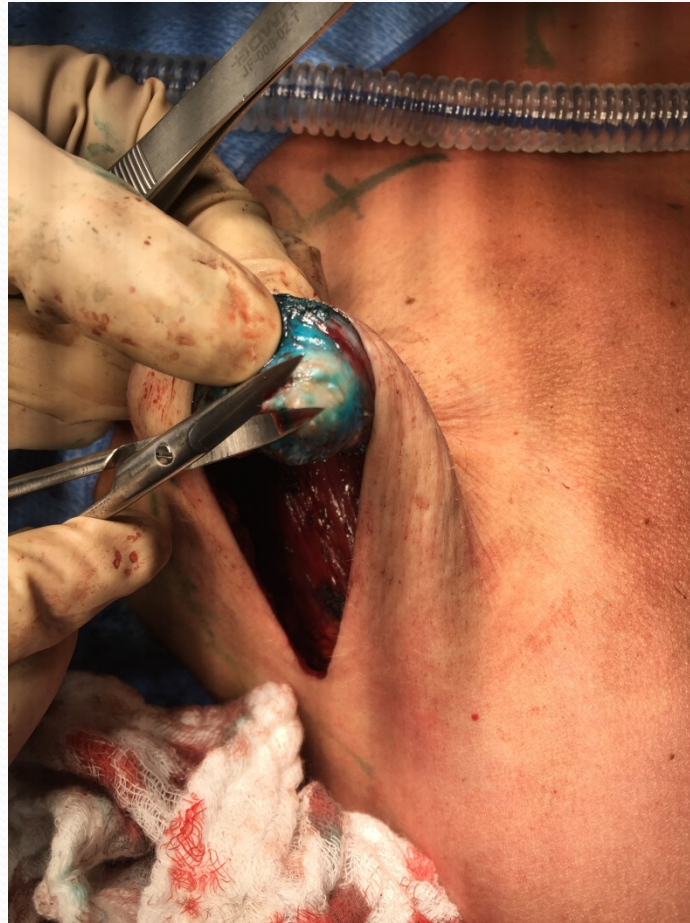Trim the duct ends



Plane between ducts and skin



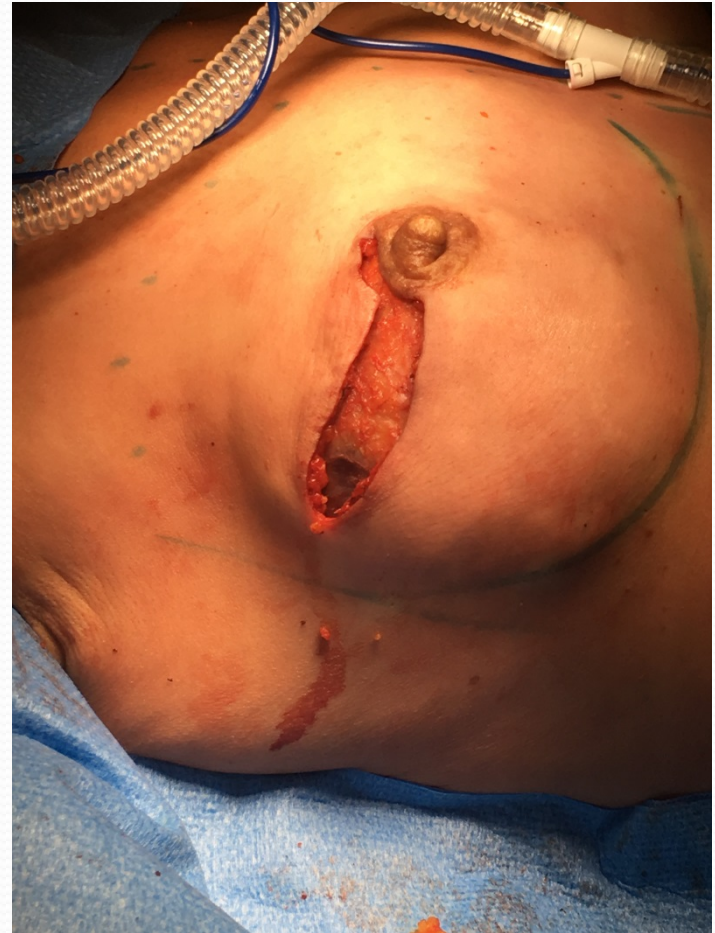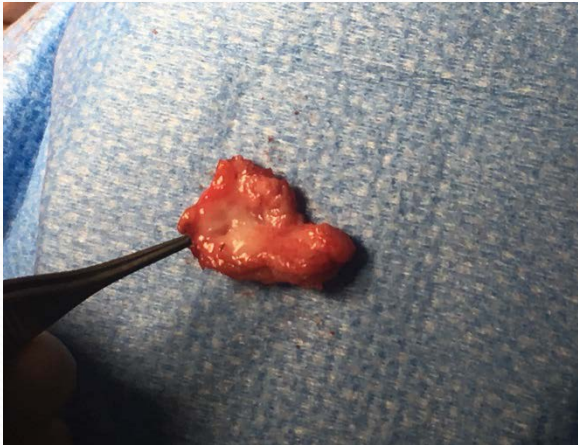Trim duct ends



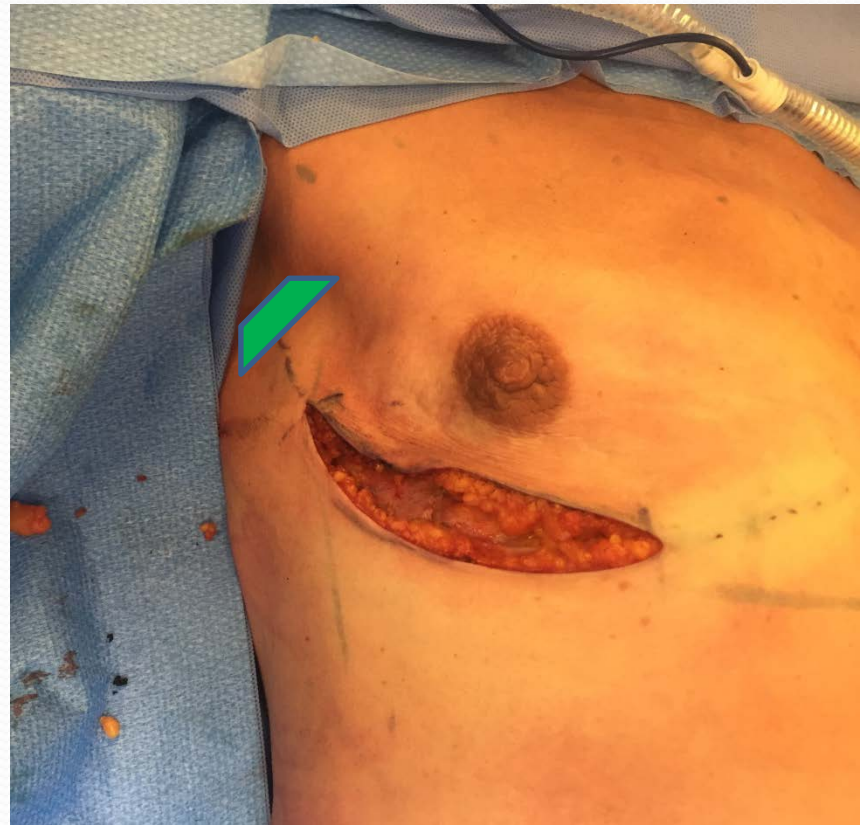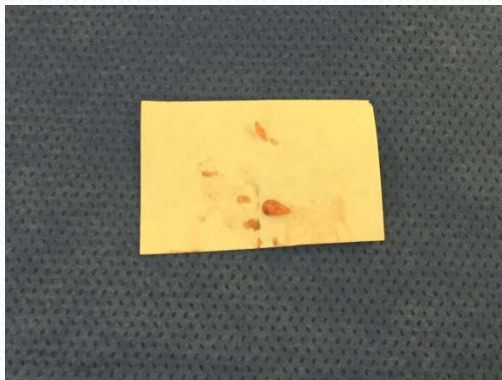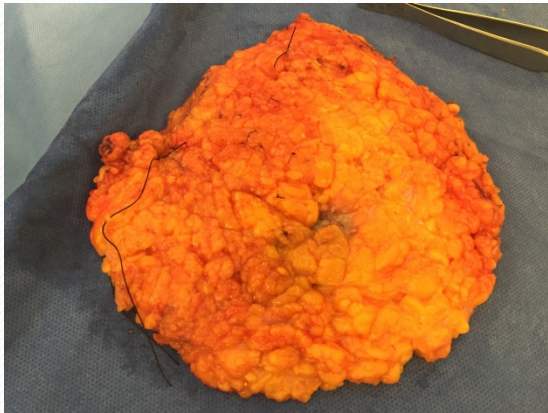


Putting it all together

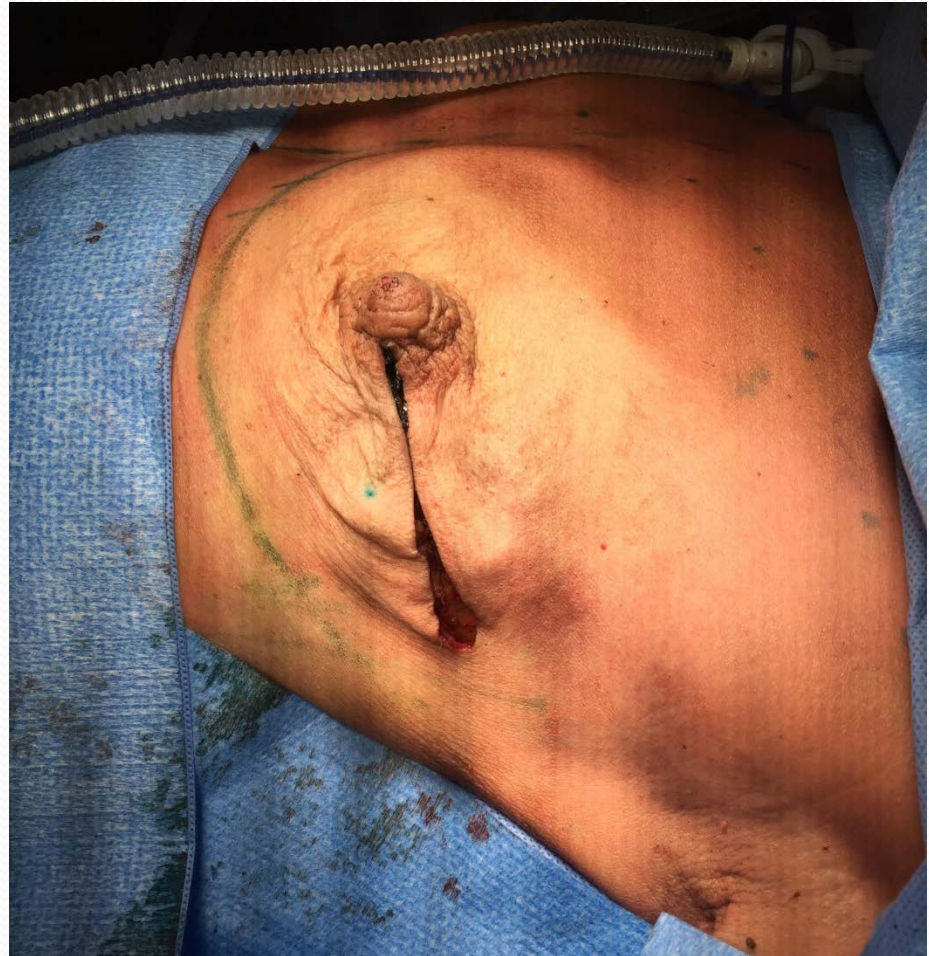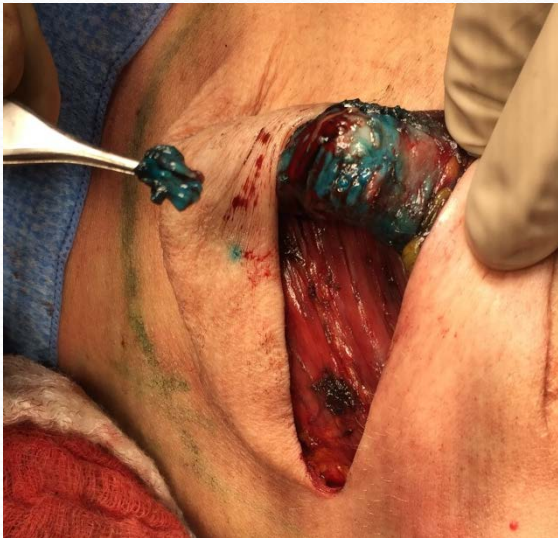
Radial/areolar incision



IMF Incision



Radial to nipple





Thank you