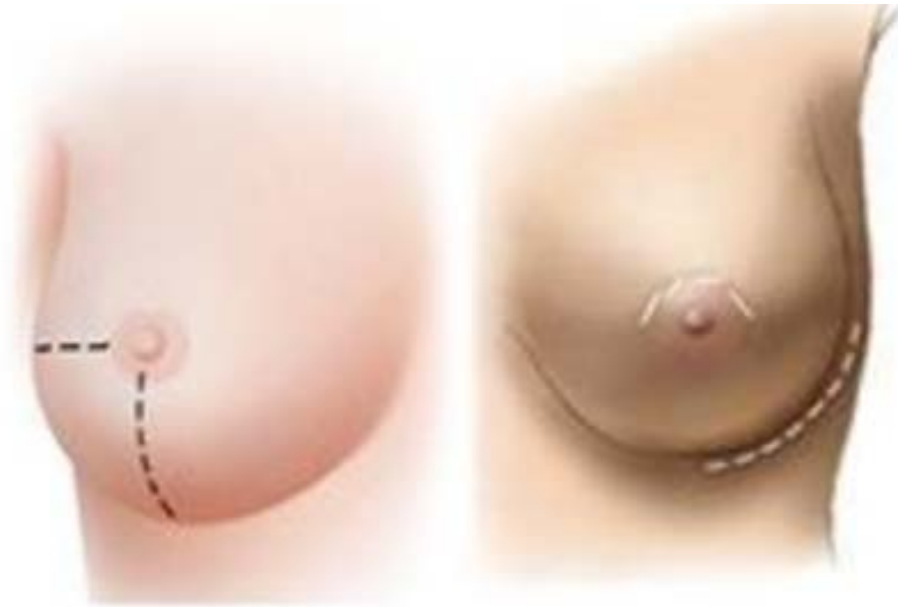



Nipple Sparing Mastectomy: Tips & Tricks

Rebecca Nelson, MD MSc FRCSC
Plastic & Reconstructive Surgeon, Burnaby Hospital





Nipple Sparing Mastectomy (NSM)

- Introduction & Technique
- Safety
- Evidence
- Indications/Contraindications
- Dr. Elaine McKevitt/Dr. Connie Chiu/Dr. Esta Bovil



What is NSM?

- Combines skin sparing mastectomy with preservation of the nipple areolar complex (NAC)
- Removal of all visible breast tissue
- Subnipple ductal tissue is submitted separately for histologic evaluation
 - Frozen
 - Permanent
- By salvaging the nipple and areolar skin, we provide **enhanced cosmesis to the patient and preservation of "normal" anatomy**



Patients undergoing NSM...

- Perceive that NSM affords them better ability to cope with the trauma of having breast cancer
 - Didier F et al. Br Canc Res Treat 2009;118:623-33
- Have significantly higher reported rates of psychosocial well being and sexual well being, compared with skin sparing mastectomy patients
 - Wei CH et al. Breast J. 2016 Jan-Feb;22(1):10-7.
 - No difference in scores for physical well-being, satisfaction with breast, or satisfaction with outcome



Safety Considerations

- Traditional teaching suggests the NAC should be removed:
 - to decrease the risk of local recurrence in the ductal tissue beneath it
 - Because it may promote lymphatic spread via centripetal drainage patterns extending from the subareolar plexus
- Multiple series have looked at NAC involvement in mastectomy specimens
 - Rates range from 0-58%
 - Significant variability in studies prevents an accurate number



Safety Considerations

Study	Study Type	N	Results
Headon et al. Arch Pl Surg 2016;43:328-38	Systematic review	12,358 mastectomies	LRR: 2.38% Compl: 22% NN: 5.9%
De La Cruz et al. Ann Surg Onc 2015;3222:3241– 3249	Systematic review & Meta-analysis	4663 patients	No difference in LR, OS and DFS for NSM vs. SSM/MRM
Orzalesi et al. Breast 2016;25;75- 81	Retrospective review (national NSM database)	1006 mastectomies	LRR: 2.9% NAC removal: 11.5% Major comp: 4.4%



Safety Considerations

TABLE 2 Oncologic outcomes of nipple-sparing mastectomy for cancer

Study	Year	N ^a	Median follow-up (months)	Local recurrence	
				Flap not NAC (%)	NAC (%)
Krajewski ⁴	2015	236	24	1.7	0
Eisenberg ⁵²	2014	208	33 (mean)	0.5	0.5
Sakurai ³⁷	2013	788	78	8.2	3.7
Coopey ²	2013	315	22	2.6	0
Peled ³⁴	2012	412	28	2	0
Spear ³³	2011	49	30 (mean)	0	0
Kim ³⁸	2010	152	60	2	1.3
Sakamoto ⁵³	2010	89	52	0	0
Gerber ³⁶	2009	60	101 (mean)	11.7	1.7
Crowe ⁵⁴	2008	58	41	1.7	0
Sacchini ⁵⁵	2006	68	24	2.9	0

NAC nipple-areolar complex

^a Number of breasts with cancer



Factors predicting involvement of the NAC

- Tumour distance from nipple
- Tumour size
- Nodal involvement

Brachtel E et al. J Clin Oncol. 2009;27:4948–54.



The evidence

- No RCTs exist, however the number of publications on nipple sparing mastectomy has risen substantially in the past 5 years
 - Prospective studies ongoing
 - Nipple Sparing Mastectomy Registry
 - American Society of Breast Surgeons



Indications for NSM

- Prophylactic mastectomies
 - Carriers of BRCA genes or other genetic conditions predisposing patients to breast cancer
 - Contralateral side during a bilateral mastectomy

- Therapeutic mastectomies
 - Node negative
 - No evidence of nipple involvement on clinical exam/imaging
 - Nonsmoker
 - Tumour size (≤ 3 cm)
 - Tumour distance from nipple ≥ 2 cm



Contraindications

RELATIVE

- Tumours \leq 2 cm of the nipple
- Extensive DCIS
- Multicentric tumours
- Node positive
 - Would consider performing NSM if good response to neoadjuvant treatment
- Breasts with significant ptosis or large breasts
- Active smokers
- Obesity
- Prior breast surgery
- History of breast irradiation

ABSOLUTE

- T4 cancers
- Inflammatory breast cancer
- Paget's disease
- Tumours with clinical or radiologic evidence of nipple involvement, or pathologic nipple discharge



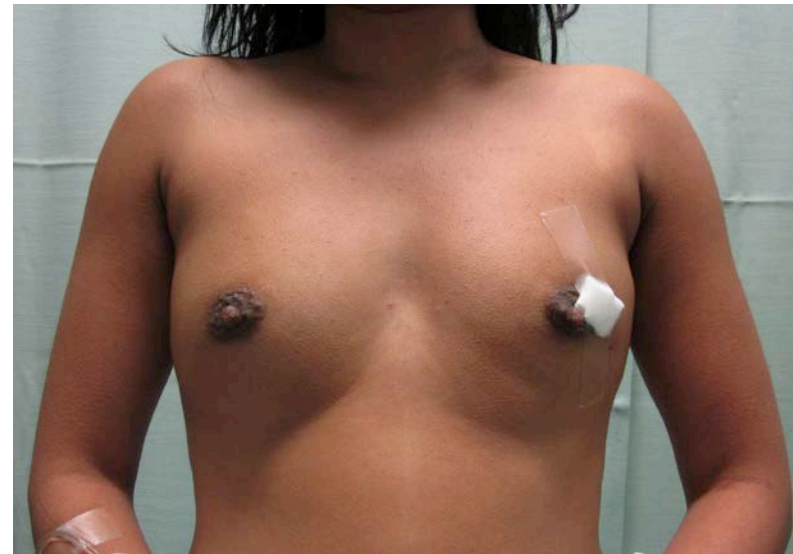
Future guidelines may recommend based on:

- HER2Neu status
- ER/PR status
- Tumour size
- Lymphovascular invasion
- Nottingham grade



Ideal Candidate

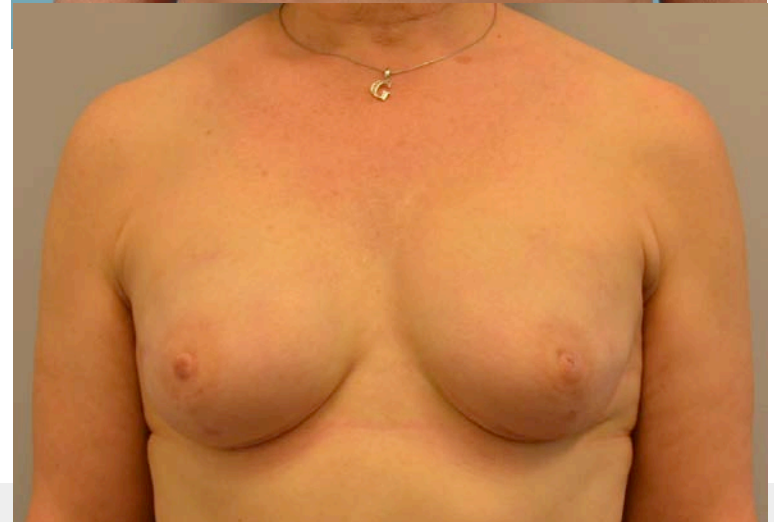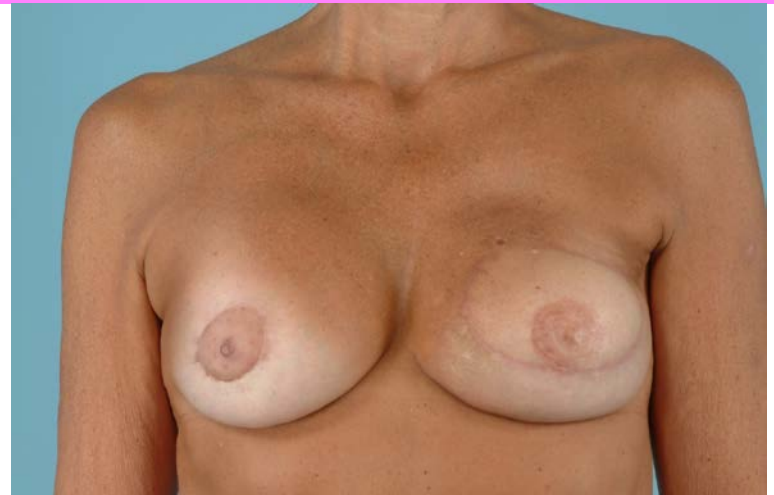- Small to moderate breast size
- Healthy nonsmoker
- Minimal ptosis
- Small, node negative tumor
- No evidence of nipple involvement





Advantages of NSM

- Single stage procedure
 - Requires fewer resources
 - Easier for patients
- Aesthetically improved over nipple reconstruction/tattoo
 - Natural colour
 - More natural projection
 - More natural shape



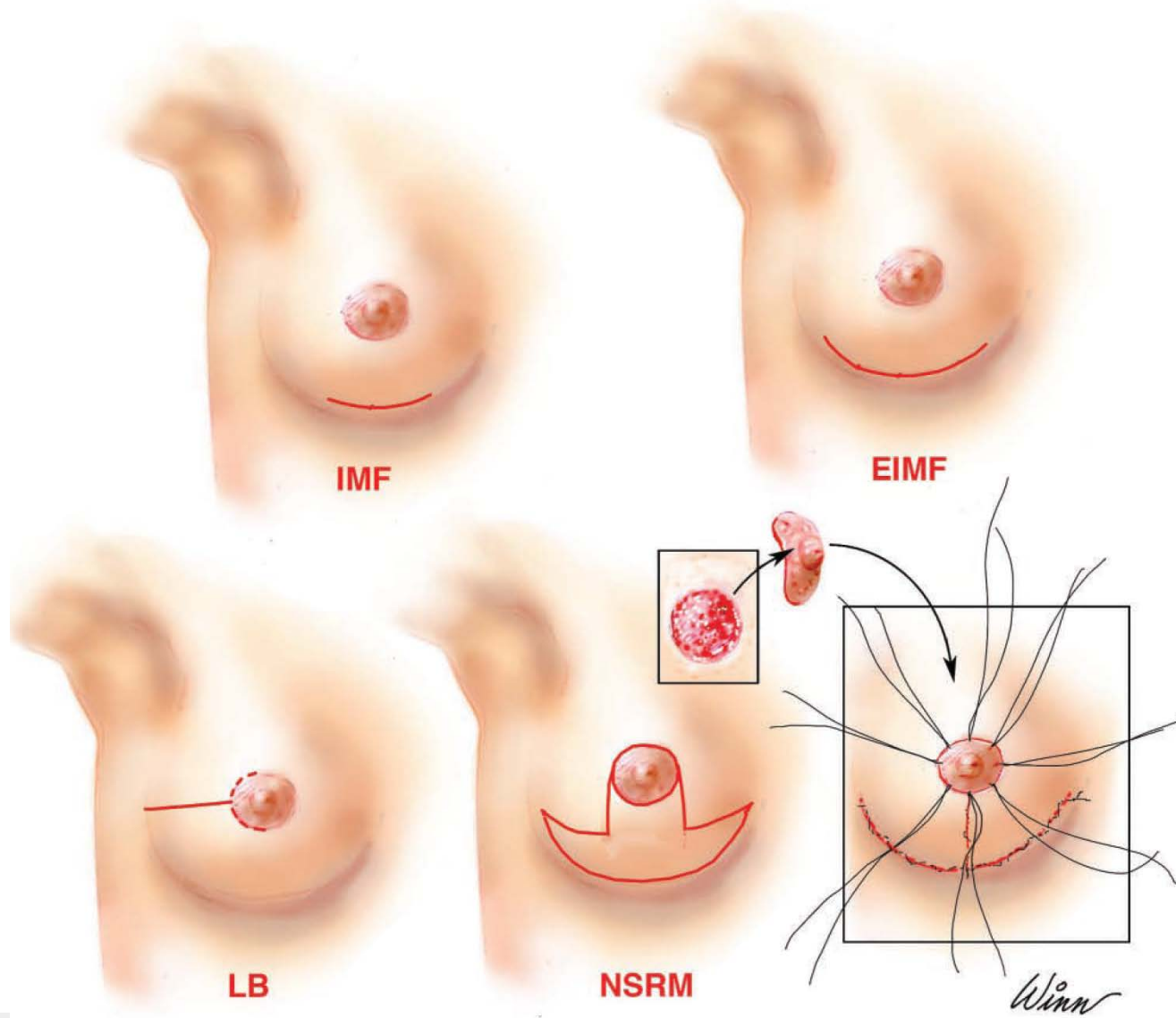


Disadvantages of NSM

- Some incisions (e.g. IMF) make it difficult to resect upper pole
- Nipple necrosis/delayed healing
 - Compromised aesthetic result
- Need for nipple resection/second procedure if subnipple tissue specimen positive
- Learning curve
 - ? Increased operative time vs. SSM

Incisions

Maxwell et al. Aesth Surg J 31;3:310-319.





Setup

- Pre & postop photos
- Preop markings agreed upon by both general and plastic surgery
- Headlamp or lighted retractor
- Clip applier, long instruments
- Local anesthetic/Tumescent technique
- Low temperature cautery
- Nitroglycerine paste
- Postop care taken to avoid undue tension on skin



Dr. Elaine McKevitt

Dr. Connie Chiu

Dr. Esta Bovil



How we do it.....

- Decision about NSM made at initial consultation or between first and second office visits
 - Tumour size and ability to obtain a clear margin
 - Definite NO: smokers, nipple involvement, nipple <2 cm from NAC, previous XRT
- Extended inframammary incision
- Local anesthetic with epinephrine
- Lighted retractor & multclip applier
- Sharp dissection under the nipple areolar complex; monopolar cautery for the remainder
 - Subareolar tissue sent as permanent section, not frozen
- Preserve ~1-2 cm of fat deep to the dermis



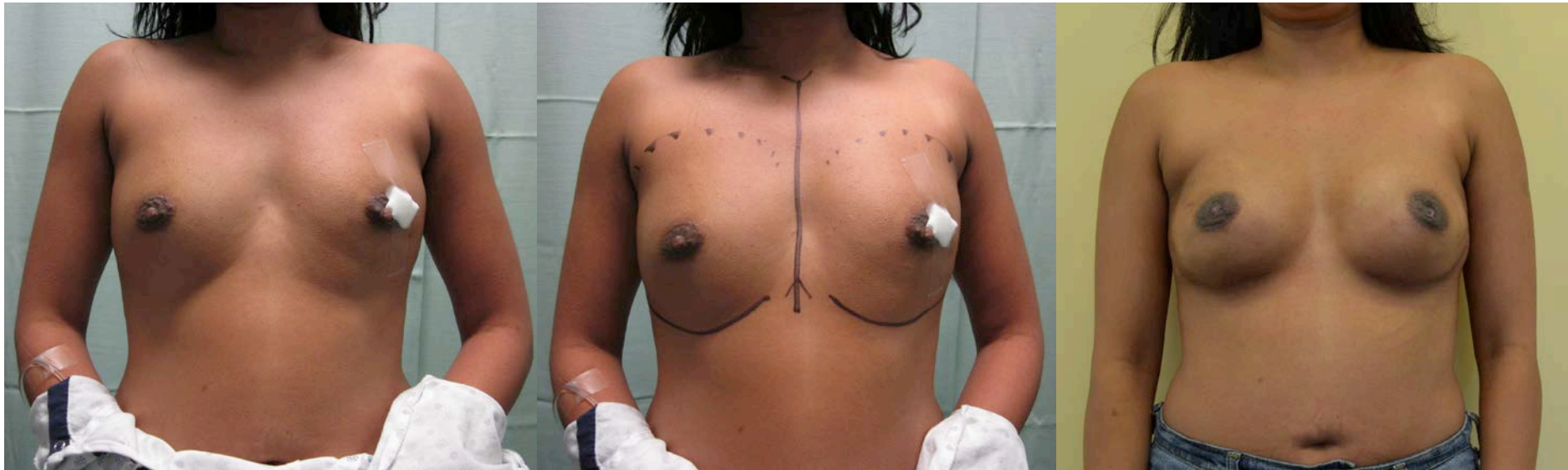How we do it.....

- In most cases, single stage immediate reconstruction with implant and Alloderm
 - I do not suture the NAC down to the deeper tissue, the way I used to for LB incisions
 - Avoid over-expanding/avoid creating ++ skin tension
- Nitropaste/opsite over the breast skin and NAC for 24h
- Breast binder



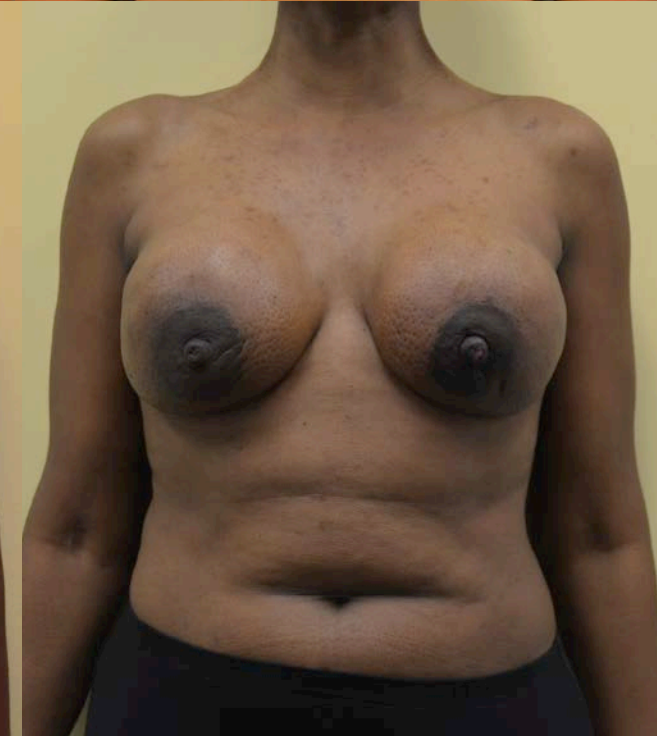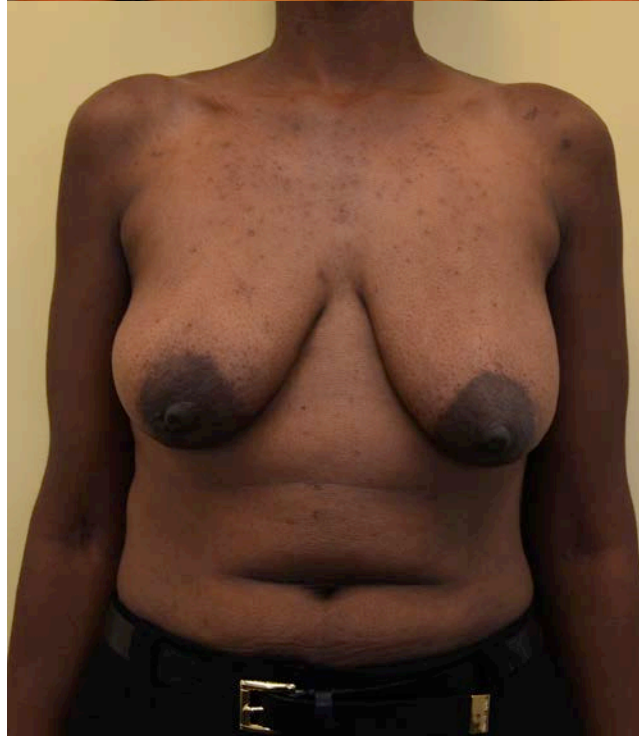
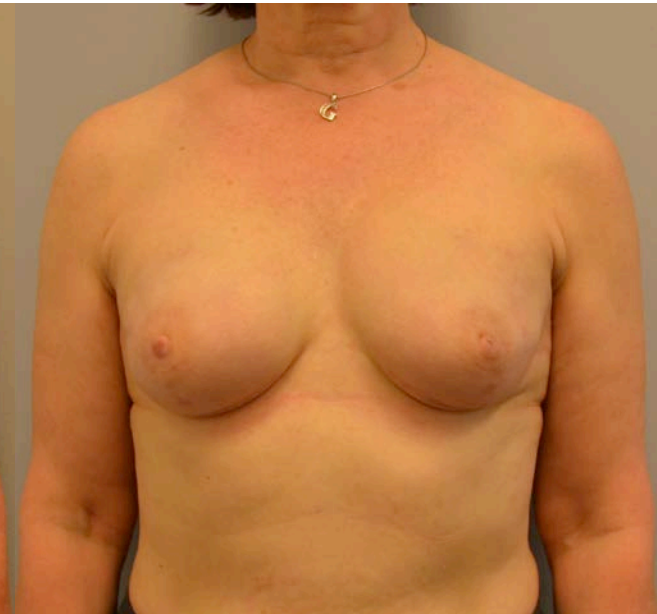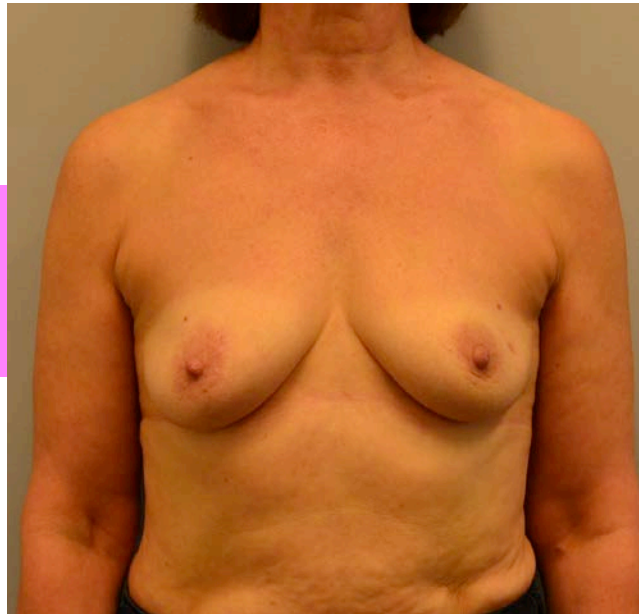
Results

- Single stage immediate implant reconstruction with Alloderm
- IMF incision



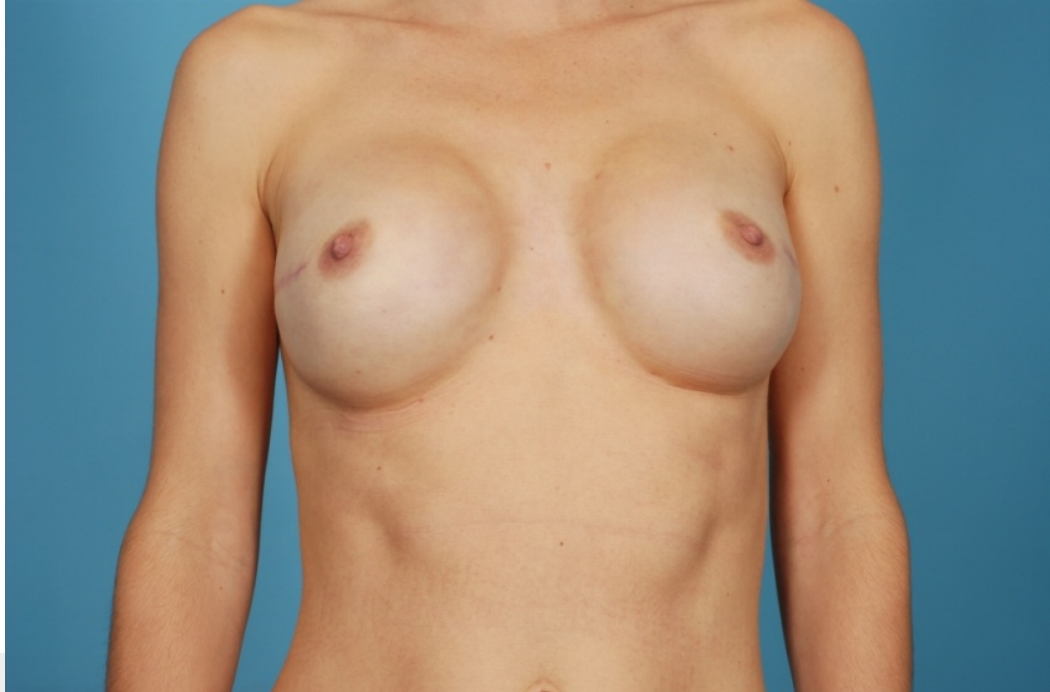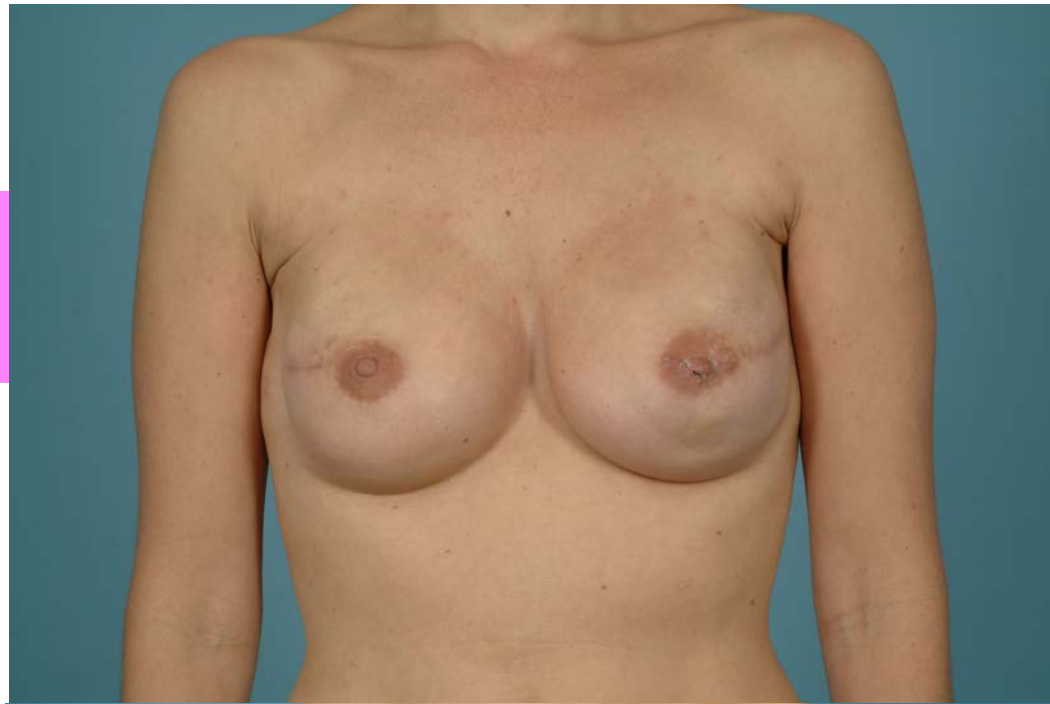
Results

- Immediate implant and Alloderm reconstruction
- IMF incision



Results

- Immediate implant with Alloderm
- Lateral and supraareolar incision (postop views only)





QUESTIONS?