# Intraductal Proliferative Lesions – DIN diagnosis and management

Dr. Kathy Ceballos

Surgical Oncology Network Breast Cancer Update

October 24, 2009

# Conflict of Interest -- None

# Asked to address....

- Classification/ new terminology (DIN) – Why?
- When is excisional biopsy recommended following a core?
- How likely is DIN1A on a core to have cancer on excision?
- What is the risk of future breast cancer with DIN1A?

# Intraductal proliferative breast lesions

- ‘Risk lesions’: neoplastic and non neoplastic
- Examples:
  - Usual ductal hyperplasia (UDH, epitheliosis)
  - Flat epithelial atypia (DIN1A)
  - Columnar cell change
  - Atypical ductal hyperplasia (ADH)
  - Low grade DCIS
  - Grade 2 and 3 DCIS

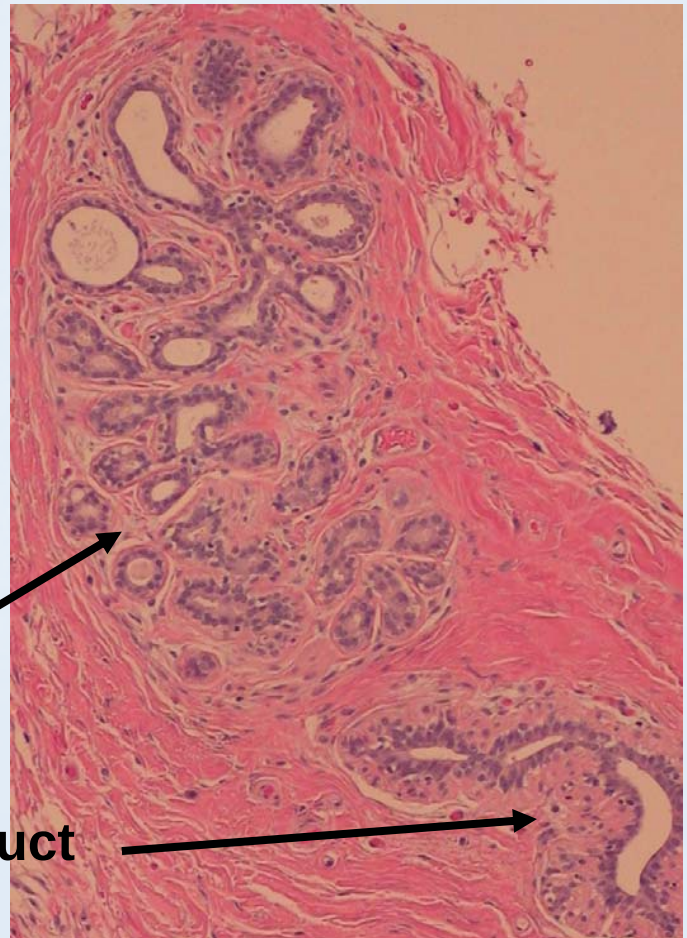

# Columnar cell lesions and Flat epithelial atypia (DIN1A)

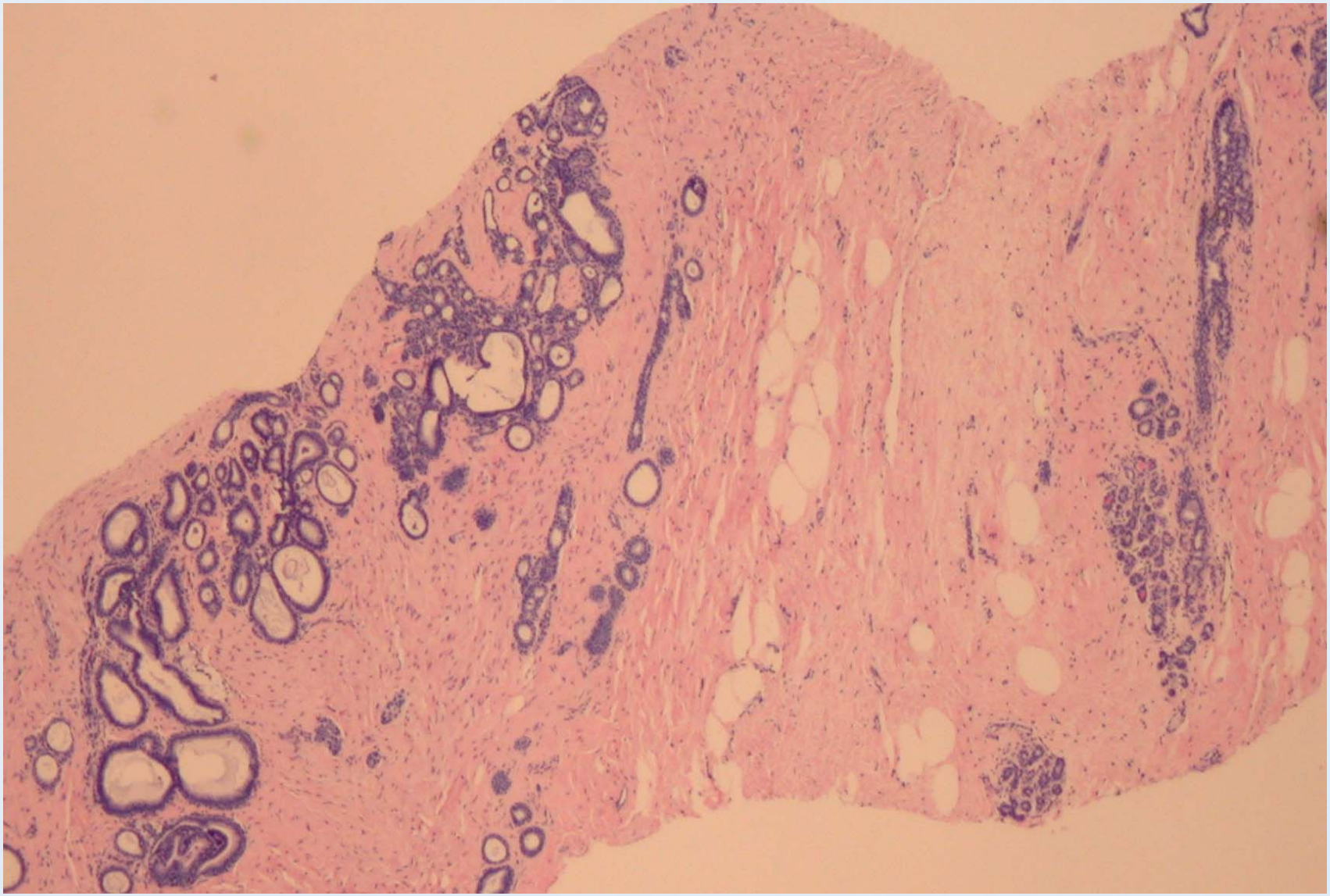

# Columnar cell lesions (CCL)

- Columnar cell change (CCC), columnar cell hyperplasia (CCH)
- +/- atypia

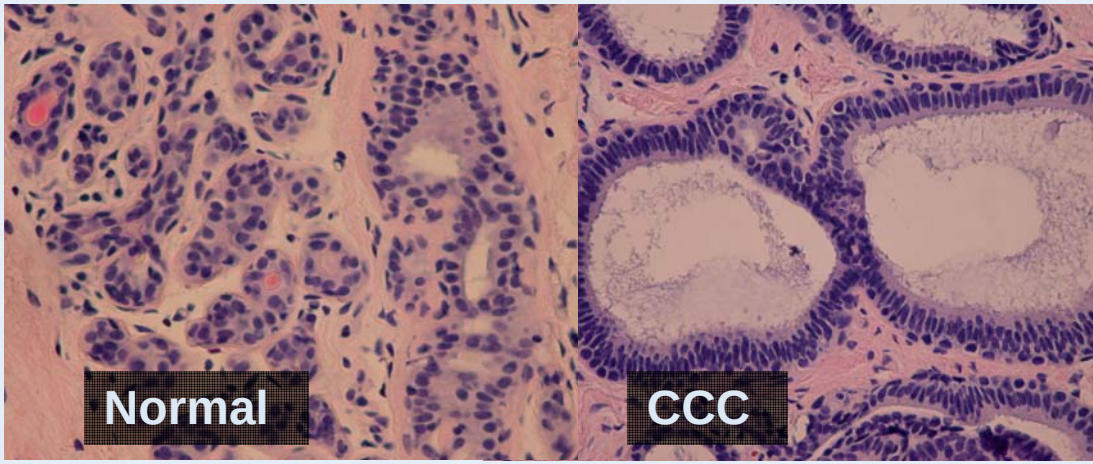


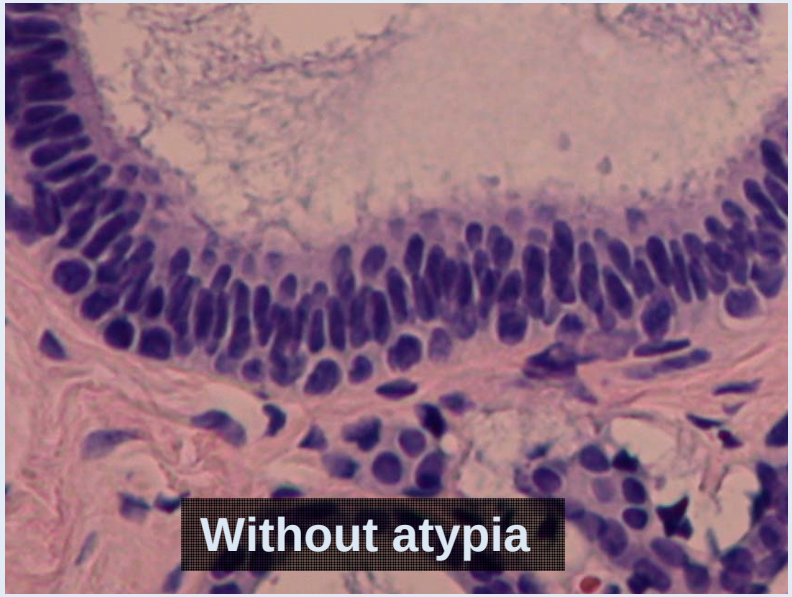


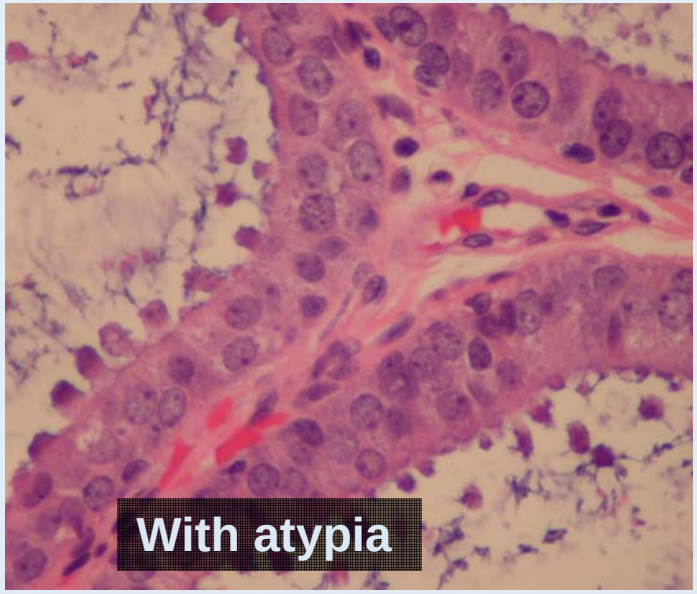

# Flat epithelial atypia (DIN1A)

- Neoplastic intraductal alteration 1 – 5 layers of mildly atypical cells resulting in a distension of TDLUs
  - Synonyms: clinging carcinoma, columnar cell change with atypia, columnar cell hyperplasia with atypia
- Associated with invasive tubular carcinoma and LCIS. May be the immediate precursor
- Frequently multicentric, multifocal and bilat

# Flat epithelial atypia (DIN1A)

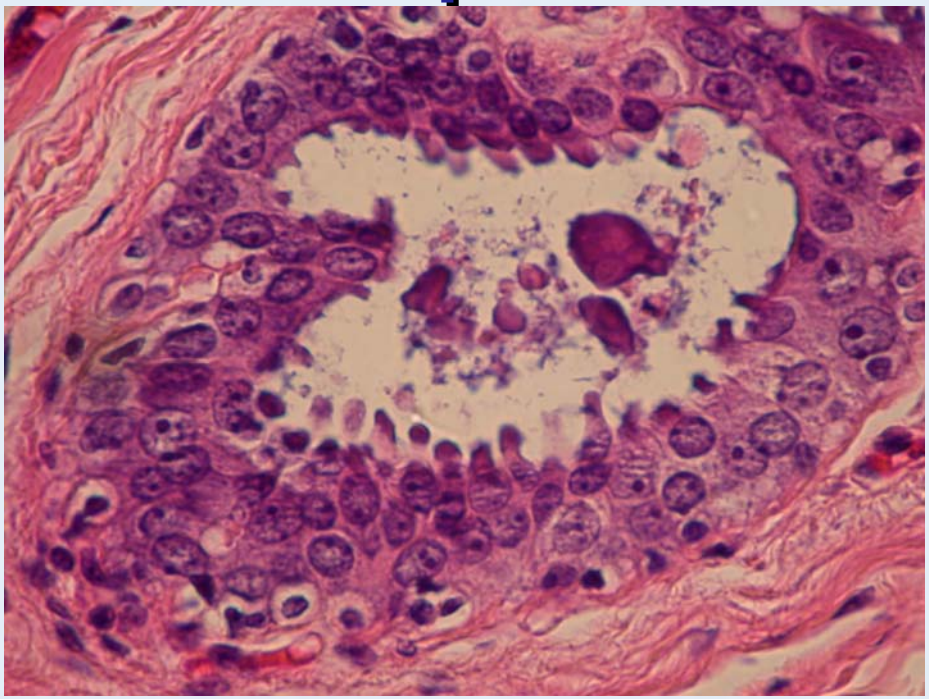

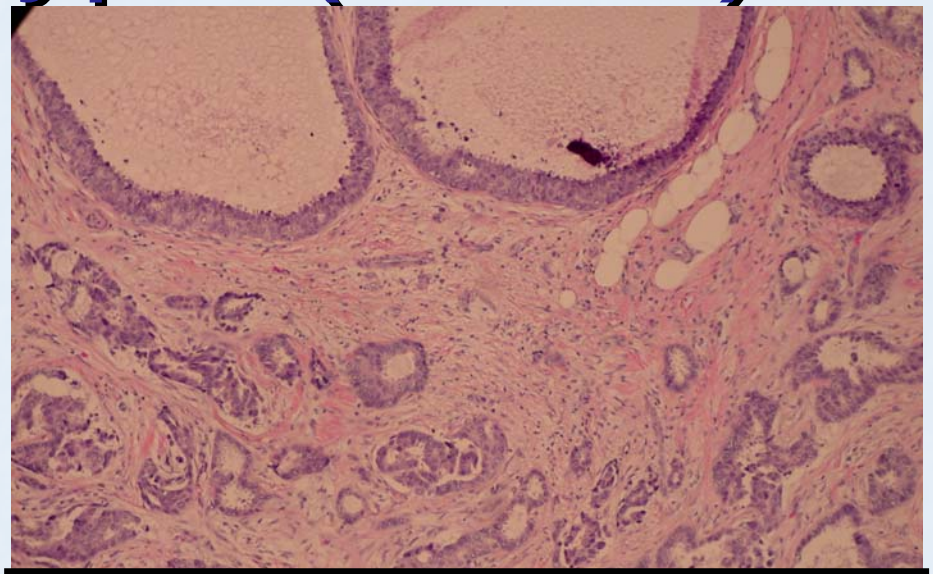

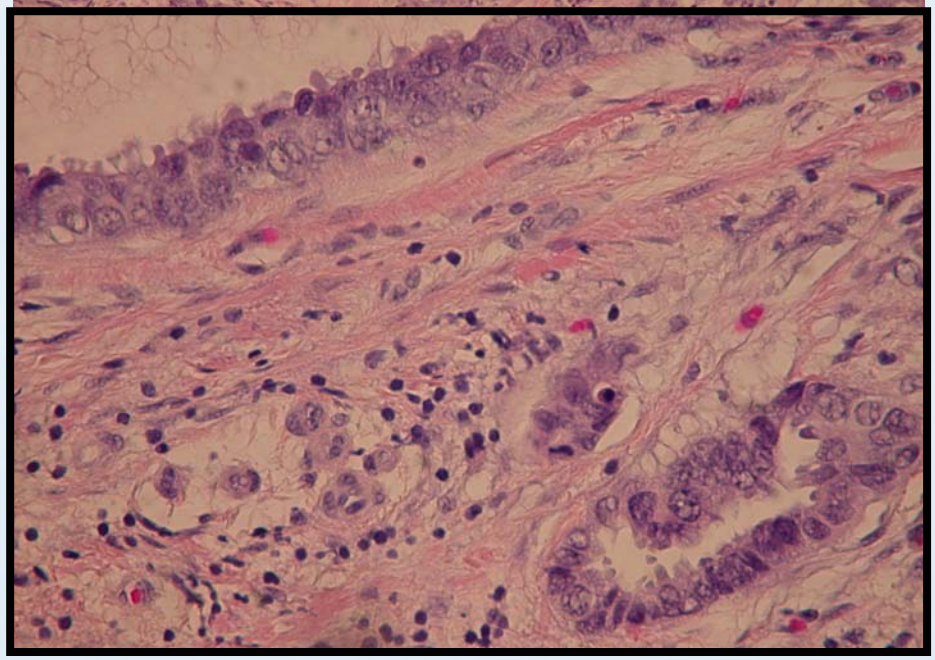

- Commonly associated with calcifications
- May be mammo target lesion

# DIN1A – issues of reproducibility

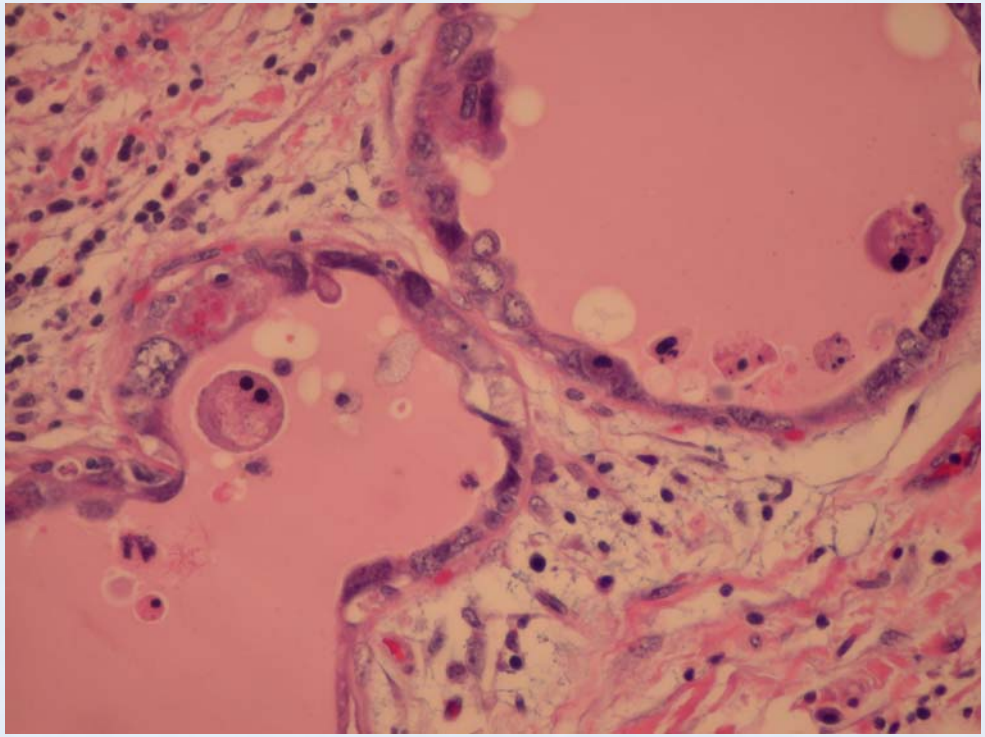

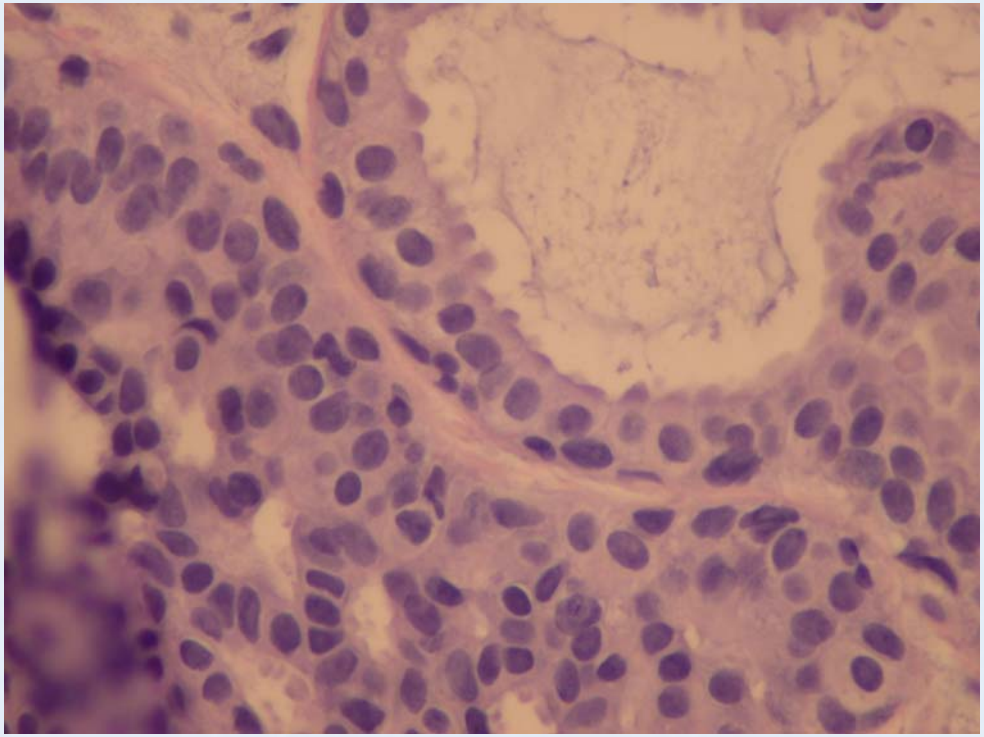

# Atypical ductal hyperplasia (DIN1B)

- Neoplastic intraductal lesion consisting of monomorphic cells forming arcades, bridges, papillae or solid masses.
- Morphologically IDENTICAL to low grade DCIS but insufficient in quantity (< 2 complete duct spaces or 2 mm)
- Concept invented to prevent over treatment of minimal disease

# Atypical ductal hyperplasia



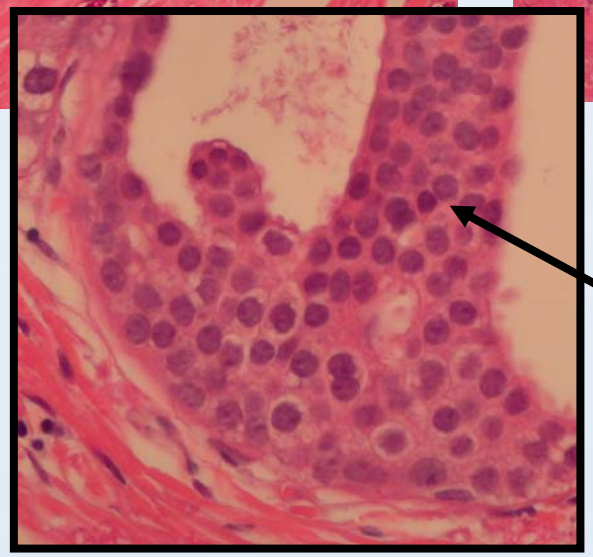

monomorphic cells

# Low grade DCIS

# Classification

- Traditional
  - Usual ductal hyperplasia
  - Flat epithelial atypia
  - Atypical Ductal Hyperplasia (ADH)
  - Grade 1 DCIS
  - Grade 2 DCIS
  - Grade 3 DCIS

# Ductal intraepithelial neoplasia (DIN) terminology

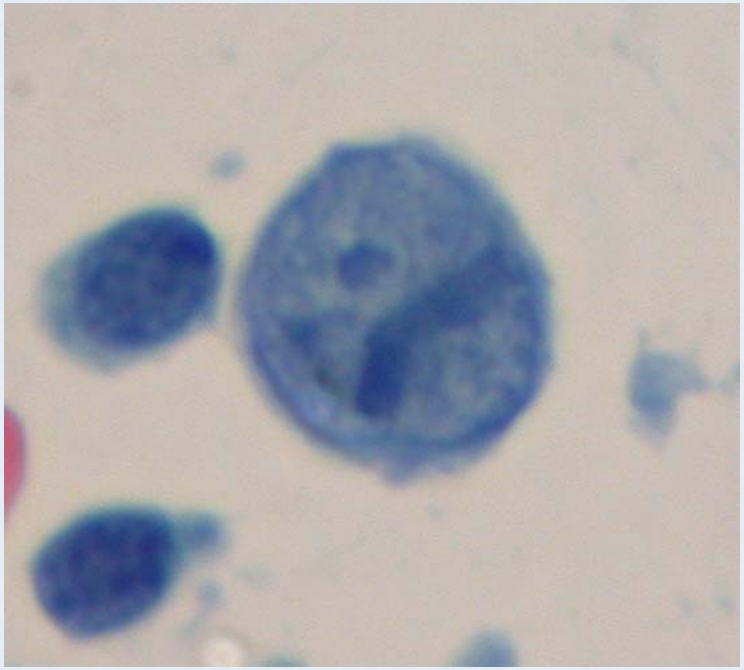

**WHY!?!!!!**

# Ductal intraepithelial neoplasia (DIN) terminology -- WHY?!

- Traditional terminology did not reflect the biology
  - Objections to the term ductal **carcinoma** in situ
    - Carcinoma usually assoc. metastatic potential
    - Non obligate precursor to invasive disease
  - Objections to term atypical ductal **hyperplasia**
    - Neoplastic lesions
    - ADH and low grade DCIS are morphologically identical yet one is carcinoma and one is hyperplasia
- Trend in other organ systems (CIN, PIN, etc)

# Ductal Intraepithelial neoplasia (DIN) terminology**

- Usual ductal hyperplasia = UDH
- DIN 1A = flat epithelial atypia
- DIN 1B = atypical ductal hyperplasia
- DIN 1C = low grade DCIS (grade 1)
- DIN 2 = grade 2 DCIS
- DIN 3 = grade 3 DCIS

**will likely evolve with molecular genetics

# DIN1A on core biopsy

Studies: Up to 1/3 of DIN1A on core bx upgraded on excision

- Limited by:
  - Numbers
  - Diagnostic criteria
  - Not all ‘pure’ DIN1A (coexisting ADH)
  - Mammographic findings unknown
  - Many include ADH/DIN1B as ‘upgrade’

# DIN1A on core biopsy

Senetta et al (2009): 392 cores for calcifications

- CCLs target calcs in 37% cases
- 41 pts flat epithelial atypia (DIN1A) only
  - 36 surgery – no DCIS, or invasive disease, 13% ADH, 23% ALH/LCIS, 34% DIN1A
- Recommendation: No need to excise

# DIN1A on core biopsy

Kunju (2007): 14 cases pure DIN1A from 2000-2005

- 1 had low grade DCIS, 2 Inv Ca on excision (21% upgraded)
- 5 ADH/DIN1B, 2 LCIS/ALH, 2 no resection
- Mammo Indication: 12 calcs, 2 densities
- Recommendation: Excision

**usually 14 gauge needle, avg of 5 passes

# DIN1A on core biopsy

Martel et al (2007): 1751 core bx reviewed retrospectively, 63 pure DIN1A

- 24 excisions up to 10 yrs later – 9 Inv Ca
- 5 of 24 excisions happened within 3 months, NO Inv Ca
- Recommendation: Risk factor – screening
  - Do not excise

# DIN1A on core biopsy

Piubello et al (2009): 875 core bx over 5 yr period reviewed, pure DIN1A in 33 cases

- 0 of 20 excisions had DCIS or inv. Ca
- Recommendation: Do not excise

# DIN1A on core biopsy – BCCA (unpublished)

145 core biopsies from BCWHHC and BCCA with pure DIN1A underwent excision

- 8 excisions (5.5%) showed upgrades of significance
  - 6 DCIS
  - 2 Invasive cancers
- ?Nature of mammographic abnormality
- Recommendation: Do not excise

# Excision

- ADH (DIN1B) – 10-39% upgraded on excision (usually DCIS)
- All papillary lesions (25% upgraded to ADH or DCIS)
- Radial scar -- ~20% ADH, ~20% DCIS, up to 12% IDC
- Mucocele like lesions -- ~30% DCIS or IDC

# No excision

- Lobular neoplasia (ALH/LN1, LCIS/LN2)
- Flat epithelial atypia (DIN1A)

- <u>This assumes rigorous radiological pathological correlation</u>

# DIN1A – Risk of subsequent Cancer



# DIN1A Risk

Bijker et al (2001): EORTC trial 10853
(recurrences or mets post breast conserving sx for DCIS)

- 0/59 cases DIN1A (called low gr clinging DCIS) recurred, follow-up 5.4 yrs

- Eusebi et al (1989):
  - 2/32 (6%) cases recurred as grade 1 DCIS, follow-up 17.4 yrs
- Conclusion: ?risk is low

# DIN1A Risk – BCCA (unpublished)

All benign breast bxs 1989-1996 reviewed

- 133 cases DIN1A (109 excisions, 24 cores)
- 34 coexisting ADH (DIN1B), 24 ALH/LCIS, 1 invasive tubular Ca
- All untreated after initial biopsy
- BCCA records searched for follow up to 2007

# DIN1A Risk – BCCA Outcomes

- **Worse lesion developed in 28/133 women (21%)**
  - 13 cases DCIS
  - 15 cases invasive carcinoma (2 lobular)

- 18 lesions were in the ipsilateral breast, 10 in the contralateral breast

# In summary...

- New WHO classification (DIN)
- Excision:
  - ADH/DIN1B, radial scars, mucocele like lesions, papillary lesions, DCIS, invasive Ca
- No excision:
  - FEA/DIN1A, ALH, LCIS
- Likelihood DIN1A on a core to have cancer on excision:
  - very low in our lab (5%)
- Future risk of breast cancer with DIN1A
  - ?similar to ADH/DIN1B (10%)

# ADH/DIN1B on core biopsy

Eby et al (2009): 991 consecutive core bx 2001-2006, 141 cases ADH/DIN1B (14.2%)

- 26/123 upgraded to DCIS or inv Ca on excision (21.1%)
- Recommendation: Excise