

CHALLENGING CASES

BCCA SON Fall Update 2012

Moderator: Dr. Rona Cheifetz



THE UNIVERSITY OF BRITISH COLUMBIA

surgery



Disclosures



- None



1. OBSTRUCTING RECTAL CANCER

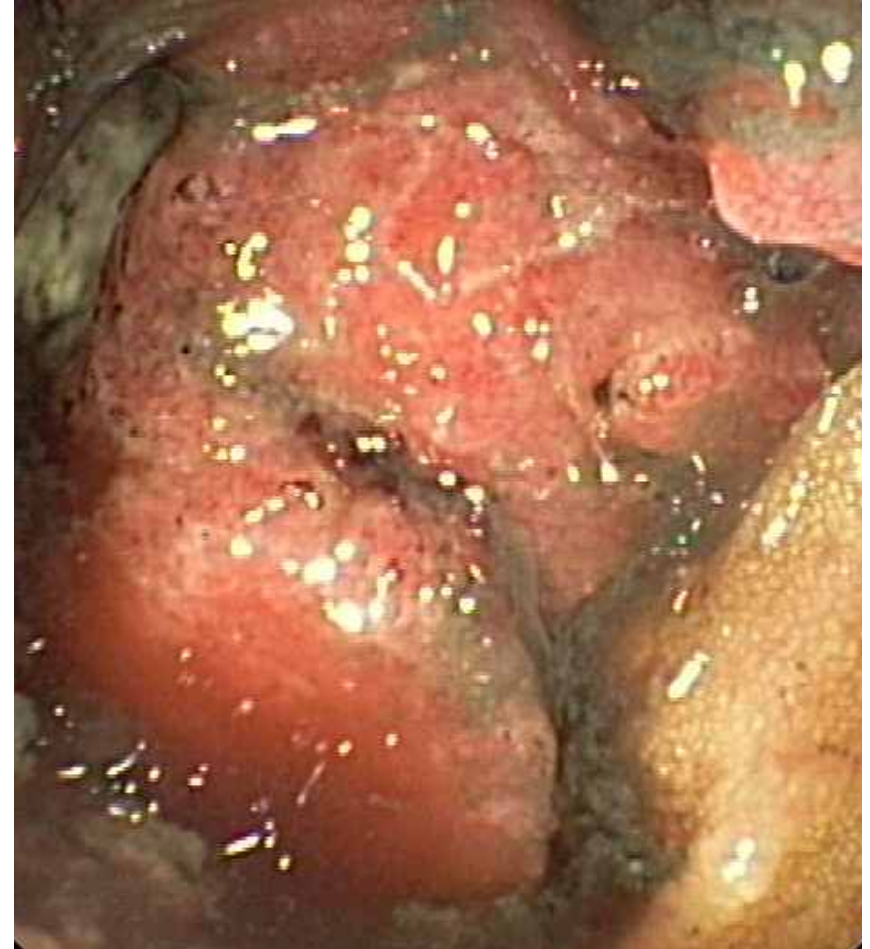Presentation



- 43 year old male
- 3-6 month change in bowel habits
 - Narrowed caliber stools
 - Occ BRBPR
- 10 lbs weight loss
- Urgent referral to GI

Colonoscopy

- Circumferential tumour starting at 6cm from anal verge
- Extends to at least 15cm
- Unable to pass further due to obstruction and angulation
- Bx: moderately diff adenoca
- Referred to Surgery



At Surgical Consult

- Hx
 - Tolerating liquids only
 - Crampy abdo pain
 - Fecal frequency, urgency, tenesmus
 - Intermittent nausea, no vomiting
- PE
 - Moderately distended, mildly tender abdomen
 - DRE – circumferential tumour starting at 6-7cm, tethered, blood on examining finger

At Surgical Consult

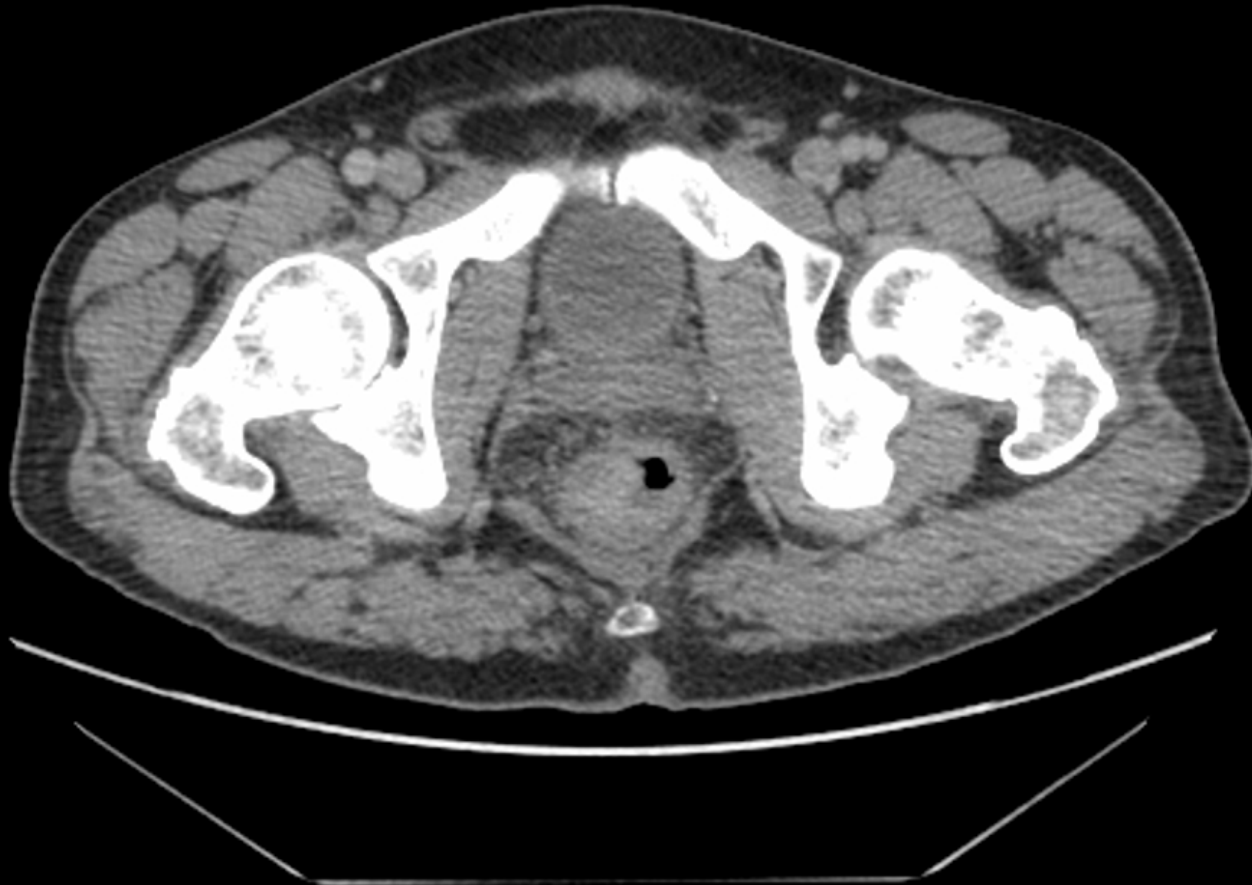- PMHx
 - Schizophrenia, well-controlled
 - DM II
 - Hypercholesterolemia
 - Hypertension
 - 20 pack year smoker
- Meds
 - Clozapine
 - Divalproex
 - Metformin
 - Ramipril
 - HCTZ
 - Statin
- Fam Hx
 - Estranged sister thought to have “stomach cancer” in mid 30s

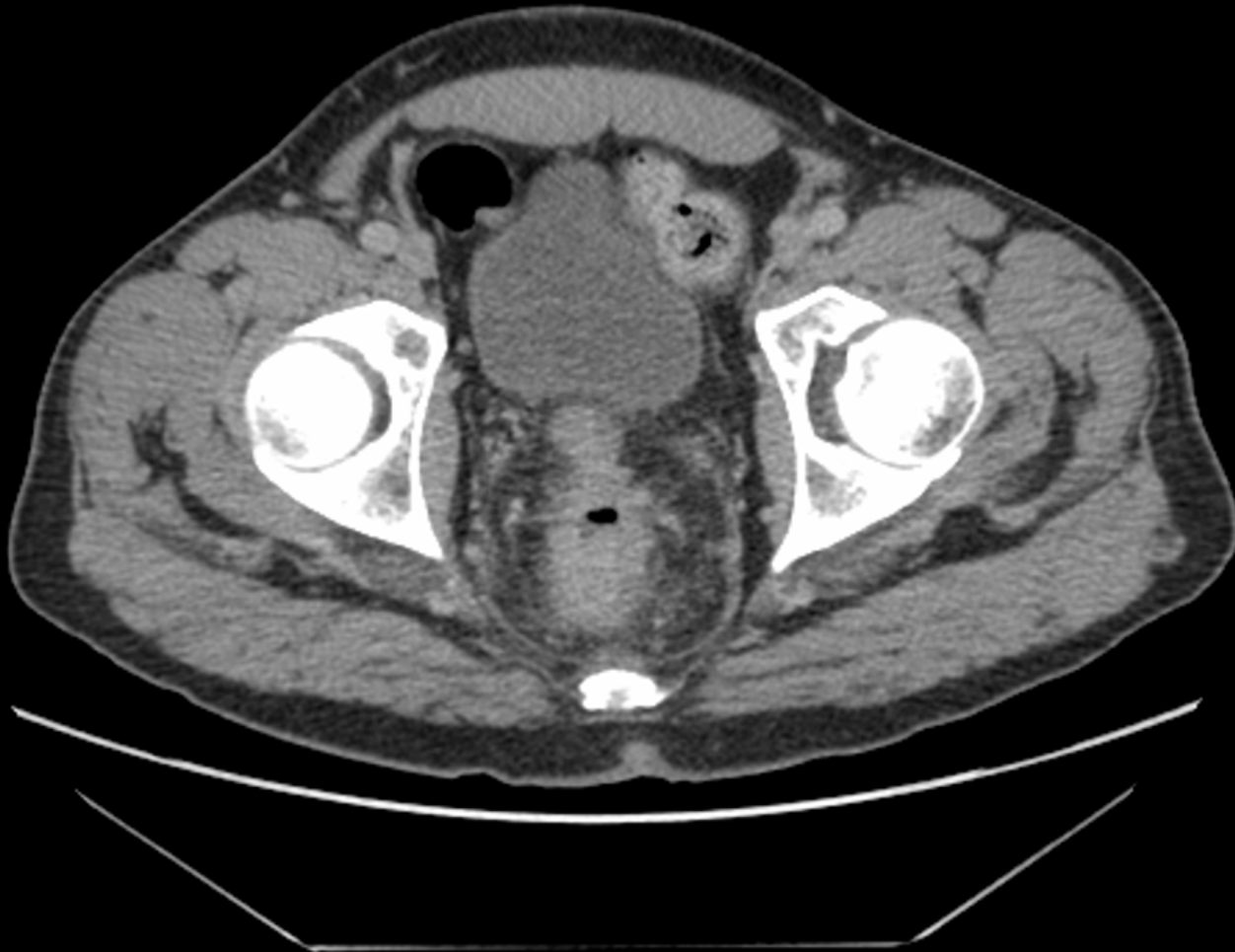At Surgical Consult

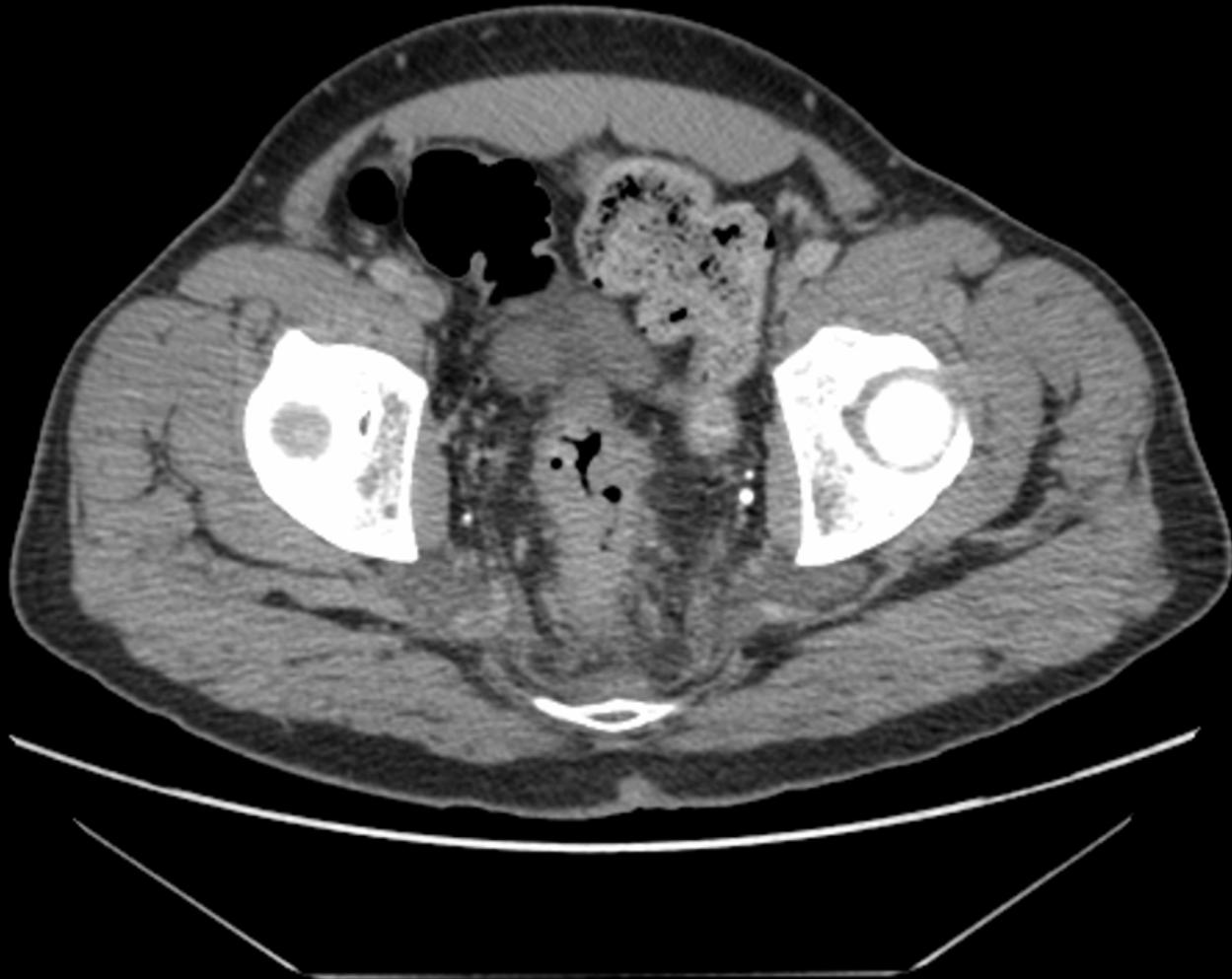

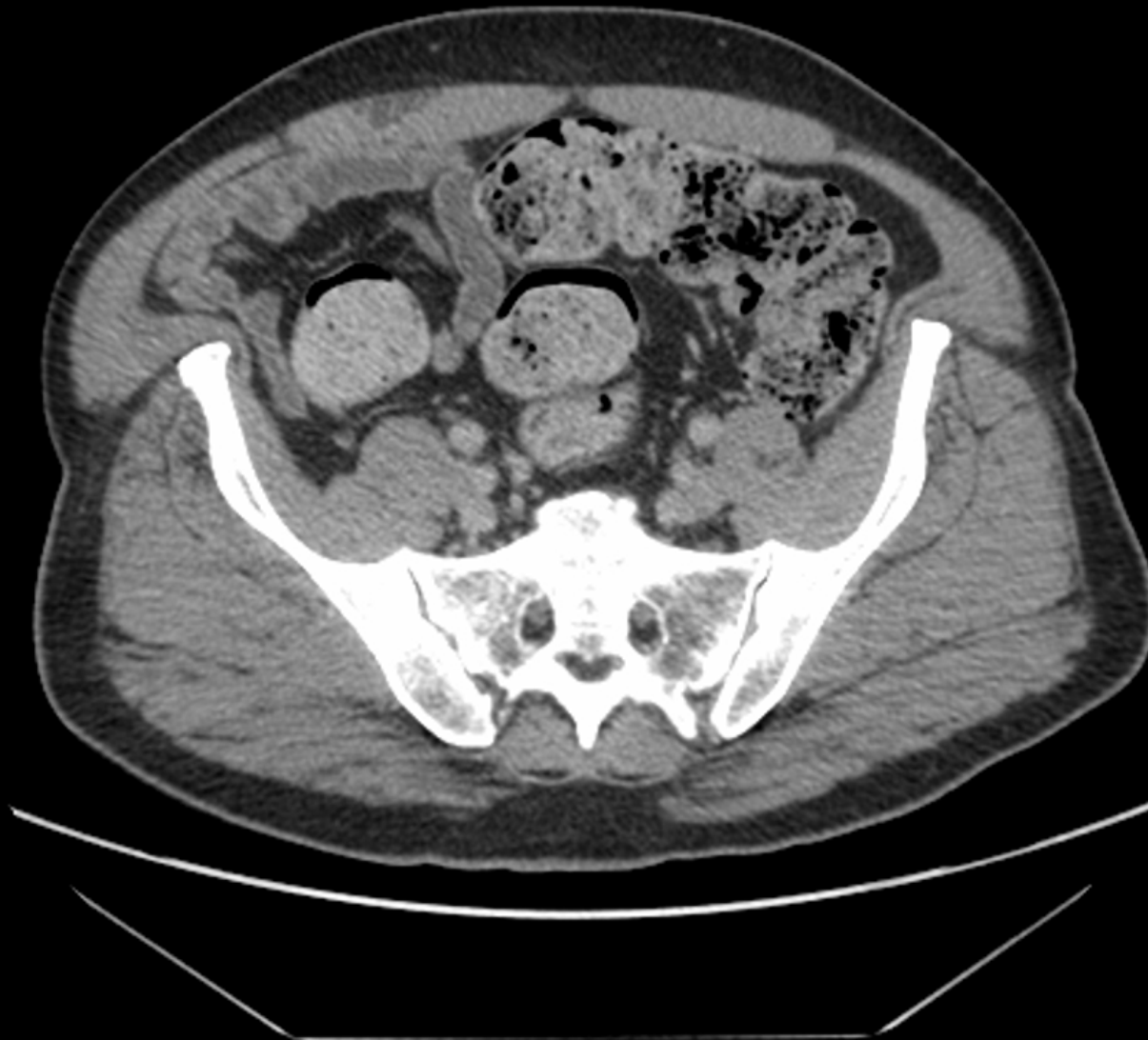- Patient advised to be admitted to hospital due to advanced obstructive symptoms
- Declined admission and reluctant to proceed with surgery
- Agreed to staging investigations and BCCA referral
 - CT CAP
 - ERUS
- CEA = 16

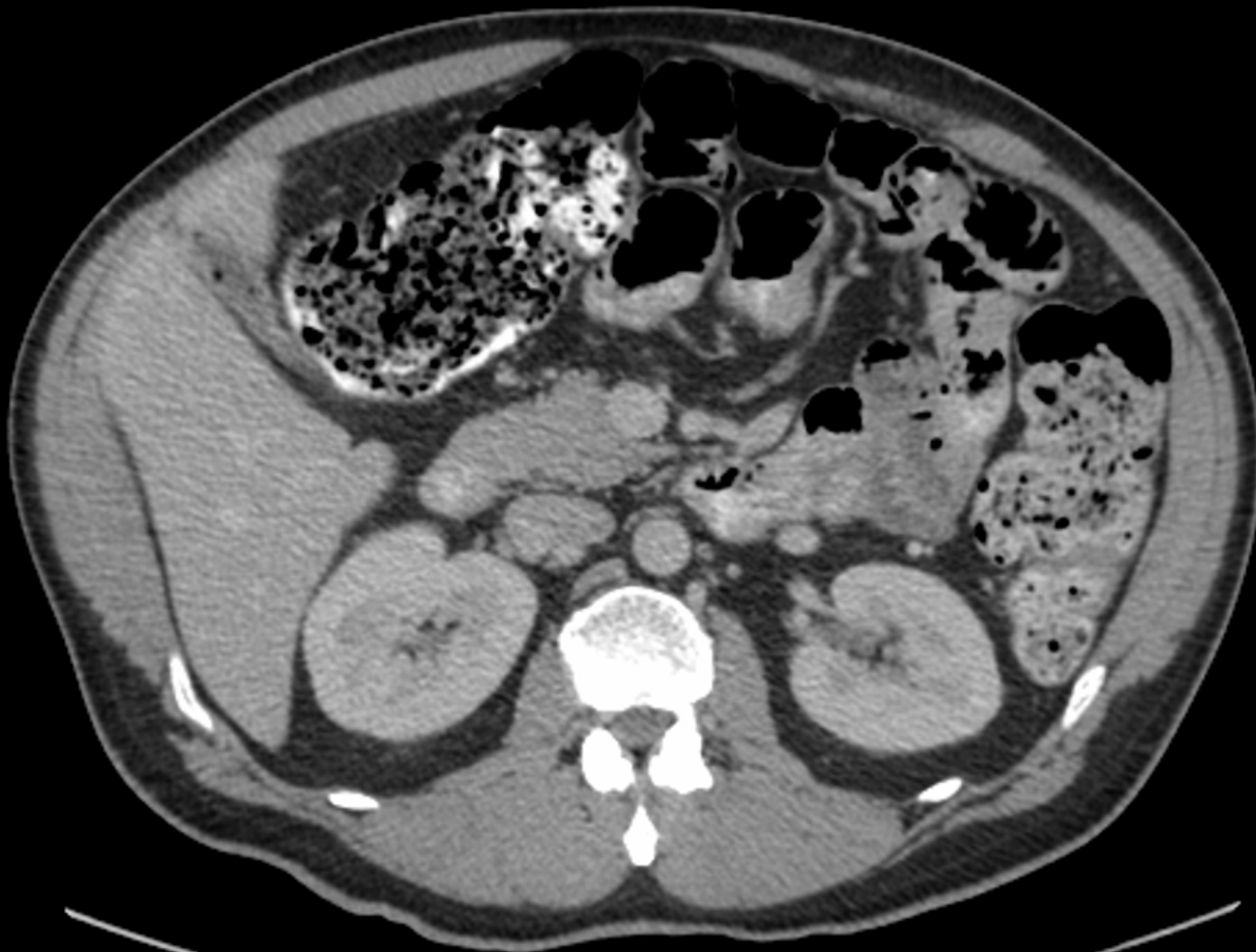











- CT CAP
 - Large obstructing tumour
 - Multiple mesorectal nodes up to 1 cm
 - Dilated proximal colon with fecal loading
 - No obvious proximal colon lesions
 - No distant mets
- ERUS
 - T3N0 but unable to pass probe beyond lower aspect
 - Incompletely visualized tumour and mesorectum
 - Anterior fat plane intact

Clinical Course

- Patient presents to ER 1 week later
 - Increasing obstructive symptoms
 - Still passing flatus
 - Stable, diffusely tender but no peritonitis
 - AVSS
 - WBC 12
 - Plain XR – distended colon, no free air
- **Management Options for Discussion**
 - Stent vs. proximal diversion vs. resection ?

Clinical Course



- Stent not available
- Urgent OR
 - Diversion with proximal transverse loop colostomy
- Decompressed, tolerating solids
- Discharged day 5

Neoadjuvant Therapy



- Started long course chemorads 4 weeks later
 - 5040 cGy
 - Oral capecitabine
- Tolerated well
- No complications or serious AE's

Surgery

- Consented for LAR, poss APR
- OR at week 10 after chemorads (delayed due to social reasons)
 - Difficult resection due to body habitus + tumour bulk
 - Open LAR (TME)
 - Colostomy left untouched
 - 1.5 cm gross distal margin
- Discharged POD 9 (ileus)

Pathology

- Moderately differentiated
- Through muscularis propria into perirectal fat (T3)
- 2/14 nodes positive (N1)
- Perineural and Lymphovascular invasion
- Extranodal tumour deposits in mesorectum
- 1.5 cm distal margin
- Radial margin clear

Postop



- Currently on adjuvant chemo
- Plan for future colostomy closure



Literature Review:

Obstructing Colorectal Cancer

- Majority of literature review pertains to the management of obstructing colon cancer as there are fewer management options in rectal cancer (as in the case presented)

Surgical Options: Obstructing Left Colon Cancer



- Diverting stoma
- Resection and stoma
- Segmental Resection and primary anastomosis with or without proximal diversion and with or without on-table prep
- Subtotal or total colectomy



- Consensus Conference on the Management of Obstructing Cancer of the Left Colon
- Literature review and assessment using standard grading for quality of data

» <http://www.wjes.org/content/5/1/29>

» Ansaloni L, et al. WJ Emerg Surg 2010; 5:29

Loop Colostomy vs Hartmann's



- No short or long term benefit to colostomy
- Longer hospital stay
- Increased potential morbidity due to multiple operations
- **Hartmann's preferred to diverting colostomy(2B- based on RCTs with important limitations) provided it can be safely performed (diversion is faster)**



Hartmann's vs Primary Resection and Anastomosis



- No RCTS
- Note: Stoma reversal rate only 20% in patients with cancer
- Still risk of anastomotic leak with subsequent reversal
- No survival benefit to Hartmanns (2C+)
- **Hartmann's preferred in high risk patients only (2C- observational studies) otherwise resect**

Total vs segmental resection



- One RCT comparing TC vs segmental with on table prep- no diff in mort, morb, leak rate, wound infection but increased bms post op with TC
- **Segmental resection preferred** unless cecal ischemia/perforation or synchronous cancers (1A)



Segmental colectomy with colonic irrigation vs manual decompression



- One RCT
- No difference in morb, mort or leak rates (but underpowered)
- CI takes longer
- **OK to use either (1A) if needed but not necessary** (based on literature for mechanical bowel prep in general)



Recommendations



- So, surgically for obstructing left colon ca:
- First choice is segmental resection and anastomosis (if it can be safely done)
- 2nd choice is resection and stoma
- 3rd choice is proximal diversion only
- Order is reversed for the sickest patients
- **But what about non-surgical options???**



Stenting for Malignant Bowel Obstruction

- Systematic review 88 studies (including palliative and bridging stents) :
- Median technical success : 96 % (66- 100)
- Median clinical success: 92 % (46 - 100)
- Median stent migration rate : 11 % (0- 50)
- Median perforation rate : 4.5 % (0 - 83)
- Median reobstruction rate: 12 % (1 - 92)

- Median patency duration: 106 days (68 - 288), reported in 14 studies
- Median reintervention rate (unplanned surgery, placement of another stent, or other interventions to maintain stent patency): 20 % (0 - 10)
- Other complications (rectal bleeding, anal/abdominal pain, and tenesmus) were rare and generally mild

» Watt AM et al. Ann Surg 2007;246:24

More recent data

- Meta-analysis 5 randomized trials with 207 patients stent vs surgery.
 - Technical success 86%
 - Perforation rate 6%
 - Migration rate 2%
 - Obstruction rate 2%.
- Average time to clinical relief of obstruction was significantly lower with stent (0.7 days vs 3.6 days)
- No sig diff 30-day mortality or morbidity rates.
 - » Sagar J. Cochrane Database Syst Rev 2011:

And More

- Meta-analysis eight studies and 601 patients stent vs surgery
 - Stented pts less likely require care in an intensive care unit (risk ratio [RR] 0.42)
 - Less likely undergo stoma formation (RR 0.70)
 - More likely to have a primary anastomosis (RR 1.6)
 - Lower complication rates (RR 0.42).
 - No difference between the groups in mortality or long-term survival.
 - » Zhang Y et al Surg Endosc 2012 26:110.

- RCT: Stenting higher success one stage surgery, less blood loss, less wound infection, less anastomotic leak and greater lymph node harvest
 - » Cheung HYS et al, Arch Surg 2009 144(12) 1127-1132
- Cost benefit (YES)-Stents are expensive, but shorter hospital stay and avoidance of stoma
- **Recommend use (1B) in expert hands**
 - » Ansaloni et al, World J Emerg Surg 2010;5:29
- Not recommended with obstruction with evidence of systemic toxicity due to risk of ischemia and/or a perforation
 - » Cheung HYS et al, Arch Surg 2009 144(12) 1127-1132

HOT OFF THE PRESS



- Prospective randomized trial 22 patients with Stage IV (unresectable) rectosigmoid cancer and subacute obstruction
- Stent vs stoma
- Stent shorter hospital stay, higher satisfaction, no survival difference
- But, they note other recent studies reporting higher mortality for stents in emergency setting
 - » Fiore e et al. AM J Surg Sept 2012 204:321-326

SO we are still conservative...



- Final recommendation in “Up to Date”
- Given the high perforation rate related to stent placement (around 5%),
- **Stents should be reserved for patients at increased risk of emergency surgery (multiple significant comorbidities) or who need to be medically optimized.**
- Stenting should be performed by endoscopists with **significant** experience with stent placement.



- So, going back to this case, of an obstructing, advanced rectal cancer;
- Stenting is an option if expertise is available, otherwise diversion to relieve obstruction and proceeding with usually treatment thereafter is appropriate.

2. Asymptomatic stage IV cancer

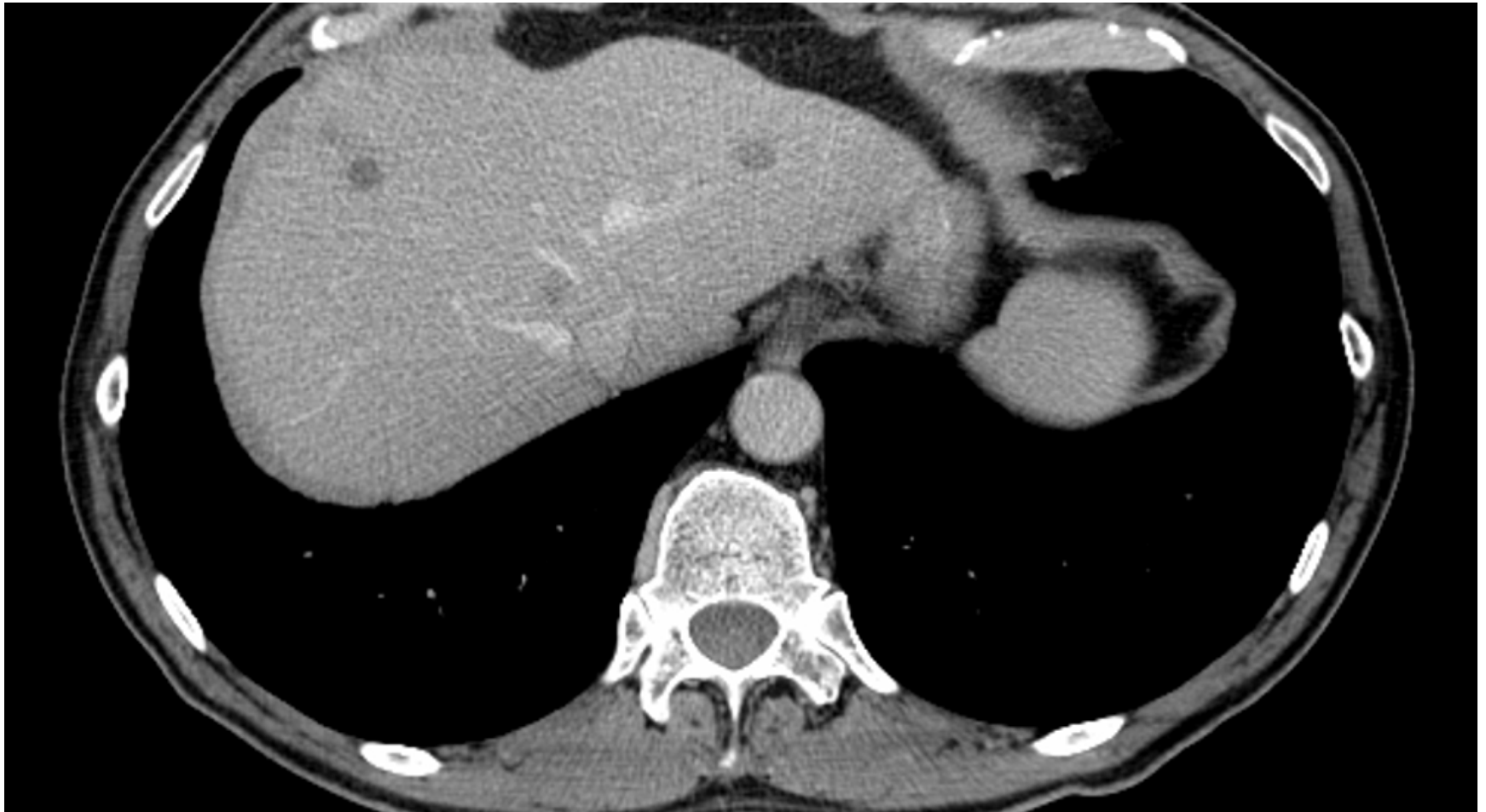Presentation

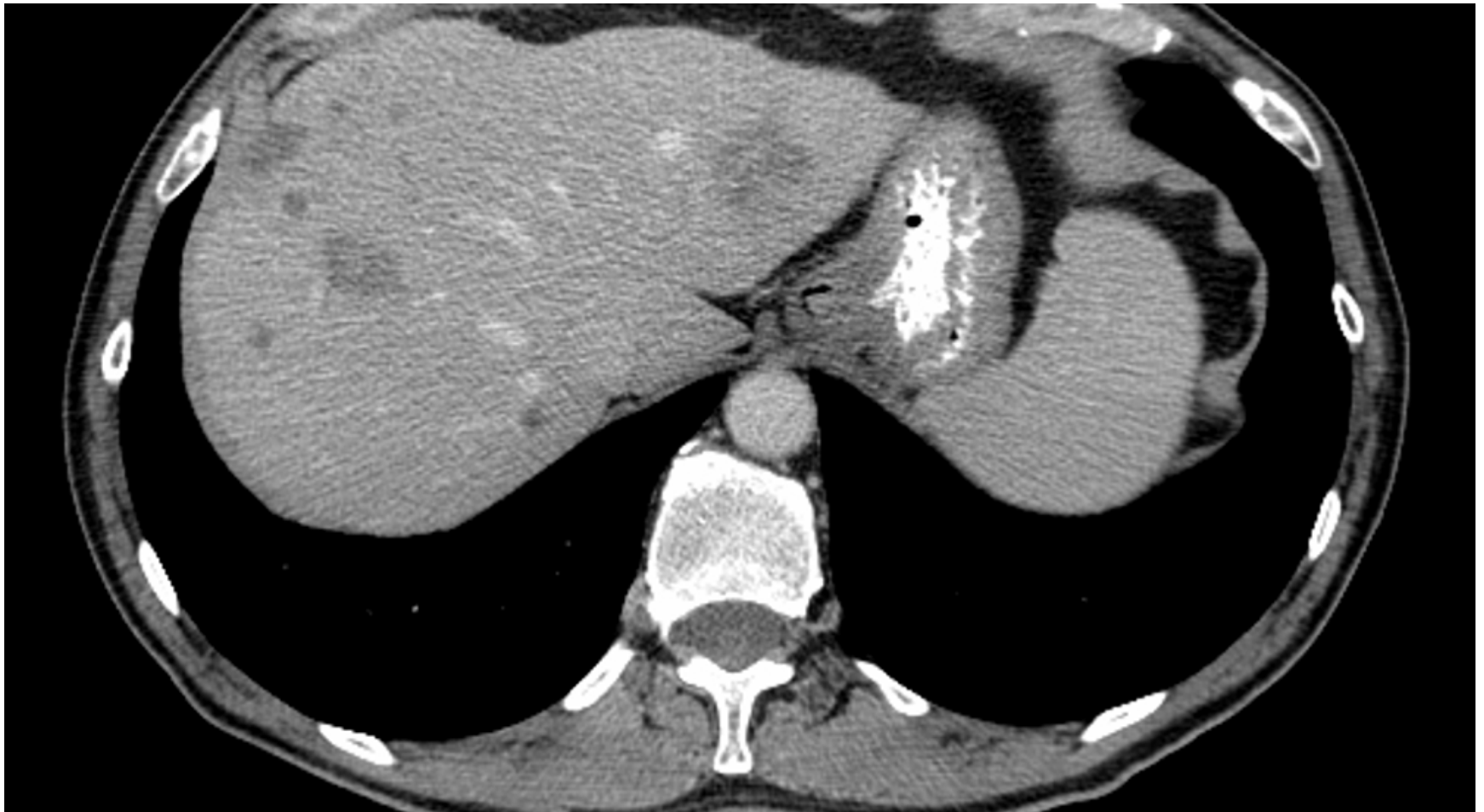

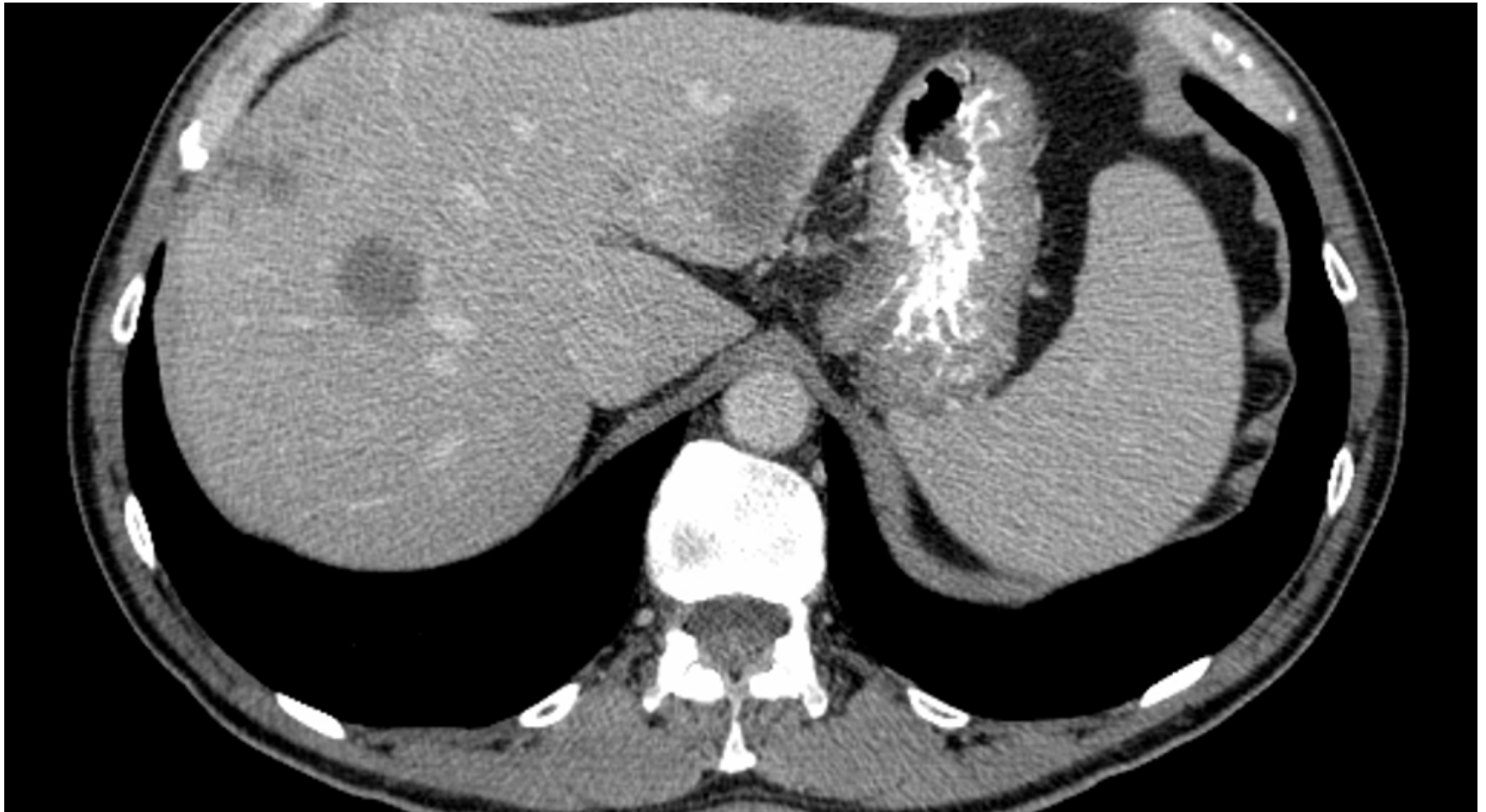- 64 year old male
- Incidental anemia found on routine blood work following complete Hx and PE by new GP
- Patient asymptomatic (normal bowel function)
- PMHx and FamHx negative, on no meds
- FOBT positive 2/3
- Referred for upper and lower endoscopy
 - EGD normal

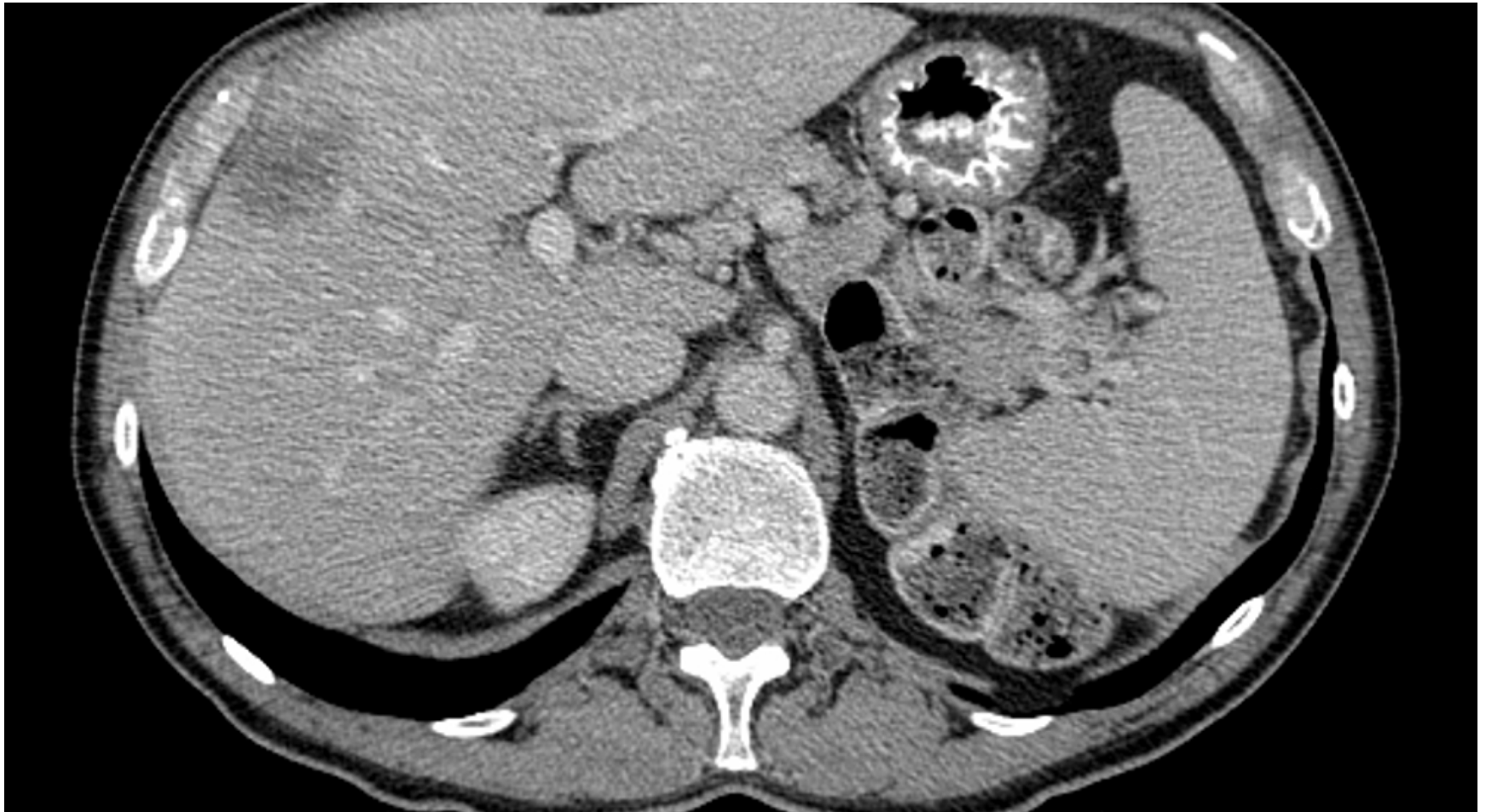Colonoscopy

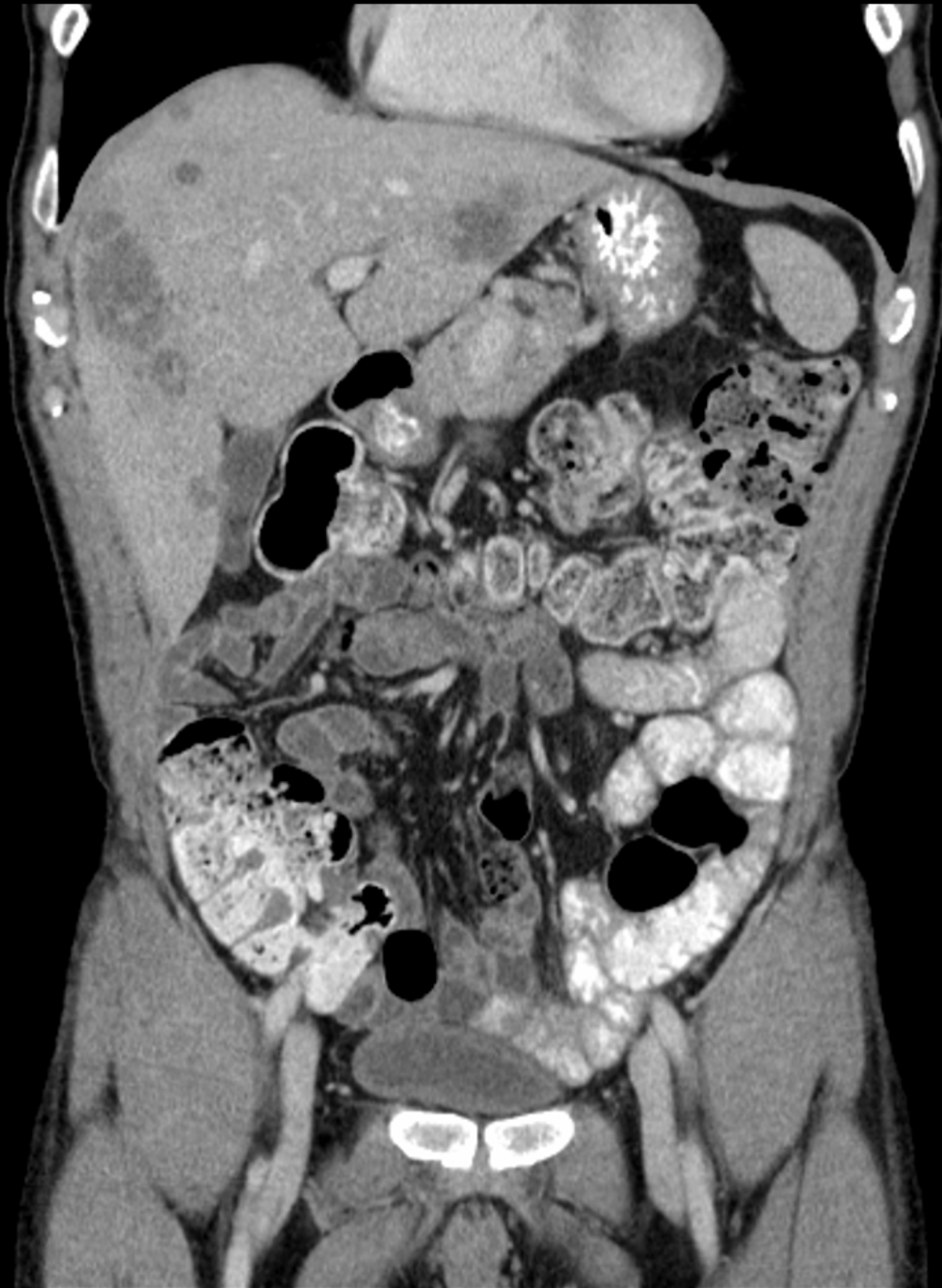- Performed 6 months after referral
- 3cm firm, umbilicated, non obstructing lesion at 18cm
 - Bx = poorly differentiated adenoca
 - Tattooed distally x3
- Mild sigmoid diverticula
- Otherwise normal to cecum
- Staging CT CAP ordered

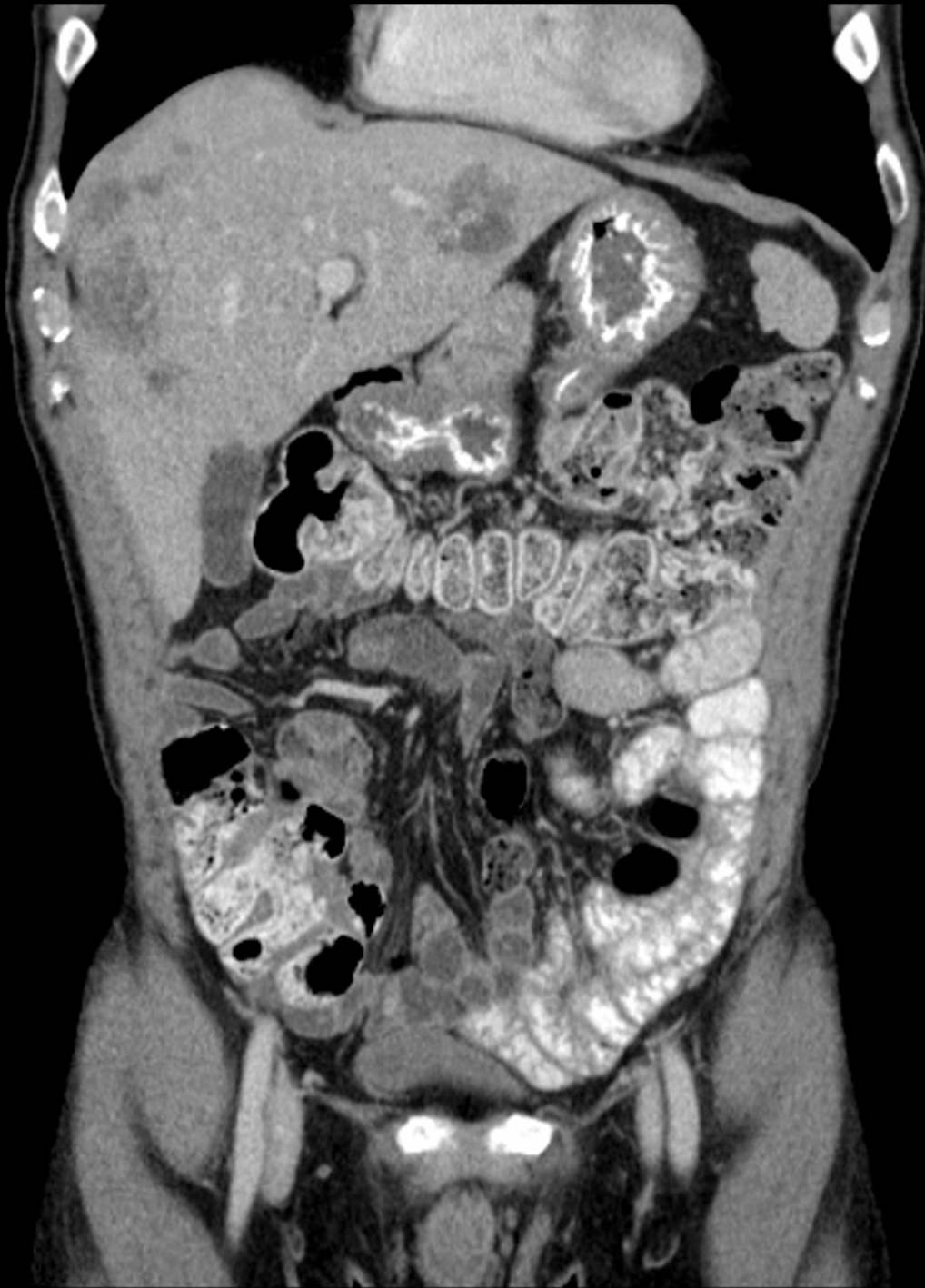











CT findings

- Multiple (>10) bilateral hepatic metastases
 - Largest in R lobe 7.1 cm, Largest in L lobe 6.1 cm
- Hepatobiliary surgeon consulted – confirmed lesions not amenable to resection

Management Options



- **Surgical resection of primary or straight to chemotherapy?**
- **Discussion**

Clinical Course

- Patient comes back to ER 24 hours after scope with LLQ pain and tenderness, temp 38.2, WBC 13, VSS
- CT
 - Small contained perforation proximal sigmoid
 - Spicules of extraluminal air, minimal surrounding fluid
- CXR normal (no free air)
- **Now what?**

Clinical Course



- Admitted to hospital
- NPO, IV Fluids, Antibiotics
- Feeling normal after 36 hours
- **Now what?**



- Options discussed with medical oncology
- Med onc not comfortable starting chemo given perforation
- Proceeded to OR on same admission
 - MIS anterior resection
 - No diversion
 - Discharged POD#4

Pathology

- Adenoca extends into mesocolonic fat with 8mm excursion beyond muscularis propria (T3)
- All margins clear
- 1/16 nodes positive (N1)
- Lymphovascular invasion
- No perineural invasion

Adjuvant Therapy



- Started on Q2wk FOLFIRI + bevacizumab
- Restaging CT after 5 cycles showed slight interval decrease in hepatic mets, though still multiple lesions

Literature Review : Asymptomatic Stage IV Colorectal Cancer

- Do these patients need intervention upfront?

Symptomatic vs Asymptomatic



- Key issue
- Definitions of “symptomatic” vary
- Symptomatic patients (bleeding requiring transfusion, perforation, obstructing), should be offered intervention



Asymptomatic Primary Tumours



- Why are we even asking?
- Because surgical resection has high morbidity (21%) in this population
- Surgical complications delay systemic therapy
- Systemic therapy treats the primary as well as the mets

Surgery vs Chemo

- Systematic review of 7 studies (850 pts- 536 having surgery first)
- With tumour in situ 13.9% obstructed (21% left and 12% right), 3% bled.
- Post op morbidity 18.8-47% (11.8% major)
- Post op mortality 10%
- Median survival in chemo grps 8.2-22 months (no bevacizumab)
- Median survival in surg grps 14-23 months

» Scheer M. Ann Onc 2008 19:1829-1835

Surgery vs Chemo

- Cochrane Review
- No randomized trials identified
- 798 studies of which 7 met the review criteria (nonrandomized controlled studies)
- 1,086 patients (722 had primary surgery, 364 had primary chemo or radiation)

Surgery vs Chemo

- No evidence of consistent improvement in overall survival with intervention
- No significant decrease in risk of complications related to the primary tumour
- Randomized trials needed
 - » Cirocchi, R. Cochrane Database Issue 8 Art No CD 008997

Chemo with Bevacizumab



- Prospective trial of primary mFOLFOX6 and bevacizumab without resection of primary (NSABP Trial C-10)
- Important because all the med oncs want to use bevacizumab now and all are worried about perforations so they want you to operate!



Chemo with Bevacizumab (Intact Primary, Stage IV Ca Colon)



- Multicentre; 99 patients (86 with follow-up)
- Median f/u was 20.7 months
- 14% (12 patients) had complications of intact primary (most obstruction)- 10 had surgery and 2 died
- 16.3% morbidity at 24 months
- Median overall survival 19.9 months (note similarity to previous reviews without bev)

Chemo with Bevacizumab (Intact Primary, Stage IV Ca Colon)



- Conclusion: Combination treatment with intact primary did not result in unacceptable complications and did not compromise survival
- **Initial noncurative resection can be avoided**
 - » Chang, G. JCO Sept 2012; 30(26): 3165 (editorial)
 - » McCahill L, et al. JCO Sept 2012; 30(26): 3223-3228



- Note: defined asymptomatic “no evidence of bowel obstruction or perforation and no active bleeding requiring a transfusion”
- Didn't specify how obstruction was defined (clinically or to the endoscope)

Unanswered Questions



- Should endoluminal surveillance be done to avoid emergency resection in patients progressing on treatment?
 - Given literature on stenting, a patient the is progressing to obstruction could be stented prophylactically
- Is there a survival advantage to resection of the primary?
 - Karoui M DIS Colon Rectum 54:930-938, 2011
 - Median survival of 30.7 (resected) vs 21.9 months (unresected) (p=0.031)
 - Not a randomized study (selection bias?)



- So, going back to this case;
- Had the patient not been perforated by the colonoscopy, there is evidence that surgery can be avoided

3. Locally advanced right colon cancer

Presentation



- 62 year old man
- Longstanding right upper quadrant pain
- Melena stools x 6 months
- Erratic bowel habits
- Referred to GI for colonoscopy



Colonoscopy

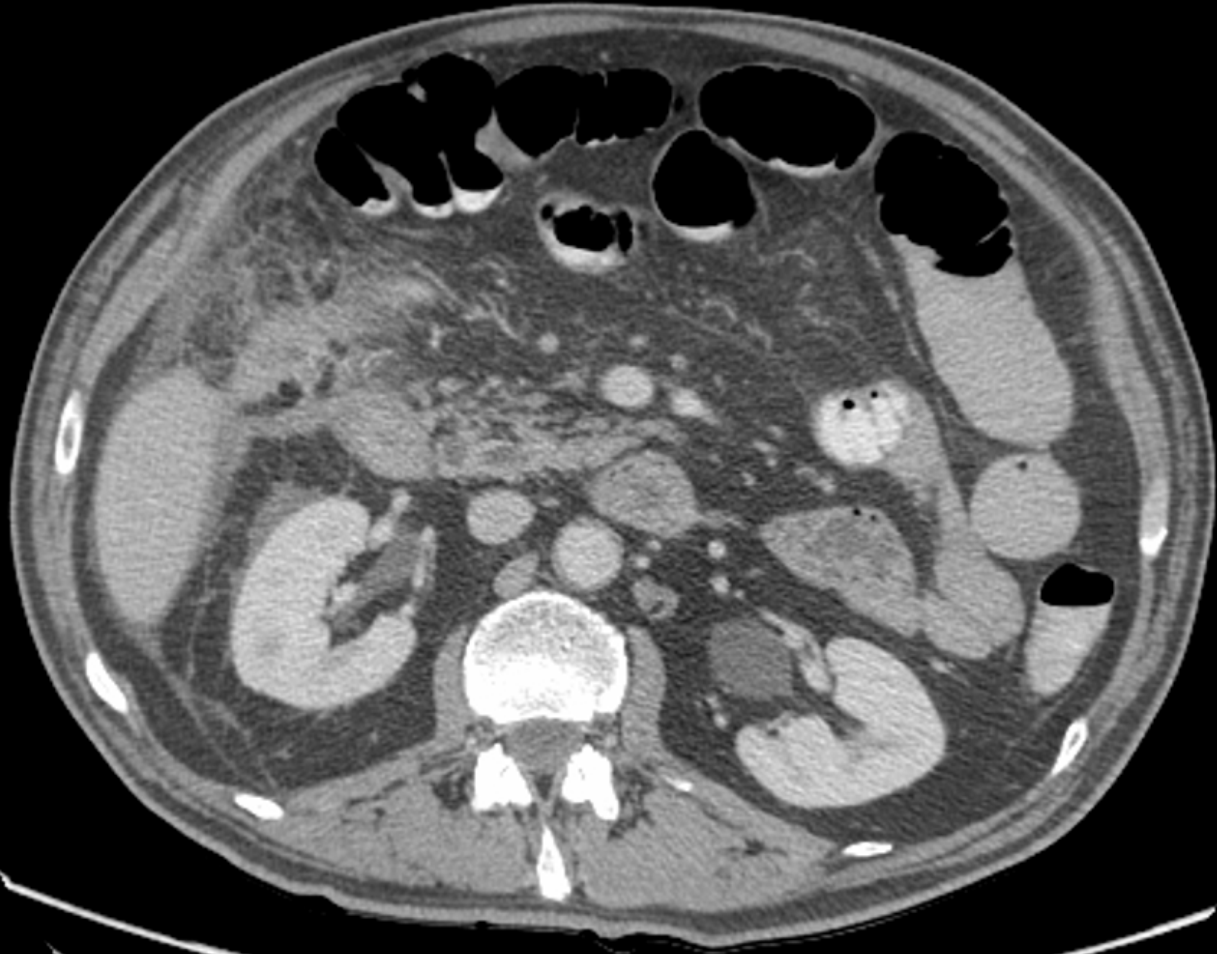


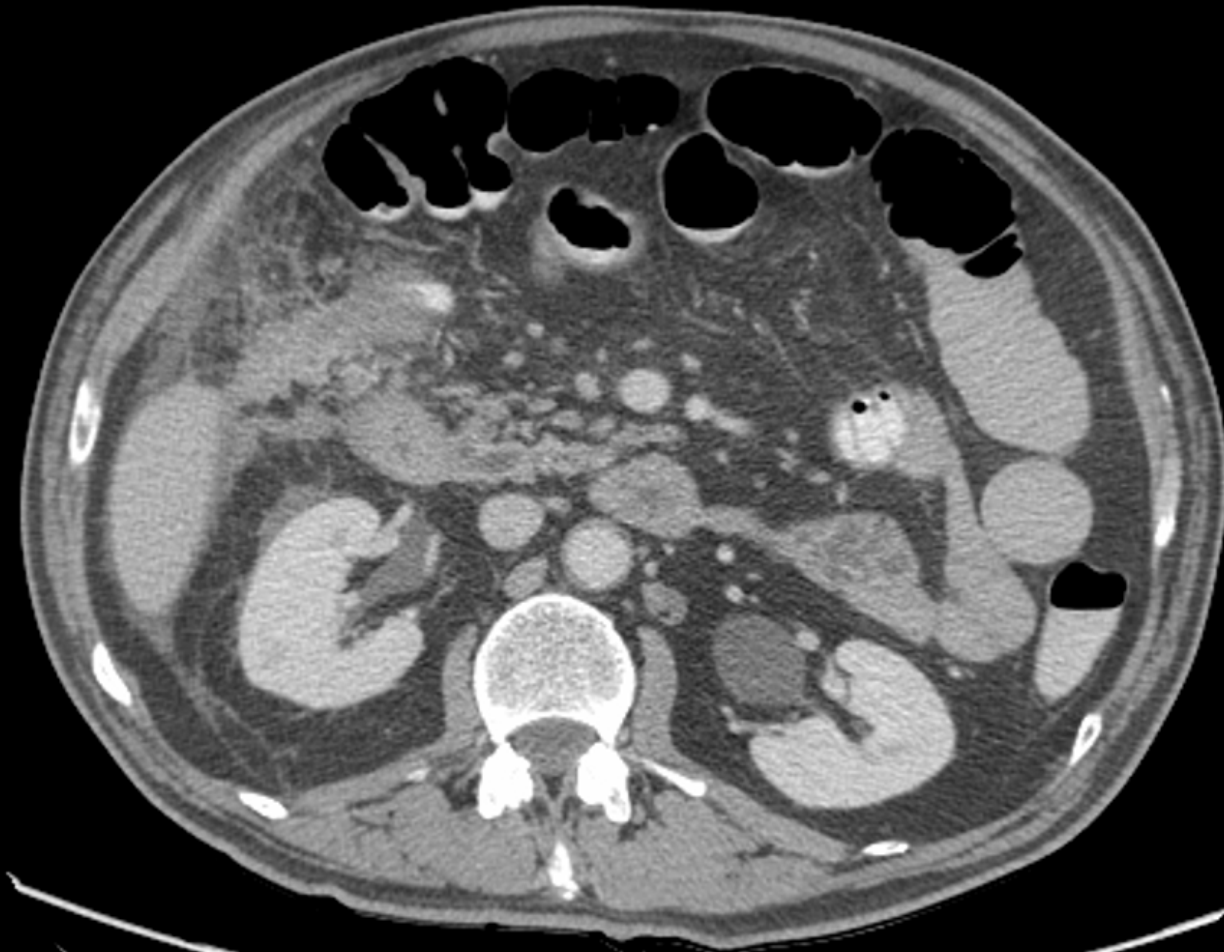
- Large fungating tumour hepatic flexure
 - Bx = poorly differentiated adenoca
- Rest of colon normal

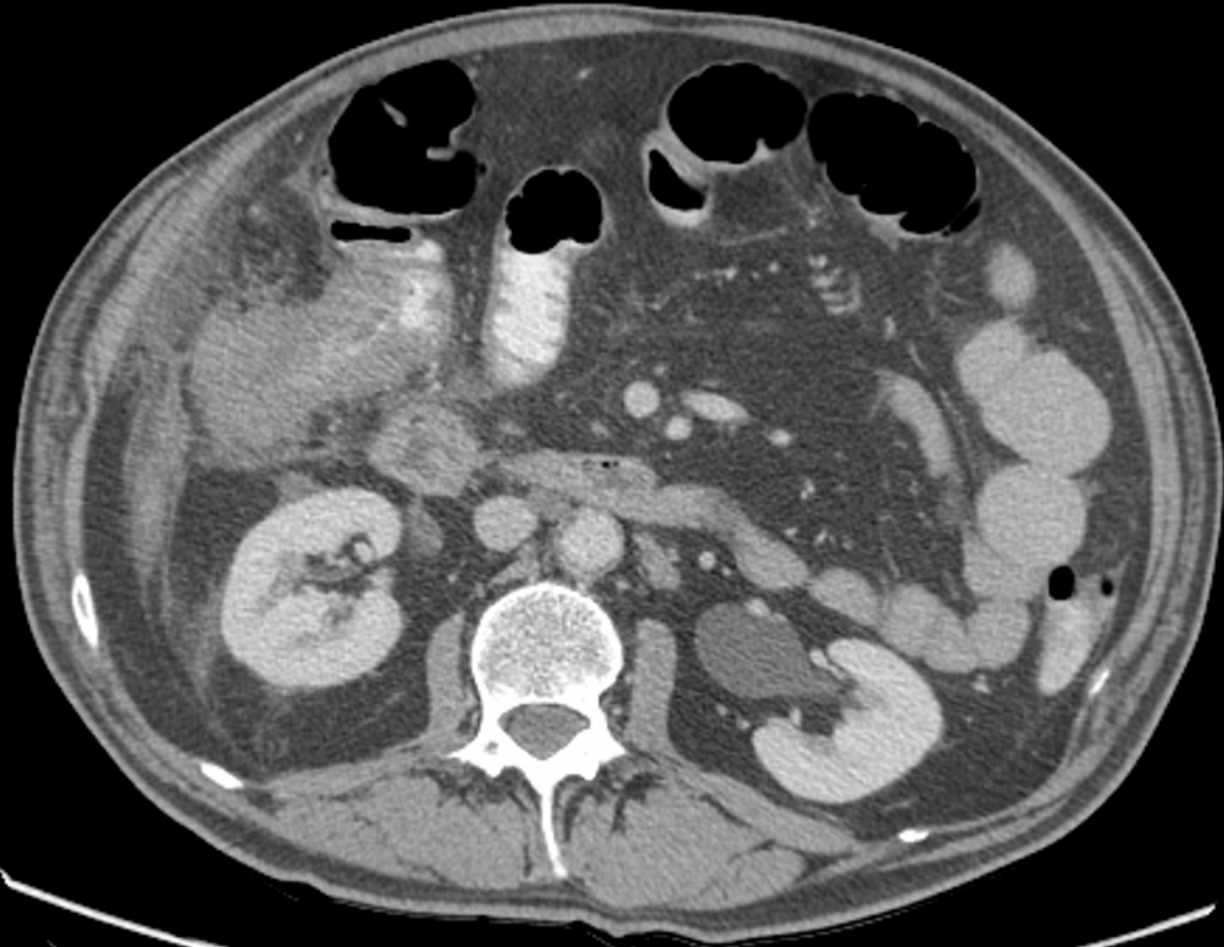
- Referred to surgeon
- Staging CT ordered

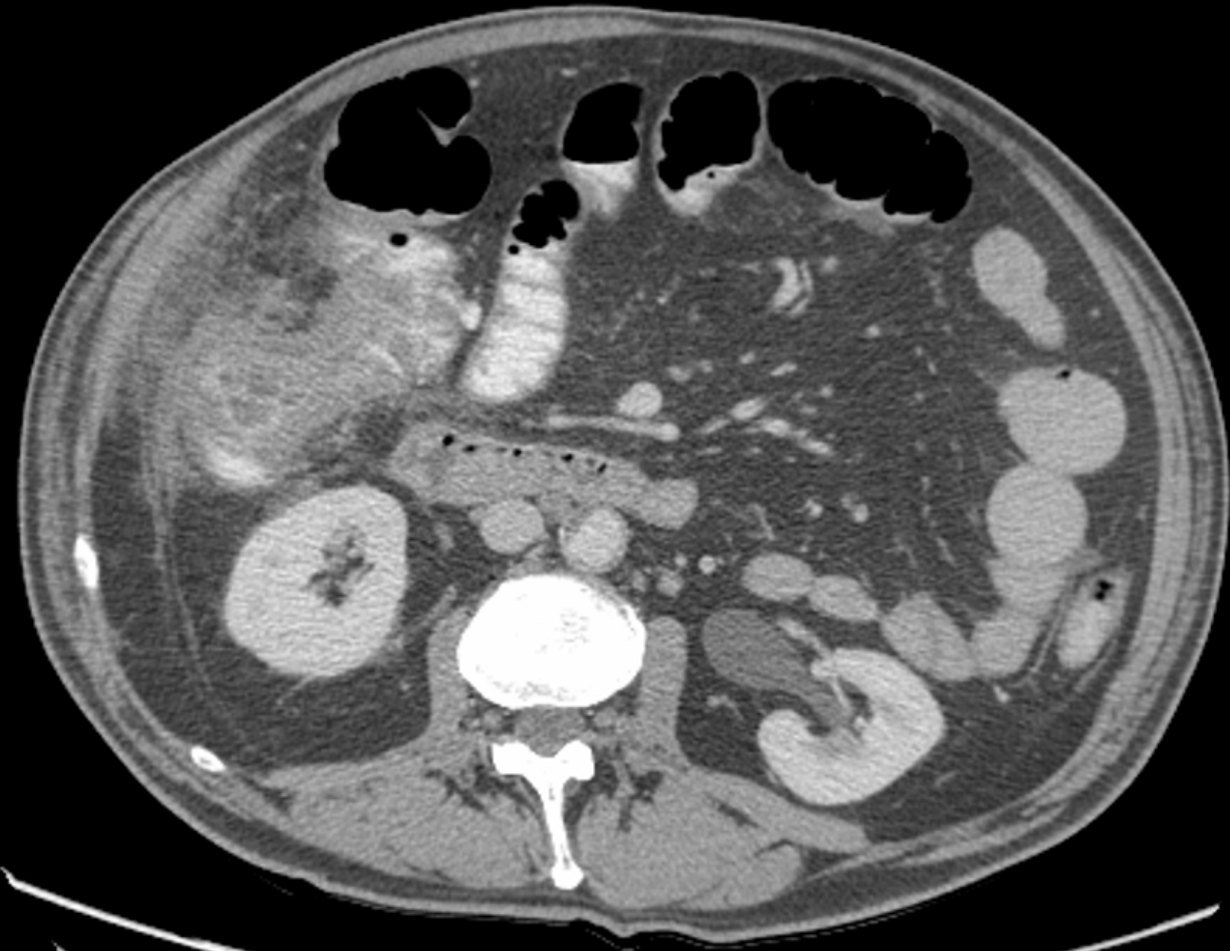
Surgical Consult

- Daily melena stools
- Weight loss 25 lbs/6 months
- Poor appetite
- RUQ pain constant
- Tender RUQ – firmness palpable
- PMHx: GERD, PUD
- Meds: PPI, T#3 prn



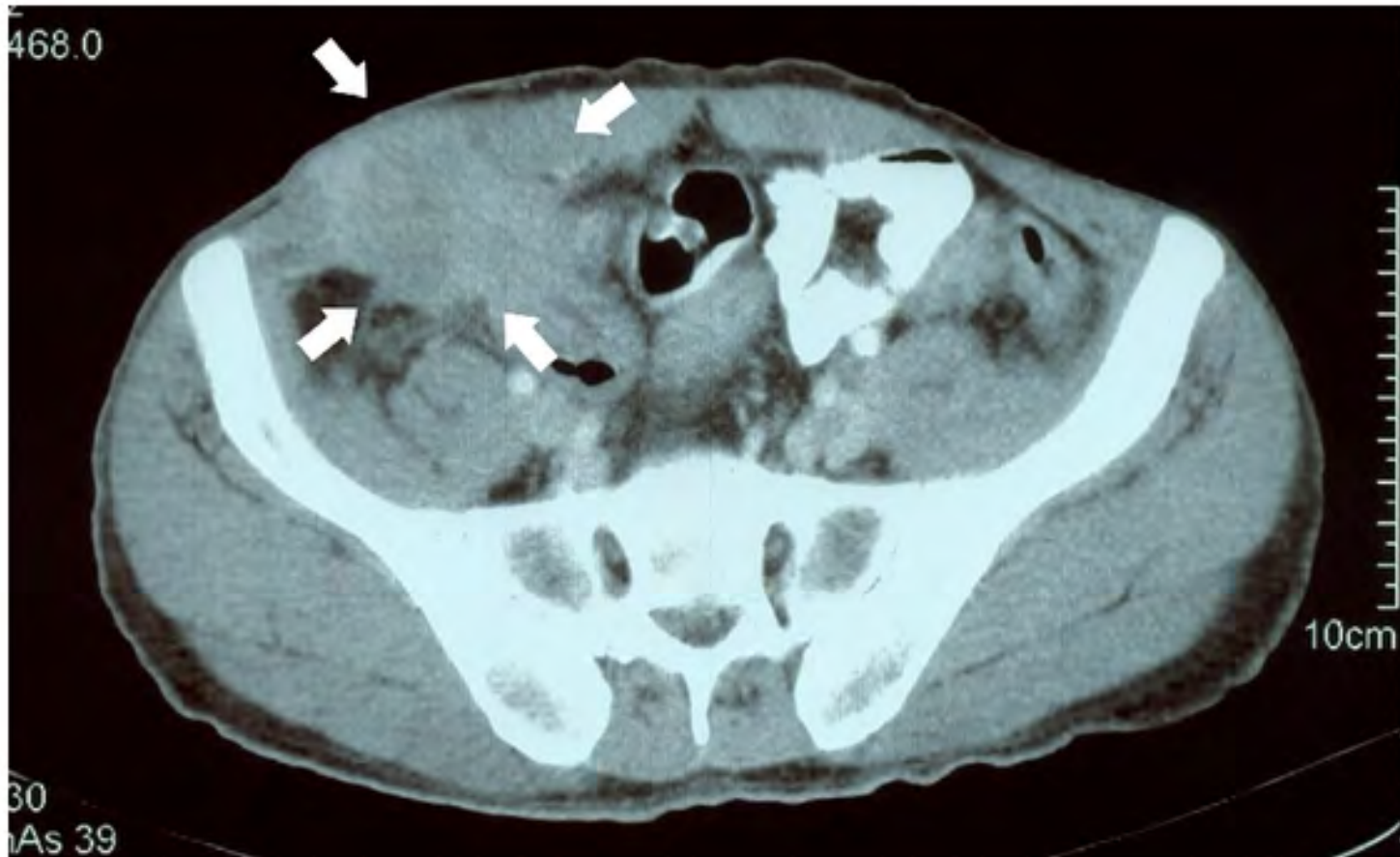






- Large ascending colon and hepatic flexure mass concerning for invasion into right abdo wall, liver, duodenum, loop of small bowel
- Surrounding fat stranding
- No obvious distant mets
- Chest clear

***Other CTs with more prominent
wall invasion courtesy of
Google image search***



Next Steps for Discussion



- Would you get a PET scan?
- Would you proceed straight to surgery?
- If so, what would be your operative plan
- Is there a role of preop radiation and/or chemotherapy in colon cancer invading abdominal wall or liver?

Clinical Course



- Decision was made to proceed to OR
 - Large mass adherent to abdo wall and inferior surface of liver
 - Extended open right hemicolectomy with en bloc resection of abdo wall, partial hepatectomy (LigaSure), small bowel resection and cuff of duodenum
- Transient bile leak – self-resolved
- Discharged home POD #12

Pathology

- Adenocarcinoma, “grade 2”
- Tumour directly invading duodenum, liver, abdo wall (T4b)
- 27/31 lymph nodes positive (N2)
- Positive for lymphovascular and perineural invasion
- All margins negative (3mm at abdo wall)
- Patient referred to BCCA (pending consultation)

Literature Review Locally Advanced Colorectal Cancer

Definition of a Locally Advanced Cancer



One that, in the assessment of the multidisciplinary team cannot be resected without a high likelihood of leaving microscopic or gross residual disease at the local site because of tumor adherence or fixation.

Assessment of Resectability



- Most of the literature is on rectal cancers
- Thin cut MRI (more sensitive 97% than CT 70% for local invasion)
- Endorectal US for rectal lesion
- Digital exam for rectal lesion

Management

(Locally Advanced Rectal Ca)



- Preoperative combined chemoradiation (5FU and leukovorin) better than radiation alone
- Randomized trial 207 pts
 - Higher R0 resection (84 vs 68%)
 - Better 5 year local control (82 vs 67%)
 - Better failure free survival (63 vs 44%)
 - Better cancer specific survival (72 vs 55%)
 - » Braendengen J. JCO 2008;26:3687



- Following preoperative therapy, plan multivisceral resection of adherent structures
- 40-84% malignant involvement of adhesions
 - » Nelson H et al. J Natl Cancer Inst 2001;93:583
- Better local control and survival with multivisceral resections
 - » Lopez MJ. J Surg Oncol 2001; 76:1
 - » Nakafusa Y et al. Dis Col Rec 2004;47:2055
 - » Rowe VL et al. Ann Surg Oncol 1997;4:131
 - » Lehnert T et al. Ann Surg 2002;235:217
 - » Luna-Perez et al. J. Surg Oncol 2002;80:100
 - » Poeze M et al. Br J Surg 1995;82:1386
 - » Govindarajan A et al. J. Natl Cancer Inst 2006;98:1474

Contraindications to Radical Resection of Rectal Cancers



- Proximal sacral/nerve root Involvement
- Proximal nodal disease (paraaortic)
- Iliac vessel encasement
- Bilateral ureteric obstruction
- Unresectable metastatic disease
- Circumferential pelvic involvement- sacrum and side wall



Outcomes

- 5 year overall survival with exenterative surgery 43-64%
 - » Pawlik et al. Ann Sur Oncol 2006;13:612
 - » Law et al. J Am Coll Surg 2000; 190:78
- Periop mortality rates <5 % in specialized centres
- Periop morbidity 47-61%

Management of R1 Resections



- Postoperative RT is offered
- DOES NOT MAKE UP FOR AN INADEQUATE OPERATION
- Improved local control and survival if microscopic residual cf gross residual
- 5 yr Local control and DFS 70 and 45% (micro residual) vs cf 43 and 11 % (gross residual)
 - » Allee PE et al. Int J Radiat Oncol Biol Phys 1989;17:1171

- 10-20% of cases
- 139 lesions treated with en bloc resection of **adherent** structures showed histologic evidence of tumor infiltration in 50% of cases (ie you can't tell)
- Controlled for stage, survival for multivisceral organ resection not significantly different of those not requiring multivisceral resection
 - » Landmann RG. Clin Colon Rectal Surg. 2005 August; 18(3): 182–189 (Review Article)
 - » Lehnert T et al. Ann Surg. 2002;235:217–225

Neoadj ChemoRads in Locally Advanced Colon Cancer



- Retrospective review of 33 patients treated with neoadjuvant chemoradiotherapy and multivisceral resection for primary locally advanced adherent colon cancer.
- Postoperative morbidity 36%
- No 30-day mortality.
- All 33 patients had microscopically clear resection margins (R0).
- 3-year OS and 3-year DFS were 87.6% and 63.7% respectively
- **High rates of R0 resection and excellent local control with acceptable morbidity and mortality.**
 - » M. Cukier J Clin Oncol 29: 2011 (suppl; abstr 3544)



Preop vs Post op Chemo in Locally Advanced Colon Cancer



- RCT (n=150) (pilot study of feasibility, safety, tolerance and accuracy of radiological staging)
- **No sig diff in postoperative morbidity**
- **Significant downstaging (p=0.04),**
 - Pathological complete responses (2 cases)
 - Apical node involvement reduced (1% vs 20% , p<0.0001)
 - Margin involvement reduced (4% vs 20%, p=0.002),
 - Radiologic regression grading higher: 31% vs 2% moderate or greater regression (p=0.0001)
- Will proceed to phase 3 trial to look at long term outcome
 - » The Lancet Oncology, Early Online Publication, 25 September 2012
 - » Feasibility of preoperative chemotherapy for locally advanced, operable colon cancer: the pilot phase of a randomised controlled trial (FOxTROT group)

- So, going back to the case of the right colon cancer involving abdominal wall, liver and duodenum
- Current literature would suggest preoperative therapy (chemo +/- rads) followed by radical surgery rather than proceeding to OR first.