

# Hepatocellular Carcinoma (HCC) Cases for FPON

Janine M. Davies MD BN MSc FRCPC  
Clinical Assistant Professor  
BC Cancer/ University of British Columbia

Family Practice Oncology Network: Oncology CME Webcast  
Nov 17, 2022



# Learning Objectives

1. Identify risk factors for hepatocellular carcinoma (HCC)
2. Summarize monitoring recommendations for those at increased risk of developing HCC
3. Review management of HCC

# Disclosures

- Advisory- Apotex, Eisai, Incyte, Astra Zeneca
- Grants/trials- BMS, NCIC
  
- I will declare off-label use of medications

CASE 1: Mr AFP

# Mr AFP

- 63 year old man, professional artist and business owner
- Comorbidities:
  - Leydig cell testicular cancer with orchiectomy (2003), no issues since.
  - DM2, not on insulin.
- Sept 2020- RUQ pain.
- CT scan w/ contrast- **single lesion in segment V/VIII measuring in total 6.4 x 4.2 x 7.9 cm.**
- Further history- No Hx HBV, HCV, ETOH minimal

# Polling Q- What are risk factors for HCC?

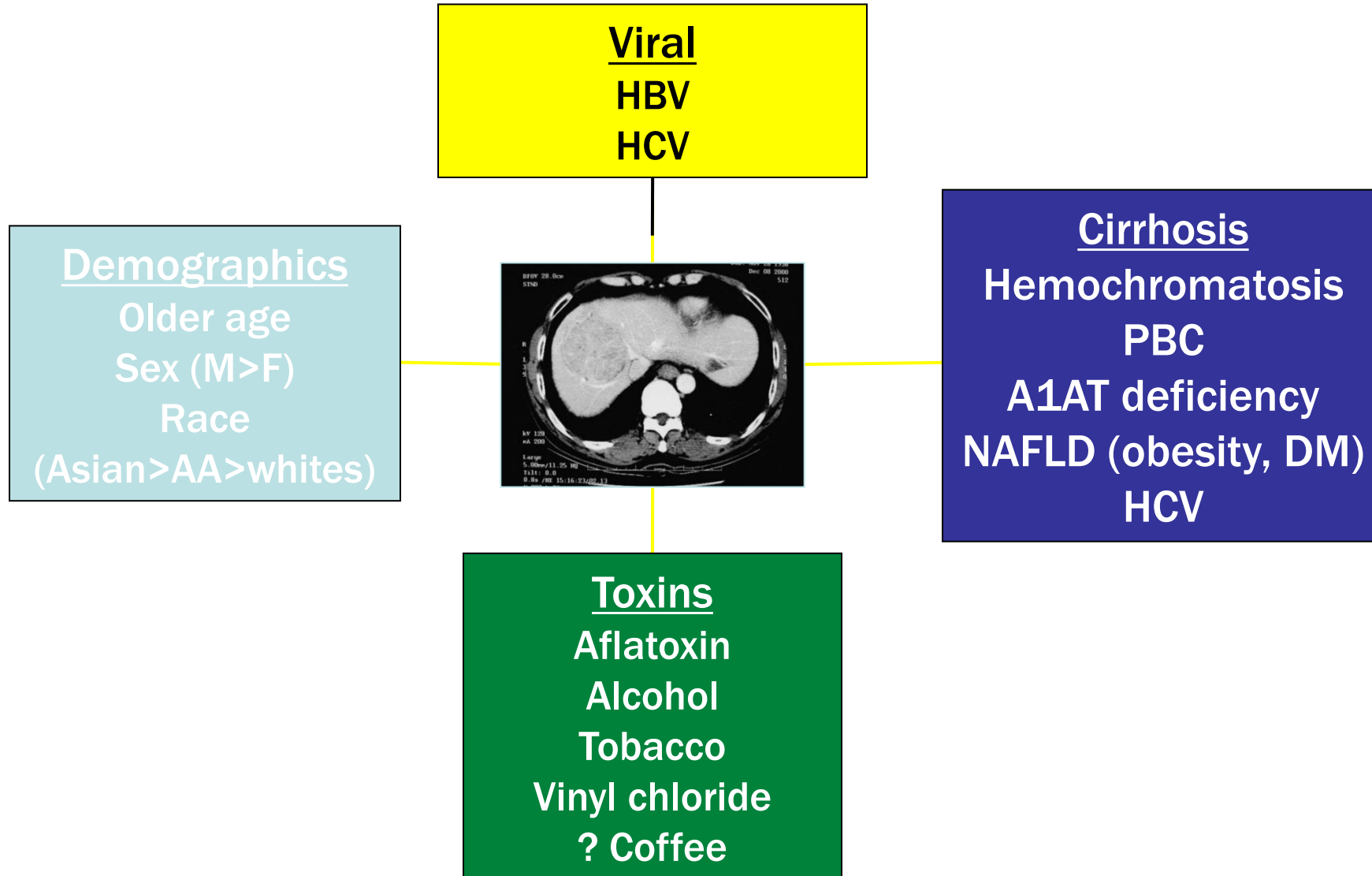
- a) HBV, HCV
- b) Etoh
- c) Cirrhosis
- d) NAFLD
- e) Hemochromatosis, alpha-1 antitrypsin def, PBC, Wilson's
- f) Toxins: aflatoxin
- g) All of the above

# Polling Q- What are risk factors for HCC?

- a) HBV, HCV
- b) Etoh
- c) Cirrhosis
- d) NAFLD
- e) Hemochromatosis, alpha-1 antitrypsin def, PBC, Wilson's
- f) Toxins: aflatoxin
- g) All of the above**

# Risk Factors for HCC

---





# Screening (AASLD guidelines)

- Adults with cirrhosis, Child-Pugh A or B
- Other:
  - HBV- start screening at 40 for Asian males, 50 for Asian females, and 20 for African descent
  - FHx of HCC

→ u/s + AFP q6 mo

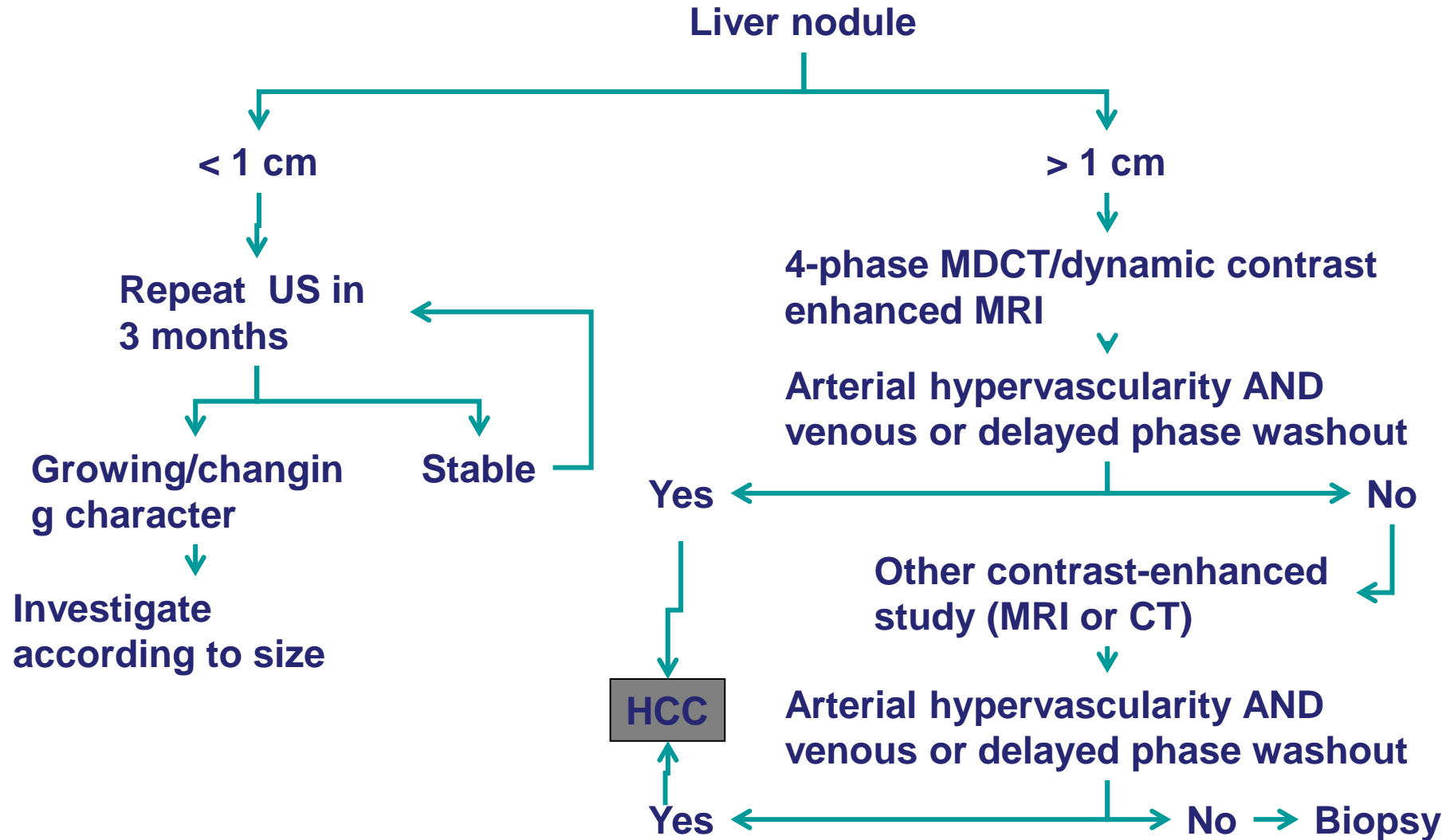
Polling Q- In this patient, what test do we  
**NEED** to diagnose HCC?

- a) Triphasic CT scan
- b) Multiphase MRI liver
- c) Liver biopsy
- d) All of the above

Polling Q- In this patient, what test do we  
**NEED** to diagnose HCC?

- a) Triphasic CT scan
- b) Multiphase MRI liver
- c) Liver biopsy**
- d) All of the above

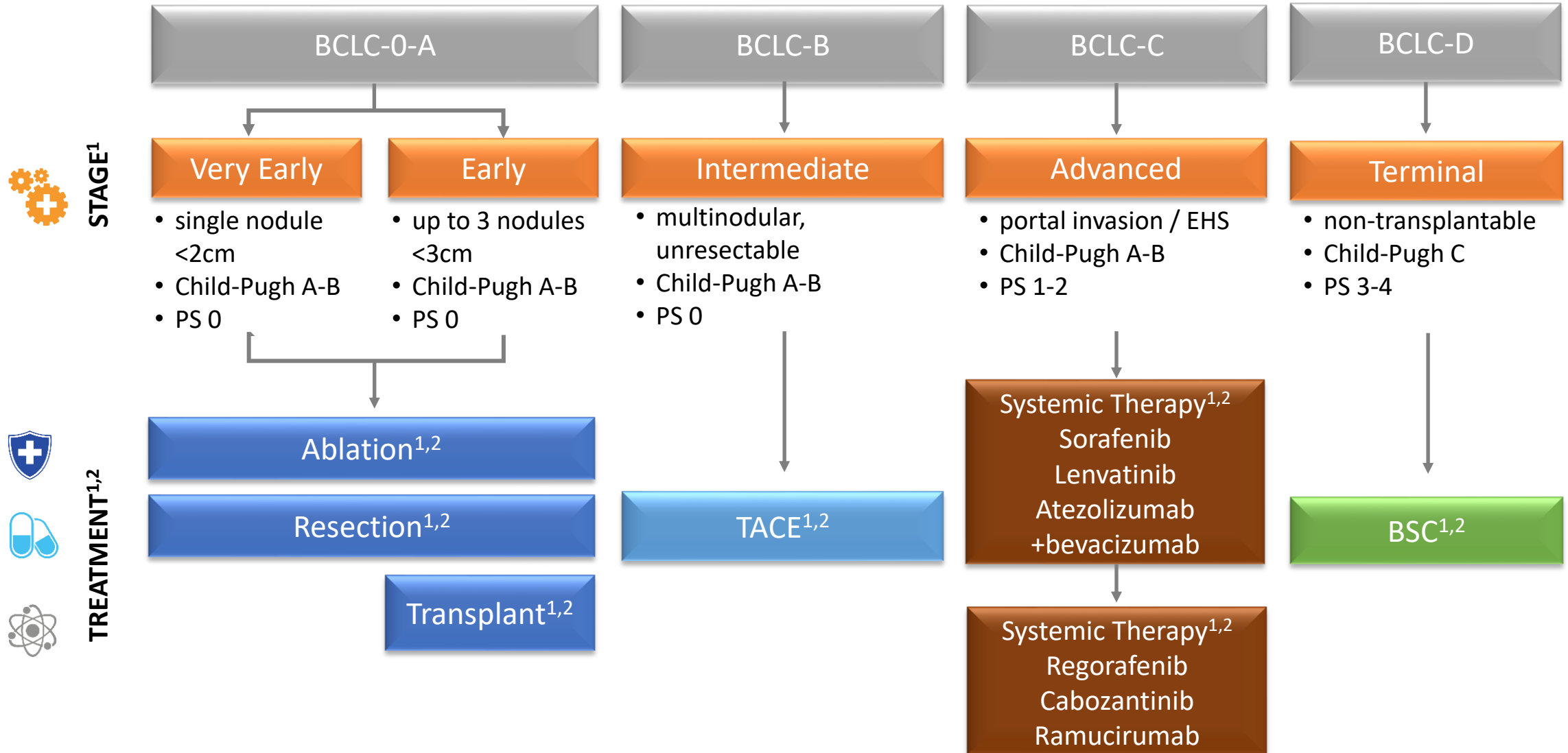
# Liver Nodule Evaluation



# Mr AFP

- In the absence of cirrhosis, Hep B or Hep C, a liver biopsy is needed to definitively Dx HCC
- Dec 2020 liver biopsy- hepatocellular carcinoma
  - Normal liver- ?NAFLD (unlikely Hereditary hemochromatosis, possible iron overload)

# BCLC Staging and Treatment of HCC



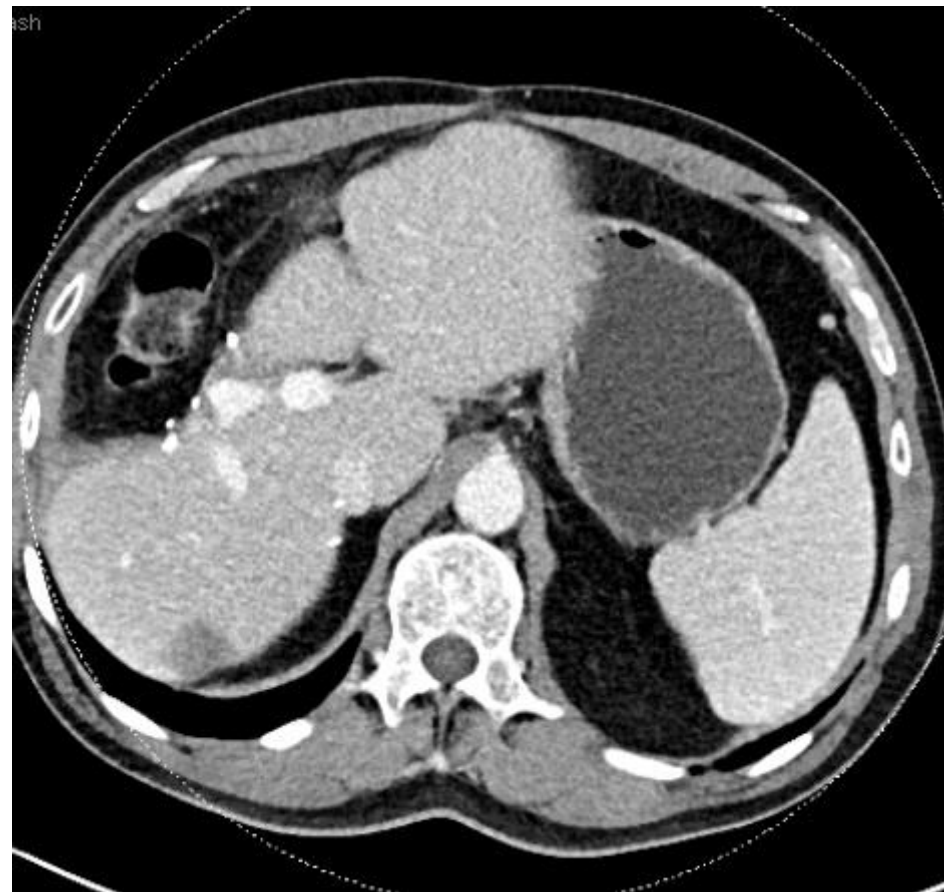
BCLC, Barcelona Clinic Liver Cancer; HCC, hepatocellular carcinoma; BSC, best supportive care; EHS, extrahepatic spread; PS, performance status; TACE, transarterial chemoembolization.

1. Forner A, Reig M, Bruix J. Lancet. 2018;391(10127):1301-1314. 2. ESMO Guidelines Committee. Ann Oncol 2018;29 (S4): iv238-iv255.

# Mr AFP

- Liver resection Mar 2021.
  - Mod diff HCC, scirrhous histologic variant, 7cm.
    - Confined to liver, no LVI, clear margin. pT1b.
  - Background mild to moderate iron accumulation- ?hemochromatosis and mild steatosis. Focal traces of periportal/centrilobular zone 3 fibrosis. No cirrhosis.
- Preop AFP >15,000, post op May 2021 was 30.
- Then on surveillance → triphasic CT scan May 2021- no liver lesions. Post op changes.

AFP- 4000 (Nov 2021)



LTR- suspicious →  
For MRI.



# Mr AFP

- F/up ultrasound : 5 liver lesions (3 were not seen on CT) concerning for multifocal HCC or LR-M\* lesions.
- Multifocal recurrent HCC
  - AFP in February 2022: 12,000.
- MRI Liver Mar 2022
  - increased segment 6 lesion (now 2.5 x 1.7cm).
  - New hypervascular lesion in segment seven 1.8 cm. The findings are suspicious for HCC.
  - Faint nonenhancing T2 hyperintense lesion is seen in segment two, of uncertain etiology.

\*LR-M- definitely malignant, not clearly HCC

# Mr AFP

- Recurrence of HCC, BCLC stage A, Child Pugh A, MELD 8.
- Liver Tumour Rounds: Potentially resectable/liver transplant eligible
  - Given significantly elevated AFP and change in size within a short time interval, ? more extensive/aggressive disease
    - systemic therapy with the intent of achieving disease control while bridging to definitive surgery.

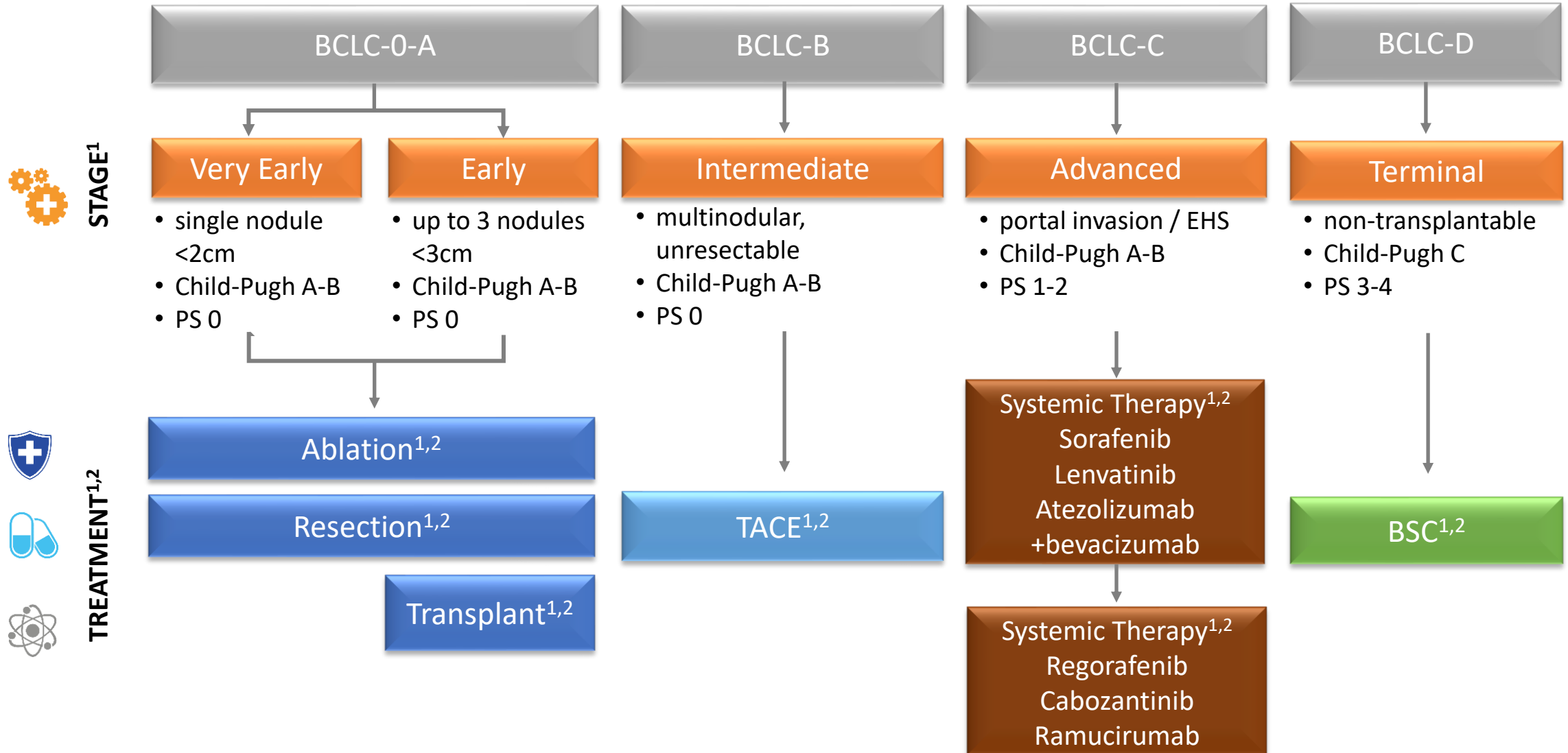
# Polling Q- What are potential 1<sup>st</sup> line systemic therapies for HCC?

- a) Sorafenib (tyrosine kinase inhibitor [TKI])
- b) Lenvatinib (TKI)
- c) Atezolizumab/Bevacizumab (immunotherapy/VEGF inhibitor)
- d) Durvalumab/Tremelimumab (immunotherapy)
- e) All of the above

# Polling Q- What are potential 1<sup>st</sup> line systemic therapies for HCC?

- a) Sorafenib (tyrosine kinase inhibitor [TKI])
- b) Lenvatinib (TKI)
- c) Atezolizumab/Bevacizumab (immunotherapy/VEGF inhibitor)
- d) Durvalumab/Tremelimumab (immunotherapy)
- e) All of the above**  
(but durva/treme not HC approved)

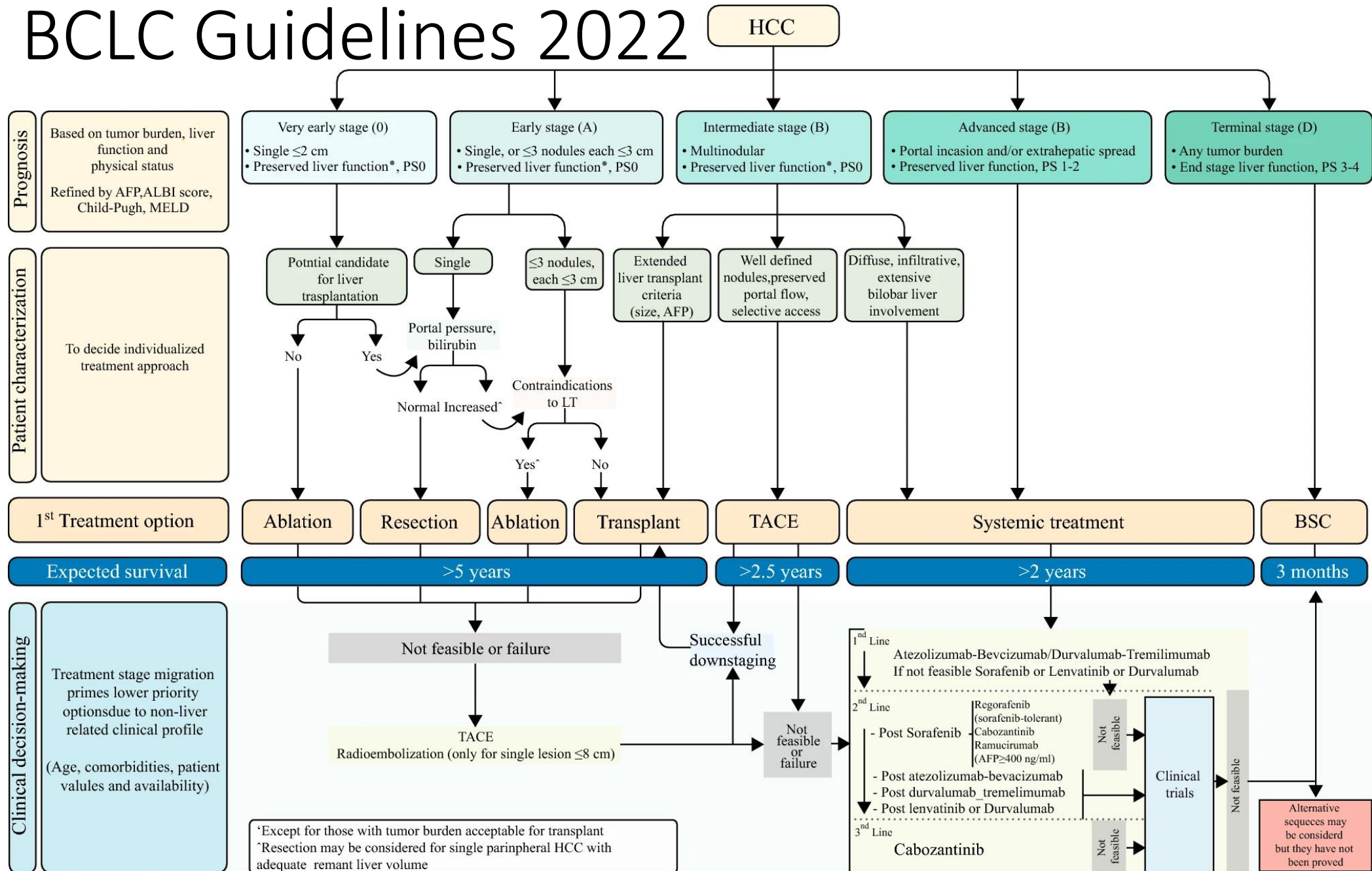
# BCLC Staging and Treatment of HCC



BCLC, Barcelona Clinic Liver Cancer; HCC, hepatocellular carcinoma; BSC, best supportive care; EHS, extrahepatic spread; PS, performance status; TACE, transarterial chemoembolization.

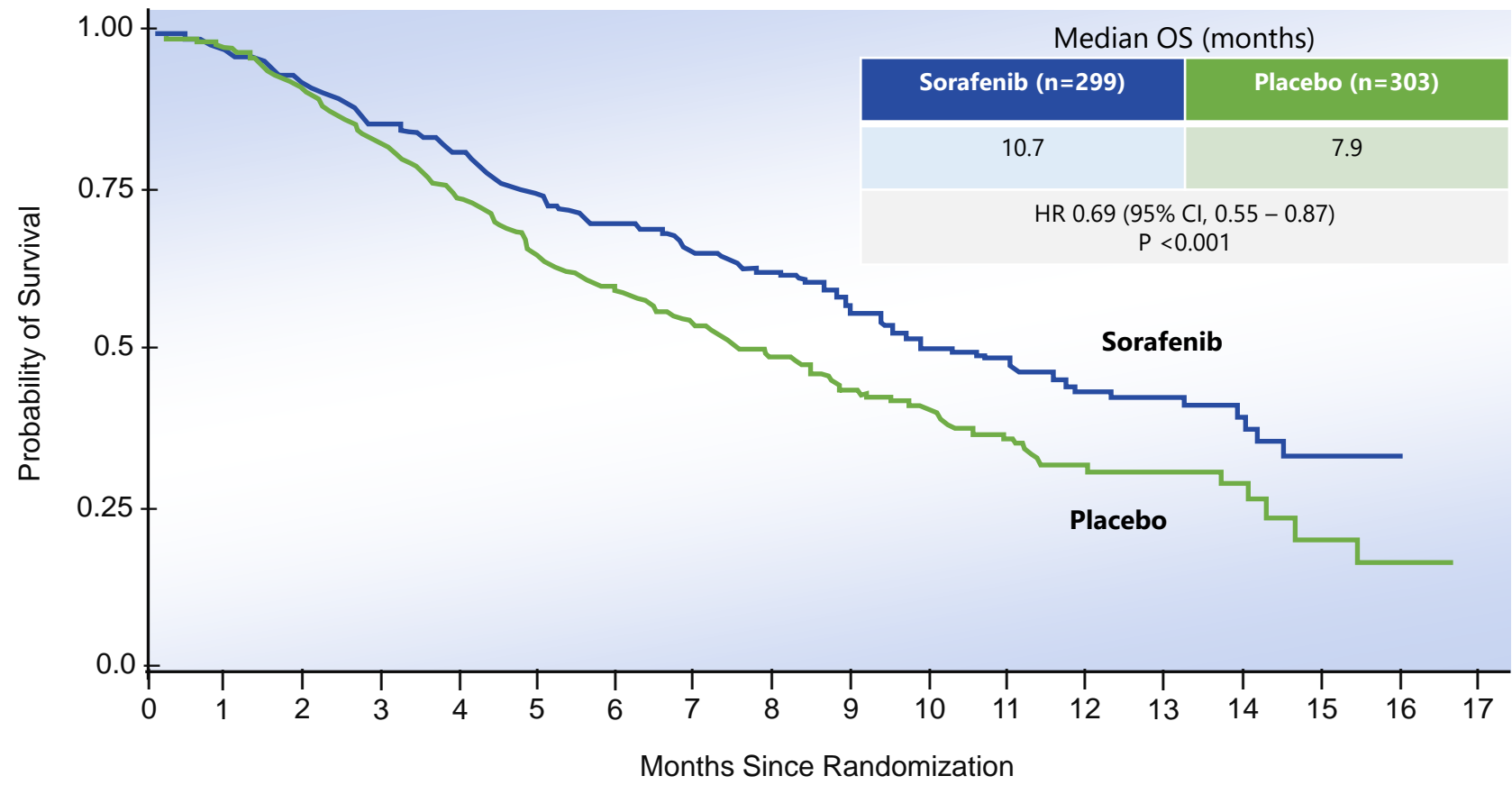
1. Forner A, Reig M, Bruix J. Lancet. 2018;391(10127):1301-1314. 2. ESMO Guidelines Committee. Ann Oncol 2018;29 (S4): iv238-iv255.

# BCLC Guidelines 2022



# SHARP: Advanced HCC, Child–Pugh A, ECOG PS 0-2, N=602

Sorafenib



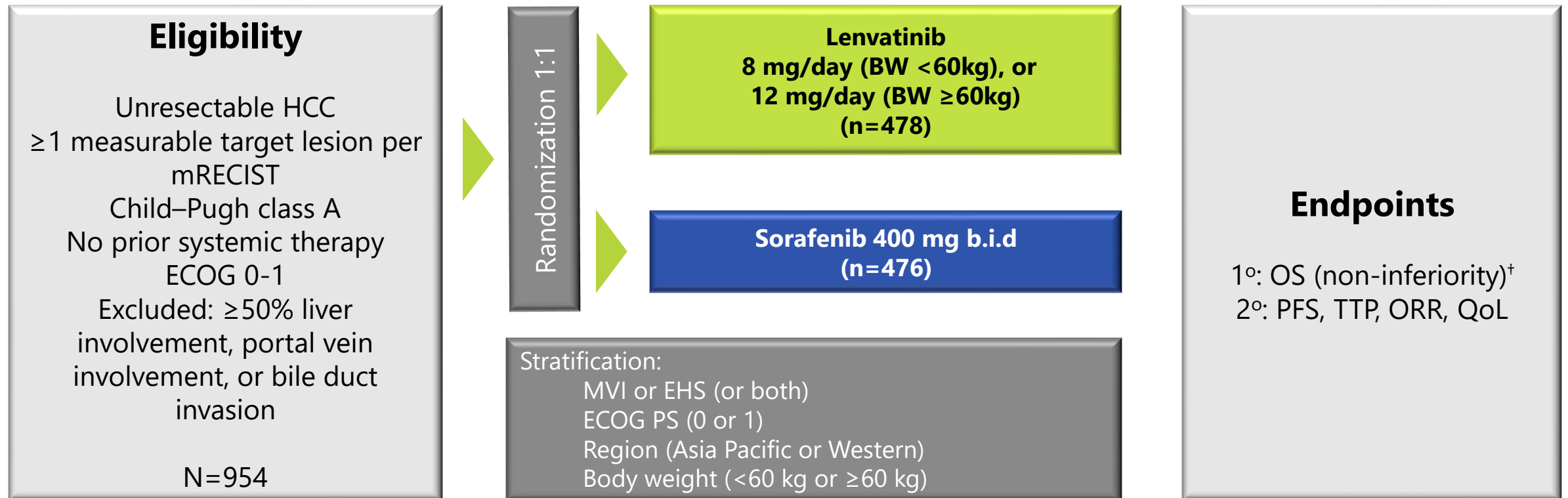
No. at risk	0	1	2	3	4	5	6	7	8	9	10	11	12	13	14	15	16	17
Sorafenib	299	290	270	249	234	213	200	172	140	111	89	68	48	37	24	7	1	0
Placebo	303	295	272	243	217	189	174	143	108	83	69	47	31	23	14	6	3	0

CI, confidence interval; HR, hazard ratio; OS, overall survival  
1. Llovet JM, et al. N Engl J Med 2008;359:378-90.

# REFLECT: Study Design

Lenvatinib

A phase III, multicentre, randomized, open-label, non-inferiority trial<sup>1</sup>

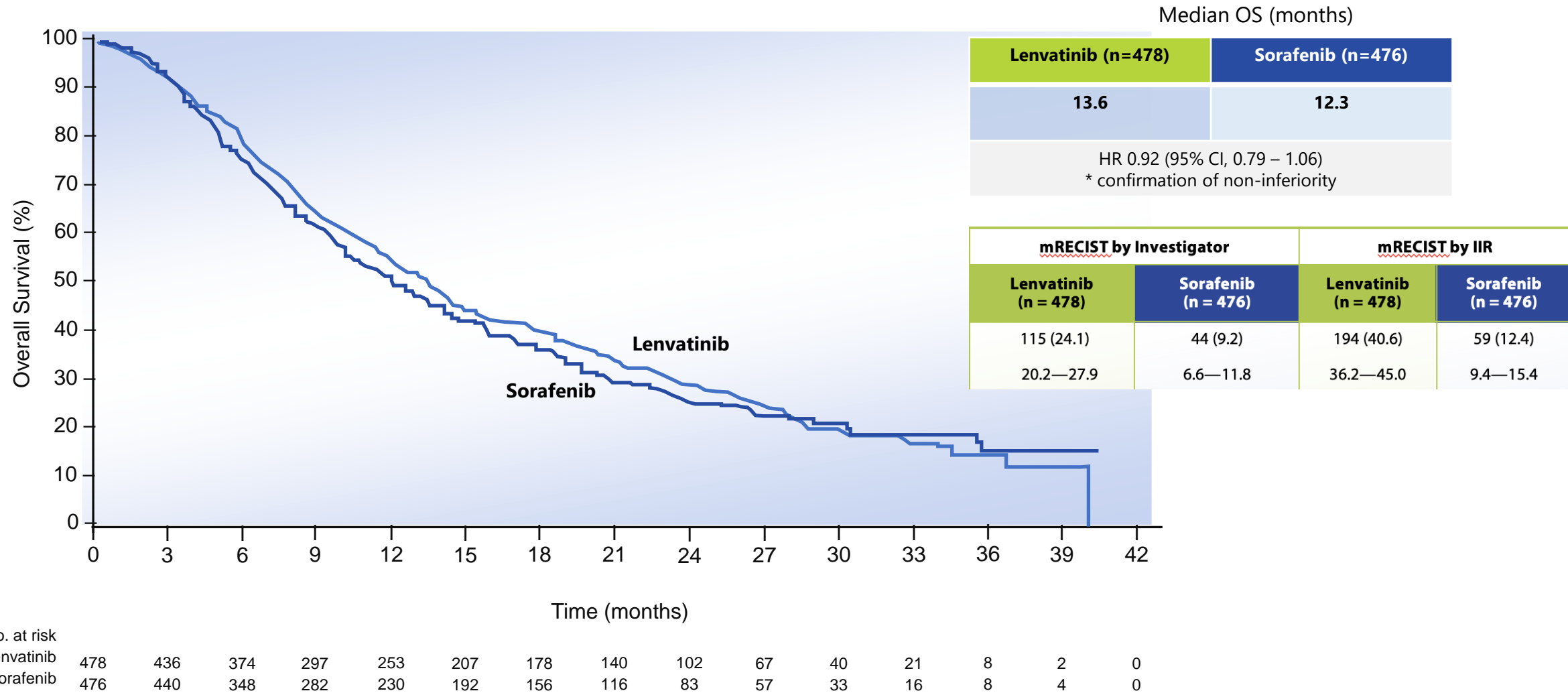


<sup>†</sup>Non-inferiority was declared if the upper limit of the two-sided 95% CI for HR was less than 1.08, overall type I error rate at  $\alpha=0.05$  (two-sided)  
bid, twice a day; ECOG PS, Eastern Cooperative Oncology Group performance status; HCC, hepatocellular carcinoma; EHS, extrahepatic spread; HR, hazard ratio; MVI, macroscopic vascular invasion; OS, overall survival; TTP, time to progression; ORR, objective response rate; PFS, progression-free survival; QoL: Quality of Life.

1. Kudo M, et al. Lancet. 2018;391(10126):1163-1173.



# REFLECT: OS



\*Non-inferiority was declared if the upper limit of the two-sided 95% CI for HR was less than 1.08, overall type I error rate at  $\alpha=0.05$  (two-sided)

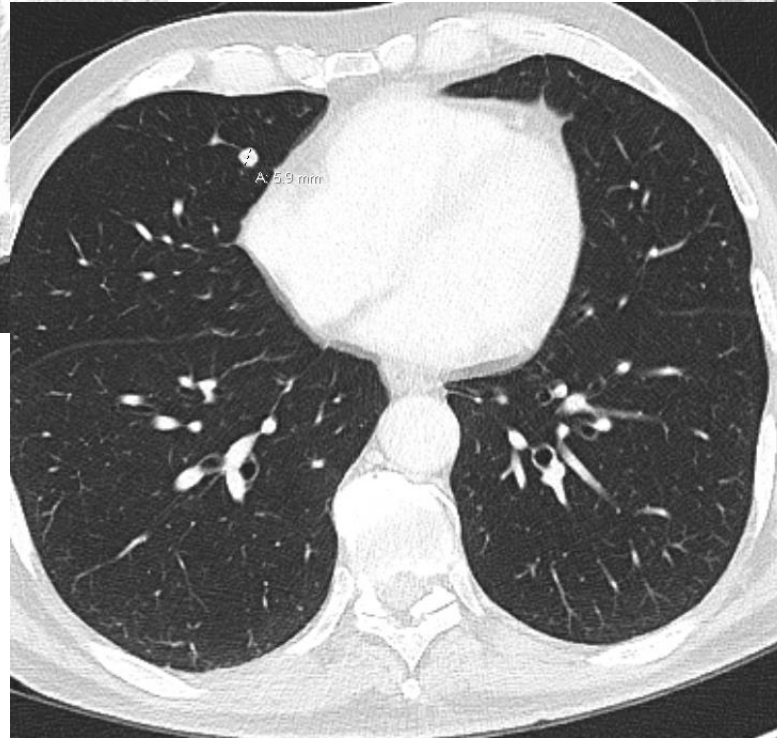
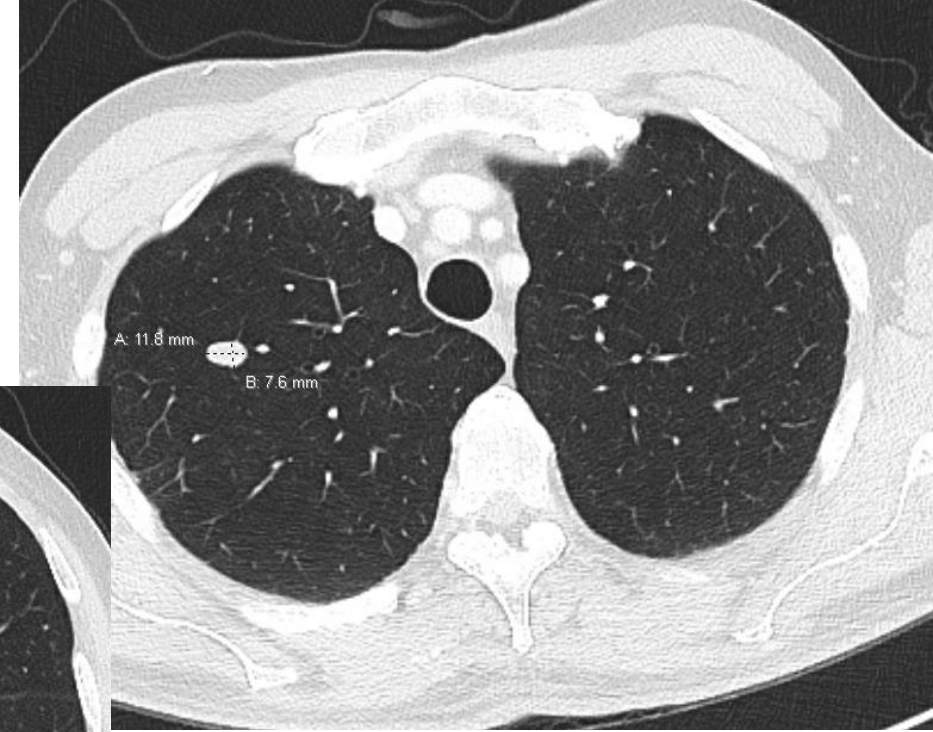
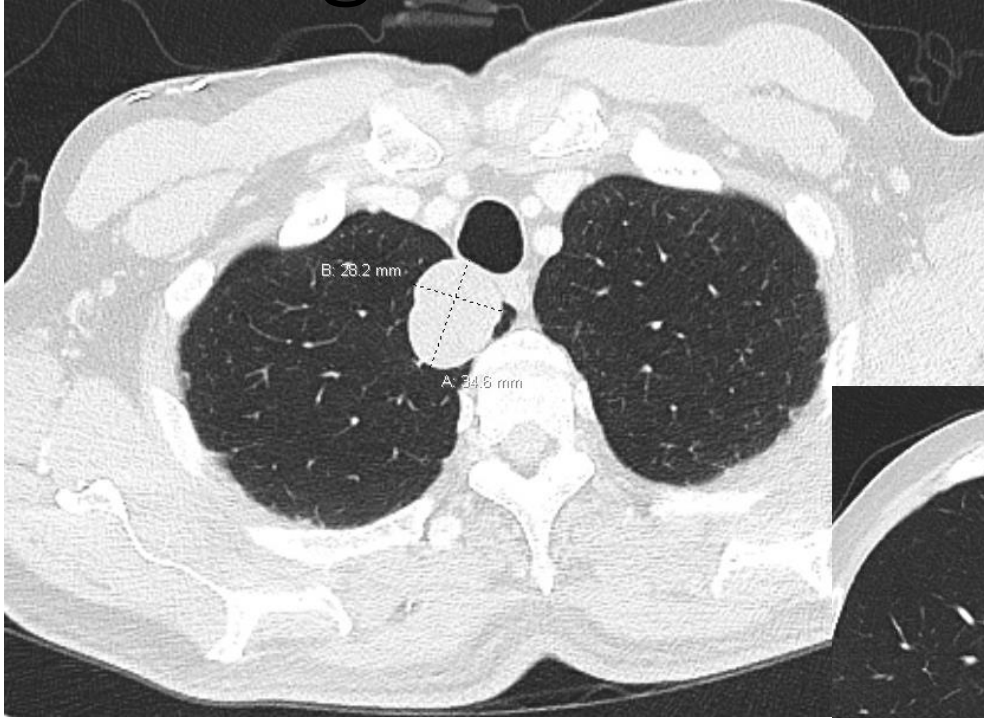
CI, confidence interval; HR, hazard ratio; OS, overall survival;

Kudo M et al. *Lancet*. 2018;391:1163-1173.

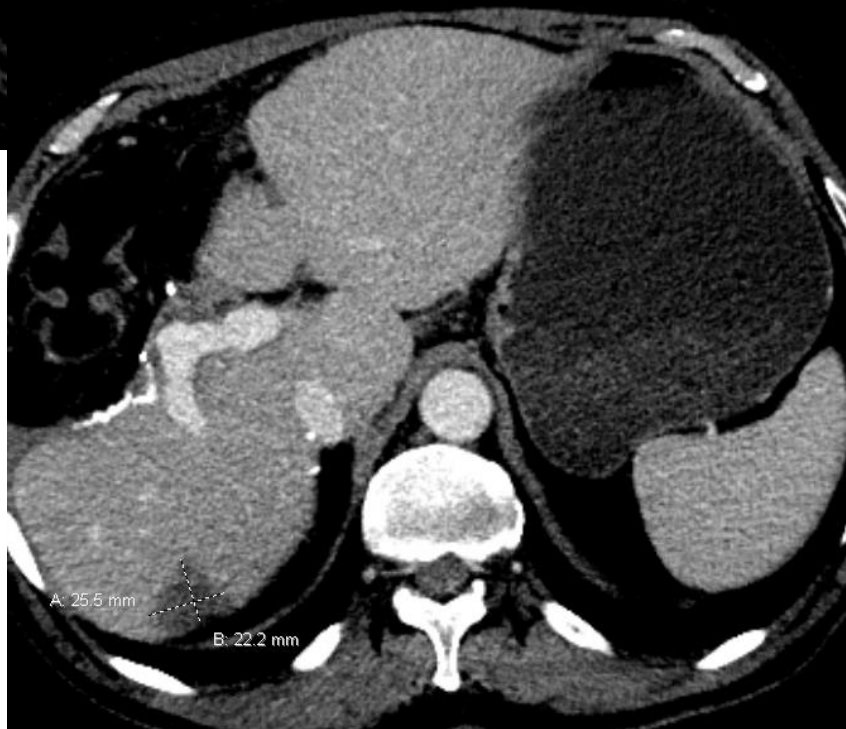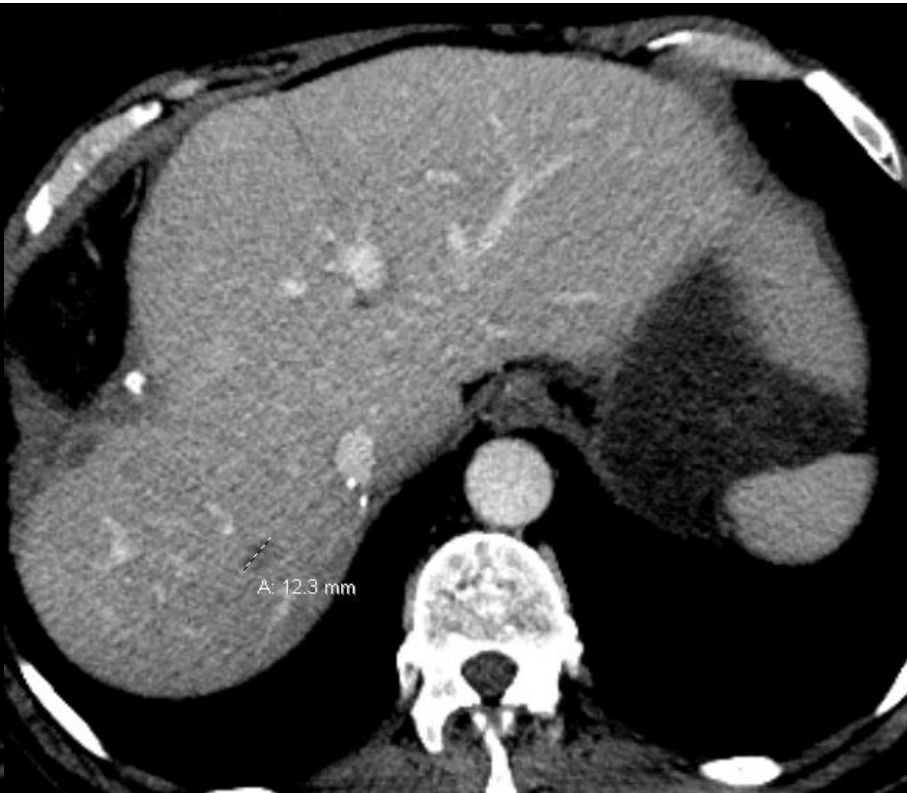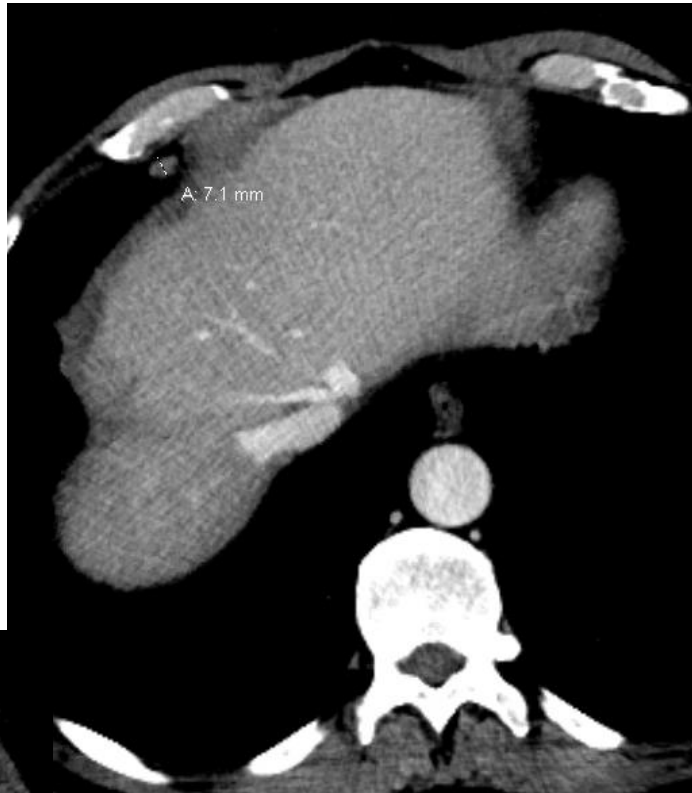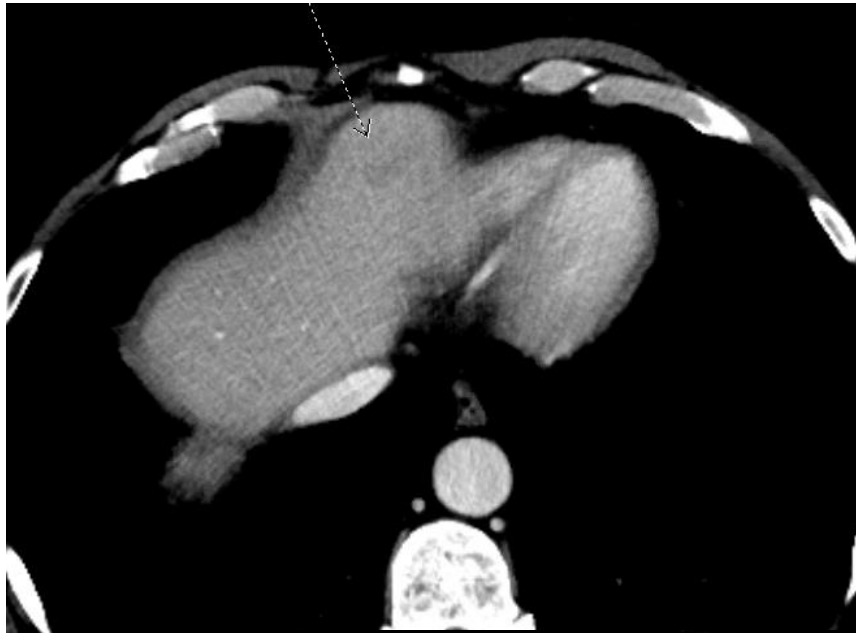
# Mr AFP- at recurrence

- Started lenvatinib 12 mg March 2022.
  - Not immunotherapy given he is potentially a transplant candidate.
  - CT chest, baseline labs
- Voice hoarseness, headaches qWednesday
- Hypothyroid: Rx L-thyroxine but often forgets. TSH:
  - Mar 5.6
  - Apr 14.2
  - May 17.6
  - June 21.4
  - July 20.7
  - Aug 19.4. FT4 9.4. FT3 3.9.
- Weight loss- +++ diet changes

# Surprise ☹️- Summer 2022 ...Long awaited baseline CT chest



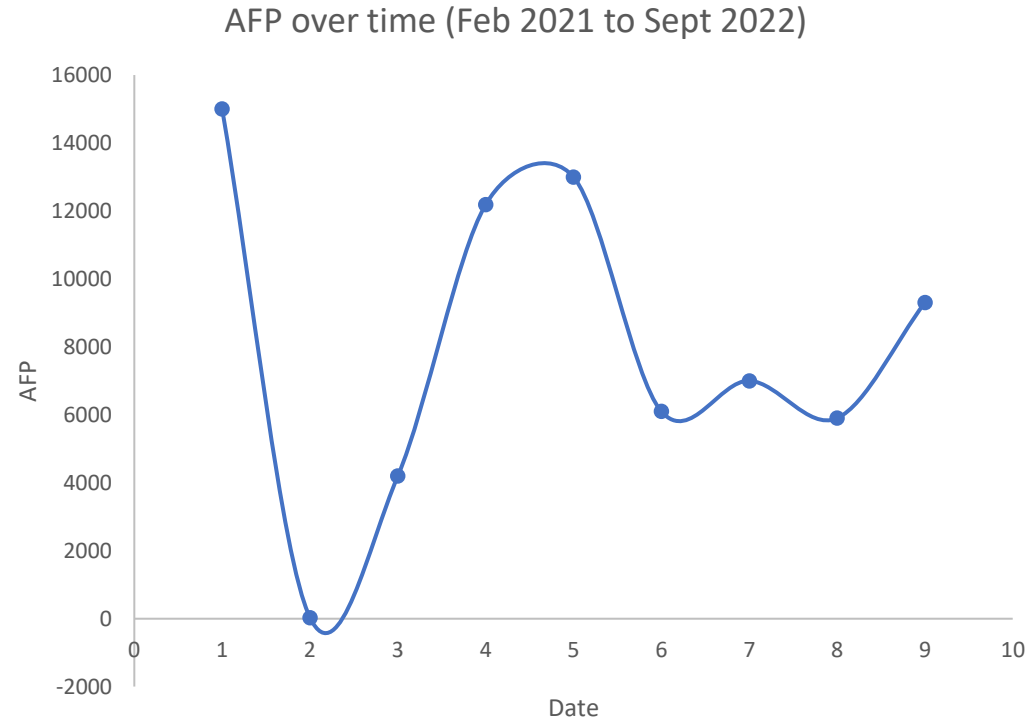
New presumed lung  
metastases



Liver disease stable

# Mr AFP

- No CT chest since Mar 2021
- Liver disease stable.



- Hypothesis: lung nodules present at the time of multifocal liver recurrence and subsequent initiation of Lenvatinib, now stable or shrinking.
  - AFP was previously higher, then dipped to the 6000 and is now 7000, which may represent an increase associated with the development/growth of metastatic disease.
- Plan: short interval re-evaluation.
  - ? Need lung Bx

# Mr AFP

- Short interval CT Sept 2022
  - Pulmonary parenchymal lesions are **slightly** larger:
    - RUL 3.5 x 2.8 cm (prev 3.3 x 2.7 cm).
    - RUL 1.2 x 0.8 cm (prev 1.1 x 0.8 cm).
    - RM: 0.5 and 0.6 cm nodules (previously 0.3 and 0.4 cm respectively)
  - Segment 2: unchanged from November 2021. Indeterminate, LR 3.  
Segment 6: Stable 2.6 x 2.2 cm.  
Segment 7: Stable 1.2 cm hypodensity without enhancement on any sequences.
  - No new liver lesion. The portal vein is patent
- Sept AFP decreasing since starting lenvatinib, from 13000 to 5900.
- Continue Lenvatinib until progression.
- Not taking Synthroid.

# Polling Q- What are 2<sup>nd</sup> line systemic Rx options?

- a) Any other 1<sup>st</sup> line Rx (soraf, atezo/Bev, durva/treme)
- b) Regorafenib
- c) Cabozantinib
- d) Immunotherapy single agent
- e) Options b + c

# Polling Q- What are 2<sup>nd</sup> line systemic Rx options?

- a) Any other 1<sup>st</sup> line Rx (soraf, atezo/Bev, durva/treme)
- b) Regorafenib
- c) Cabozantinib
- d) Immunotherapy single agent
- e) Options b + c



# At time of progression...

- Technically no funding for Immunotherapy.
- Will apply for atezo/bev
  - No longer a transplant candidate so that isn't a contraindication
- Alternative, 2<sup>nd</sup> line regorafenib
- Nov AFP 8900 (rising).

# 2L Systemic Therapy for Unresectable HCC

	Funded <sup>2</sup>	NOT Funded <sup>2</sup>
Health Canada Approved <sup>1</sup>	Regorafenib (RESORCE) <sup>3</sup> Cabozantinib (CELESTIAL) <sup>4</sup>	Nivolumab (CheckMate 040) <sup>5</sup>
NOT Health Canada Approved <sup>1</sup>		Ramucirumab (REACH-2) <sup>6</sup> Pembrolizumab (KEYNOTE-240) <sup>7</sup>

1. Directed search (Sep 16 2020) of: <https://health-products.canada.ca/dpd-bdpp/index-eng.jsp>

2. Directed search (Sep 16 2020) of: <https://www.cadth.ca/pcodr/find-a-review>

3. Bruix J, et al. Lancet 2017;389(10064):56-66. 4. Abou-Alfa GK, et al. N Engl J Med. 2018;379(1):54-63. 5. El-Khoueiry AB, et al. Lancet 2017;389(10088):2492-2502. 6. Zhu AX, et al. Lancet Oncol. 2019;20(2):282-296. 7. Finn RS, et al. J Clin Oncol 2020;38(3):193-202.

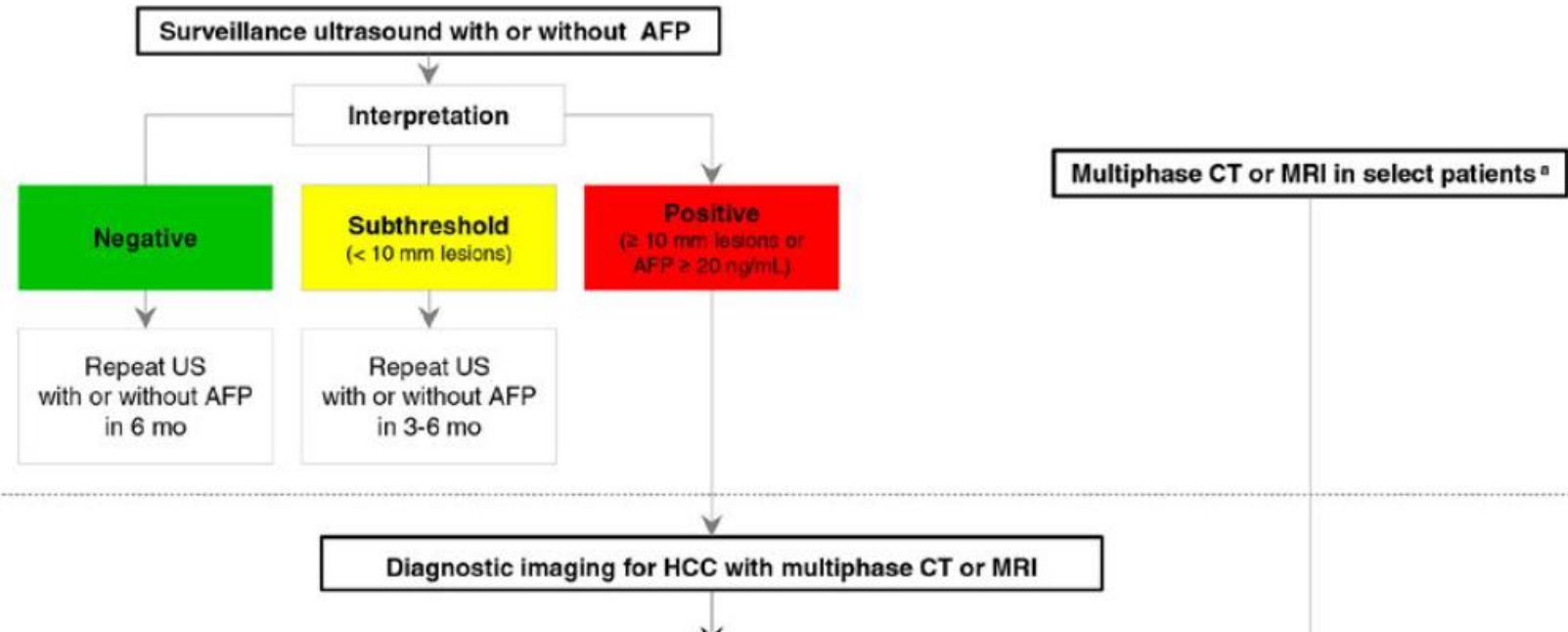
# CASE 2: Mr PC

# Mr PC

- 75 M Dx prostate cancer (2020) and underwent prostate cancer radiation.
- Early 2020 Staging CT showed **2.8 cm dome liver lesion**
- Comorbidities:
  - High risk prostate cancer, Gleason 4 + 4, PSA 59.4, Rx Zoladex started January 2020, completed EBRT pelvis/prostate August 2020.
  - HTN, hyperlipidemia,
  - Hepatic steatosis/NASH
  - Previous Etoh use disorder.
  - Diverticulitis Nov 2021 w/ localized perforation + colovesicular fistula involving sigmoid colon . ABx and anterior resection with takedown of the colovesicular fistula. Complicated by anastamotic leak.
  - Compression # T11

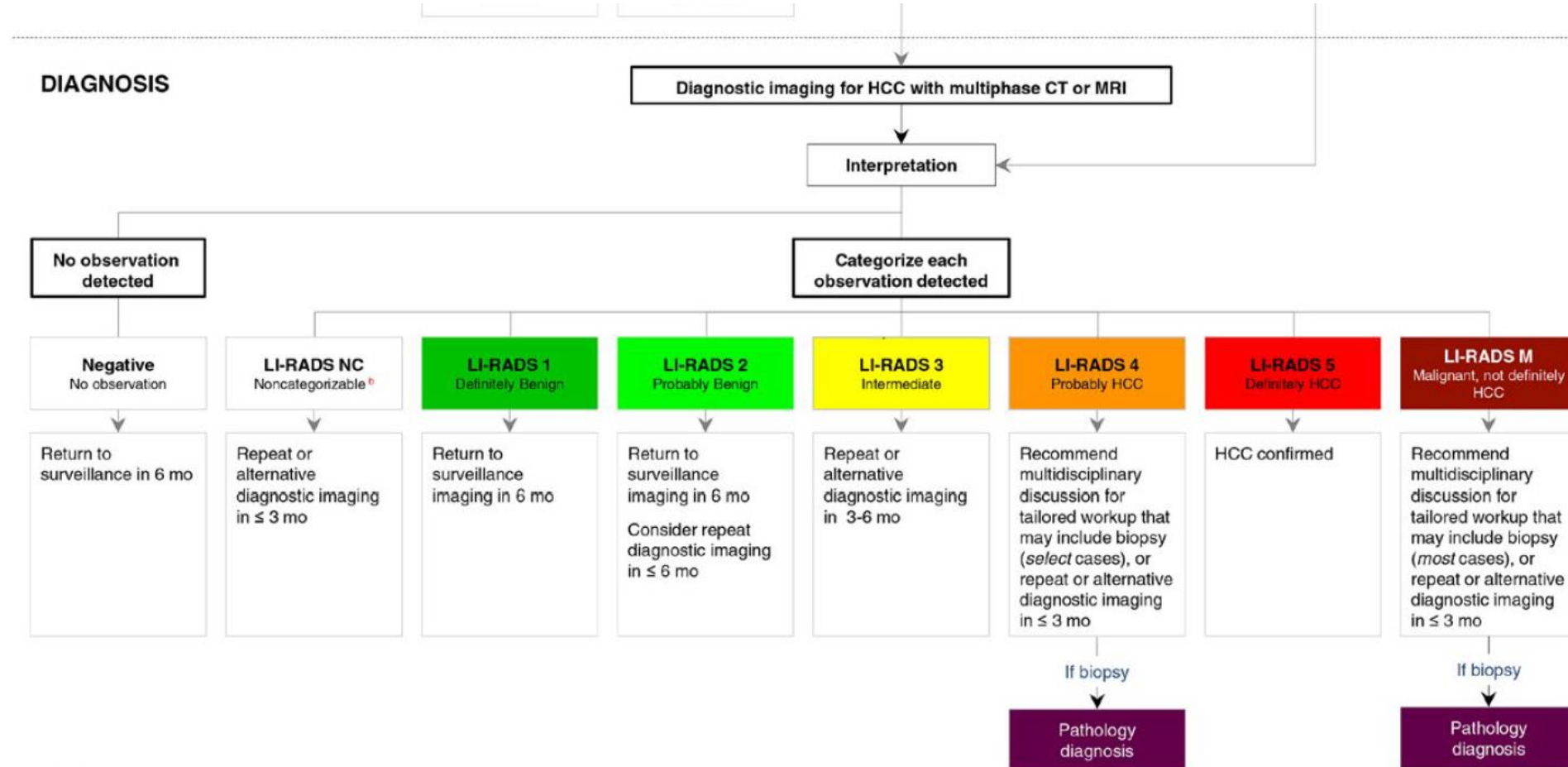
# AASLD Surveillance Algorithm (2018)

## SURVEILLANCE



## DIAGNOSIS

# AASLD Diagnostic Algorithm (2018)



## Footnotes

a. Multiphase CT or MRI in select patients

Some high-risk patients may undergo multiphase CT or MRI for HCC surveillance (depending on patient body habitus, visibility of liver at ultrasound, being on the transplant waiting list and other factors).

b. Noncategorizable

These are due to technical problem such as image omission or severe degradation

# Mr PC

- MRI c/w HCC segment VIII

# Polling Q- What treatment(s) may be possible for a solitary HCC?

- a) TACE
- b) Resection
- c) Ablation
- d) Liver transplant
- e) Systemic therapy
- f) Radiation
- g) TARE
- h) All of the above/situation dependent



# Polling Q- What treatment(s) may be possible for a solitary HCC?

- a) TACE
- b) Resection
- c) Ablation
- d) Liver transplant
- e) Systemic therapy
- f) Radiation
- g) TARE
- h) All of the above/situation dependent

# Treatments for HCC

## **Local**

- surgery
- Ablation (RFA, MWA)
- liver transplant
- TACE

## **Bridging Therapies**

- TACE
- TARE
- Other local (surgery, RFA, SBRT)

## **Palliative**

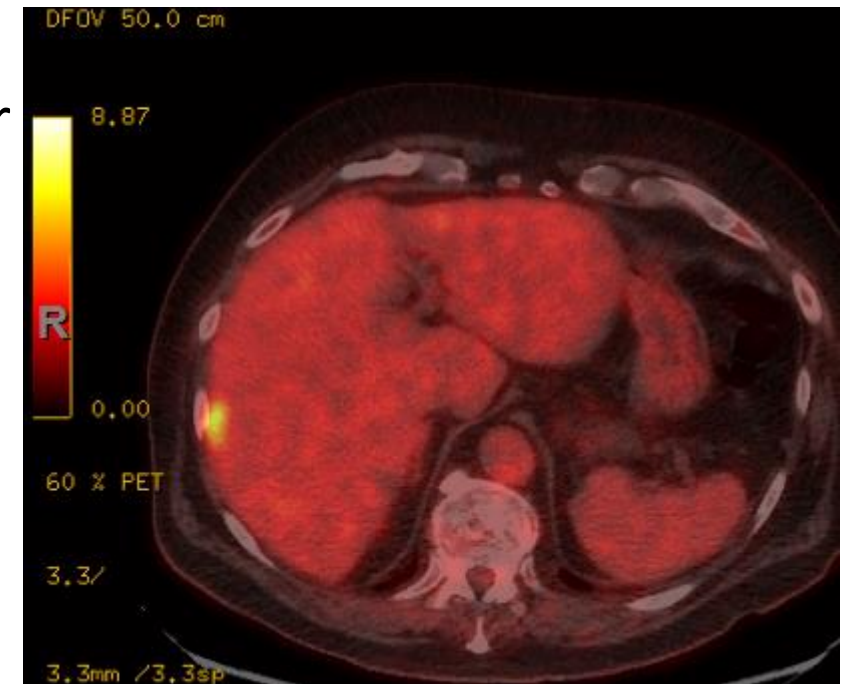
- Systemic therapy: TKI, immunotherapy
- radiation
- supportive care

# Mr PC

- MRI c/w HCC segment VIII
- → **laparoscopic ablation** Oct 2020.
- F/up MRI Dec 2021
  - ablation zone OK (LR-TR non viable)
  - right inferior epigastric nodule (2 x 1.4 cm) adj to seg II has increased in size  
?metastatic disease.

# Mr PC

- 1.5 years later...
- PET- New liver lesion and peritoneal nodule –
  - Small focus at ablation zone (1.1 cm, SUV max 3.7) ?inflammatory or infectious tissue but r/o residual HCC.
  - Seg 7 peripheral lesion- not definitively subcapsular and may represent a true hepatic lesion. 1.4 cm, SUV max 4.8.
  - Right epigastric multilobulated nodule is FDG avid (SUV max 6.0, 2.3x2cm) ?malignant.
- Now what?



# Management of HCC: General Principles

- **Multidisciplinary** team evaluation
- Assess for curative treatment options: resection, transplantation, or RFA
- Evaluate underlying hepatic function and HBV/HCV status
- Understand the indication and institutional expertise for regional therapies: TACE, radioembolization, and radiation, etc.
- Systemic therapy: indication, eligibility, and side effects
- Evaluate for downstaging
- Encourage pts to participate in clinical trials

# Impact of Multidisciplinary Care

- Factors associated with higher likelihood of receiving active HCC Rx:
  - Care at academically affiliated VA hospital (OR 1.97)
  - Multi-specialist evaluation (OR 1.60)
- Factors associated with reduced mortality risk:
  - Specialist care within 30 days of Dx with hepatologists (HR 0.70), oncologists (HR 0.82), or surgeons (HR 0.79)
  - Review by tumour board (HR 0.80)

# Mr PC

- Liver Tumour Rounds- viable disease at ablation margin, capsular implant seg VII, and likely met ant to seg II (peritoneal)- enlarging → LR-TR viable.

→ Recc: Bx LN/nodule.

→ Systemic therapy for peritoneal disease. No role surgery w/ metastatic disease. HPB would see if disease stable.

# Mr PC

- Biopsy peritoneal nodule: recurrence, grade 2 HCC (Mar 2022).
- Child-Pugh A, ECOG 1



# Mr PC

- What about his comorbidities?
  - High risk prostate cancer, Gleason 4 + 4, ADT → RT August 2020. PSA rising.
  - HTN, hyperlipidemia,
  - **Hepatic steatosis/NASH**
  - **“previous” Etoh use disorder** → 10oz spirits/day x >20 years, then abstinent x12 years, now 3 wine/day.
  - diverticulitis Nov 2021 w/ localized perforation + colovesicular fistula involving sigmoid colon . Treated w/ ABx and anterior resection with takedown of the colovesicular fistula. Complicated by anastamotic leak. **Infection resolved.**
- No cardiac disease, PE/DVT, stroke/TIA, seizures, thyroid disease. No inflammatory disease/connective tissue disease. Not on immunosuppressive therapy or steroids. No prior GIB. No HBV or HCV.
- Social Hx- caregiver for wife, looks after rural property + home.

# Polling Q- What are potential 1<sup>st</sup> line systemic therapies for Mr PC?

- a) Sorafenib
- b) Lenvatinib
- c) Atezolizumab/Bevacizumab
- d) All of the above

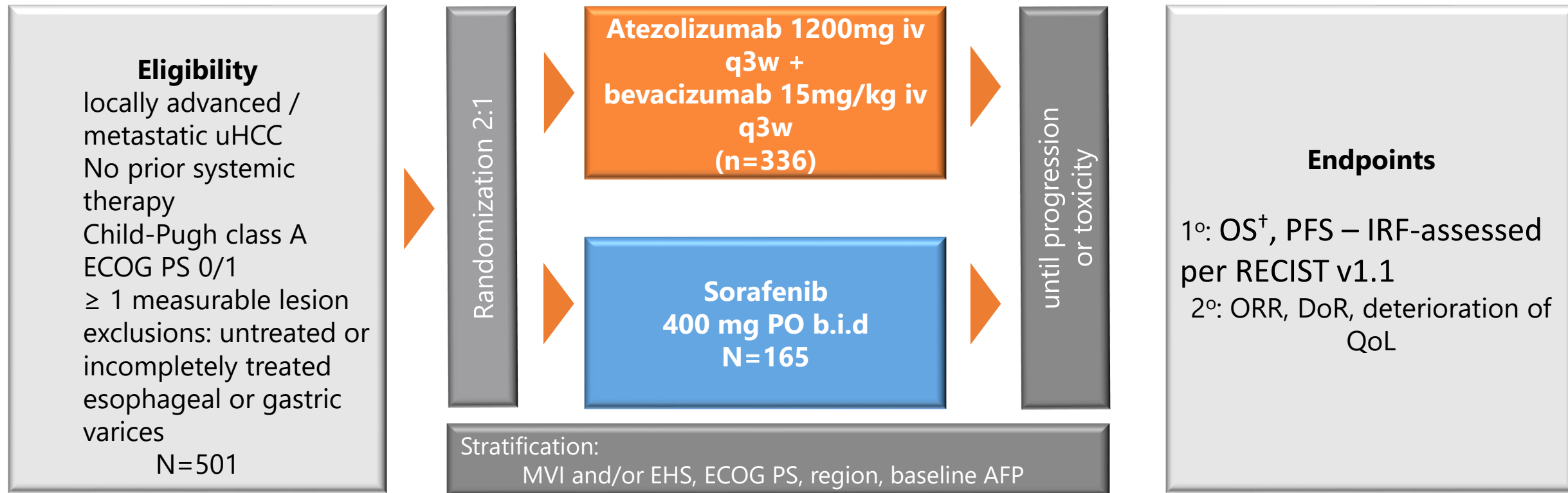
# Polling Q- What are potential 1<sup>st</sup> line systemic therapies for Mr PC?

- a) Sorafenib
- b) Lenvatinib
- c) Atezolizumab/Bevacizumab
- d) All of the above

# IMbrave150: Study Design

Atezolizumab +  
Bevacizumab

IMbrave150:<sup>1</sup> randomized, multicentre, phase III, open-label trial



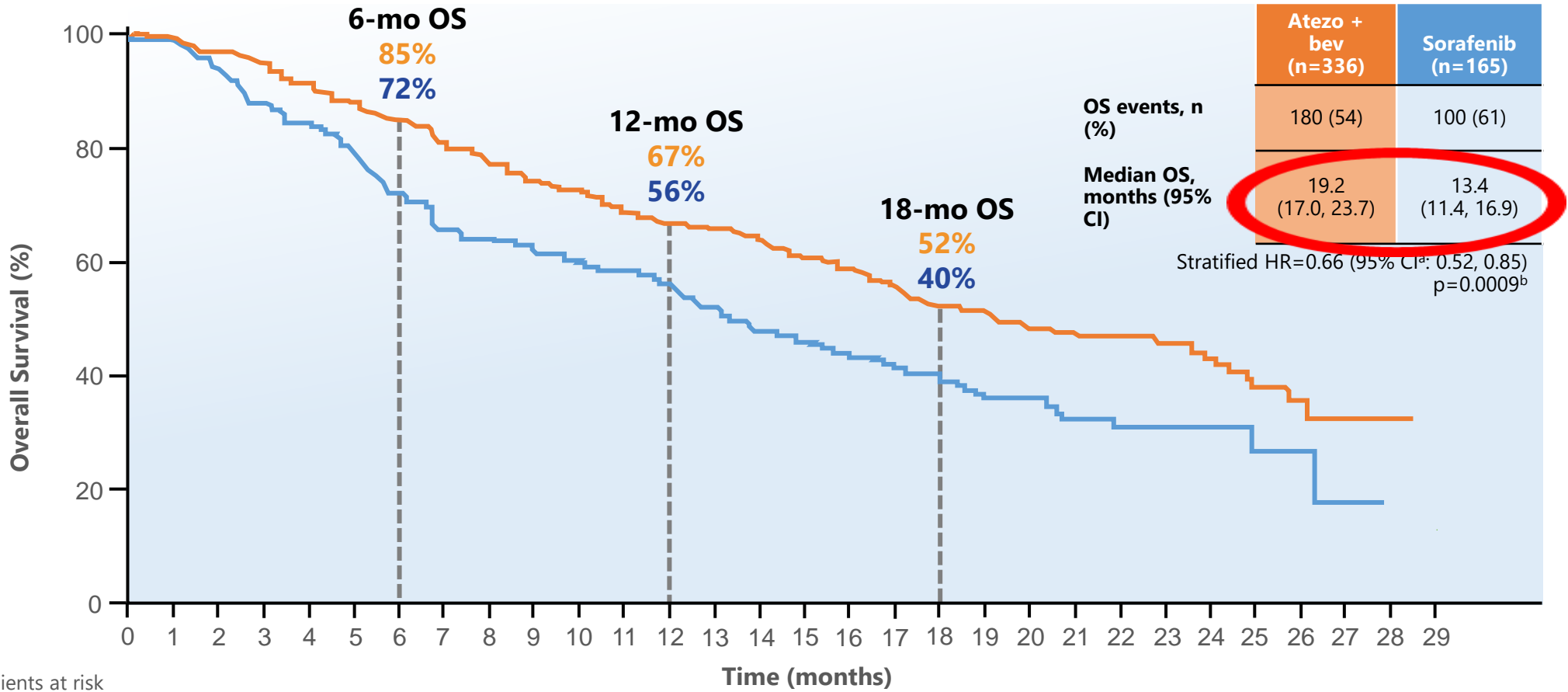
<sup>†</sup>80% power to detect a hazard ratio for overall survival of 0.71 using a logrank test at a twosided 0.048 significance level; two-sided significance for PFS was 0.002

AFP, alpha-fetoprotein; b.i.d, twice a day; ECOG PS, Eastern Cooperative Oncology Group performance status; EHS, extrahepatic spread; HR, hazard ratio; IRF, independent review facility; iv, intravenous; MVI, macroscopic vascular invasion; OS, overall survival; po, orally; q2w, every two weeks; RoW, rest of world; uHCC, unresectable hepatocellular carcinoma; QoL, quality of life.

1. Finn RS, et al. N Engl J Med 2020; 382:1894-1905.

# IMbrave150: OS<sup>1</sup>

**Atezolizumab +  
Bevacizumab**



No. of patients at risk

	0	1	2	3	4	5	6	7	8	9	10	11	12	13	14	15	16	17	18	19	20	21	22	23	24	25	26	27	28	29
Atezo + bev 336	329	32	312	302	28	276	263	25	240	233	22	214	209	20	192	186	17	164	156	13	105	80	57	42	24	12	11	2	NE	
Sorafenib 165	158	0	133	128	8	106	96	2	88	85	1	78	72	2	64	61	5	55	49	4	32	24	18	12	7	3	2	NE	NE	
		14			11			92			81			66			58			44										
		4			9																									

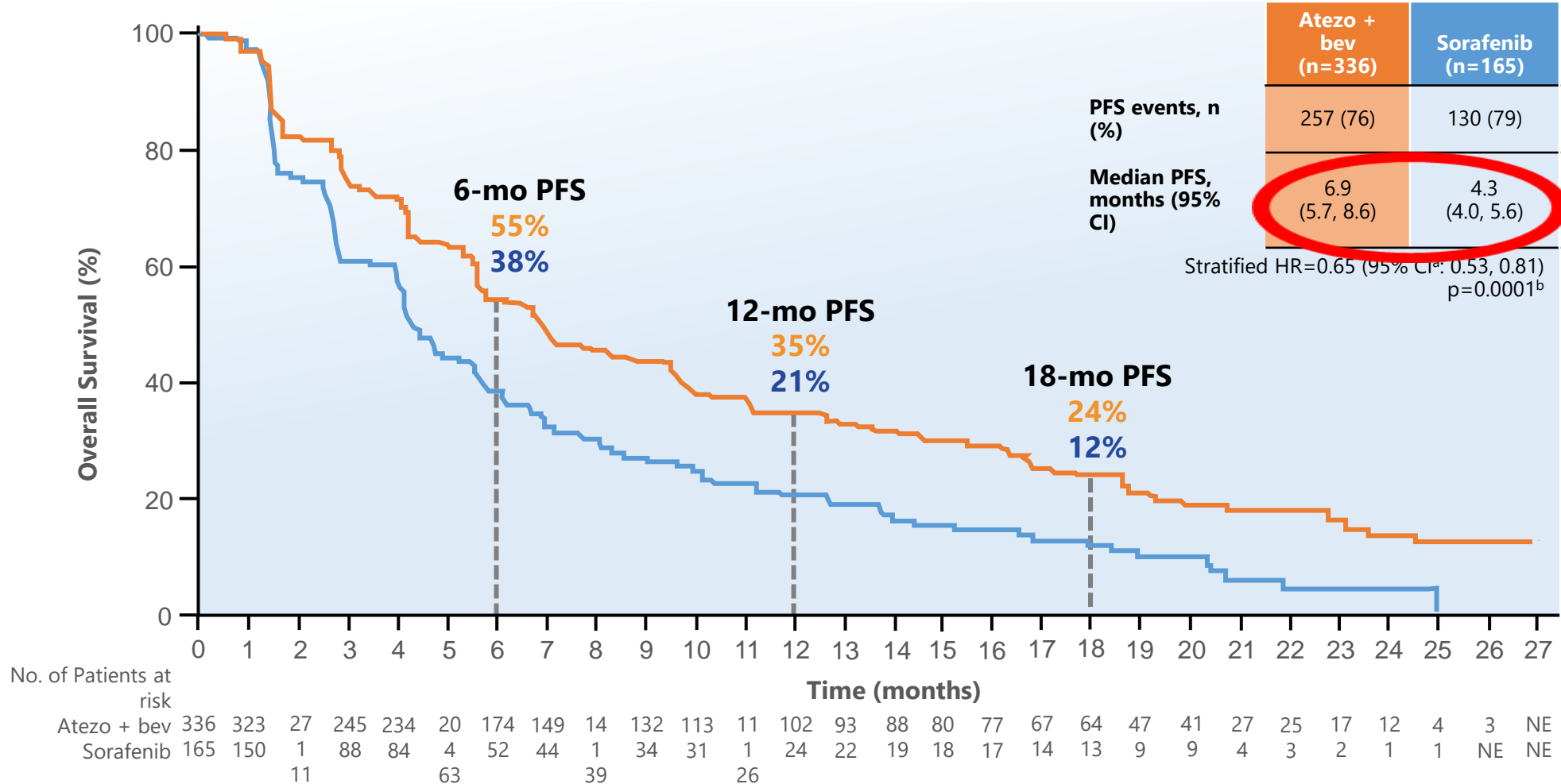
CCOD: August 31, 2020; median follow-up: 15.6 months.

<sup>a</sup> Stratification factors included in the Cox model are geographic region (Asia excluding Japan vs Rest of World), AFP level (<400 ng/mL) at baseline and MVI and/or EHS (Yes vs No) per interactive voice/web response system (IxRS).

<sup>b</sup> P value for descriptive purposes only.

1. IMbrave 150: Updated Overall Survival Data. Presented By Richard Finn at 2021 Gastrointestinal Cancers Symposium #G121

# IMbrave150: PFS<sup>1</sup>



CCOD: August 31, 2020; median follow-up: 15.6 mo.

<sup>a</sup> Stratification factors included in the Cox model are geographic region (Asia including Japan vs Rest of World), AFP level (<400 ng/mL vs ≥ 400 ng/mL) at baseline and MVI and /or EHS (Yes vs No) per interactive voice/web response system (IxRS).

<sup>b</sup> P value for descriptive purposes only.

\*Per IRF-assessed RECIST v1.1

# IMbrave 150: Tumour Response<sup>1</sup>

	RECIST v1.1		HCC mRECIST	
	Atezo + bev (n=326)	Sorafenib (n=159)	Atezo + bev (n=325)	Sorafenib (n=158)
Confirmed ORR, (95% CI)	<b>30</b> <b>(25, 35)</b>	<b>11</b> <b>(7, 17)</b>	<b>35</b> <b>(30, 41)</b>	<b>14</b> <b>(9, 20)</b>
CR, n (%)	25 (8)	1 (< 1)	39 (12)	4 (3)
PR, n (%)	72 (22)	17 (11)	76 (23)	18 (11)
SD, n (%)	144 (44)	69 (43)	121 (37)	65 (41)
DCR, n (%)	241 (74)	87 (55)	236 (73)	87 (55)
PD, n (%)	63 (19)	40 (25)	65 (20)	40 (25)
Ongoing response, n (%)	54 (56)	5 (28)	58 (50)	6 (27)
<b>Median DOR (95% CI), mo<sup>b</sup></b>	<b>18.1</b> <b>(14.6, NE)</b>	<b>14.9</b> <b>(4.9, 17.0)</b>	<b>16.3</b> <b>(13.1, 21.4)</b>	<b>12.6</b> <b>(6.1, 17.7)</b>

Clinical cutoff: August 31, 2020; median follow-up: 15.6 mo, DCR, disease control rate; DOR, duration of response; mRECIST, modified Response Evaluation Criteria In Solid Tumors

<sup>a</sup> Only patients with measurable disease at baseline were included in the analysis of ORR.

<sup>b</sup> Only confirmed responders were included in the analysis of ORR.

1. IMbrave 150: Updated Overall Survival Data. Presented By Richard Finn at 2021 Gastrointestinal Cancers Symposium #G121

# Polling Q: What are contraindications to atezolizumab/bevacizumab?

- a) Recent bleed, prior variceal bleed, or risk of
- b) Recent stroke or MI
- c) Uncontrolled HTN
- d) Untreated HBV
- e) Autoimmune disorder
- f) Transplant
- g) Requires ongoing steroids
- h) All of the above



# Polling Q: What are contraindications to atezolizumab/bevacizumab?

- a) Recent bleed, prior variceal bleed, or risk of
- b) Recent stroke or MI
- c) Uncontrolled HTN
- d) Untreated HBV
- e) Autoimmune disorder
- f) Transplant
- g) Requires ongoing steroids
- h) All of the above

**Table 3. Requirements specific to first-line agents considered as inclusion or exclusion criteria in pivotal clinical trials.**

Atezolizumab + bevacizumab	Lenvatinib or sorafenib
<b>Requirements regarding concomitant medications</b>	
Patients with HBV infection should be under antiviral therapy with a viral load <500 IU/ml	
Patients should not be in need of full-dose anticoagulants or anti-aggregants (prophylactic doses are allowed).	Patients should not be in need of anticoagulants, except low molecular weight heparin
Treatment with strong CYP3A4 inducers or chronic daily treatment with a NSAID should be avoided.	
<b>Contraindications based on current or prior acute events or chronic conditions</b>	
Thrombocytopenia with platelets <75 × 10 <sup>9</sup> /L	Thrombocytopenia with platelets <75 × 10 <sup>9</sup> /L
Severe chronic hepatitis with AST, ALT >5 × ULN	Severe chronic hepatitis with AST, ALT >5 × ULN
Renal insufficiency (creatinine clearance <50 ml/min)	Renal insufficiency (creatinine clearance <40 ml/min)
Proteinuria ≥1 g/24 h	Proteinuria ≥1 g/24 h
Untreated or incompletely treated gastric or oesophageal varices with high-risk for bleeding (assessed by esophagogastroduodenoscopy within the last 6 months)	Gastric or oesophageal varices that require treatment
Current or past autoimmune diseases, with the following exceptions: hypothyroidism, type 1 diabetes, skin diseases with limited involvement.	
Any condition that requires chronic systemic immunosuppression.	
Inhaled or topical steroids and adrenal replacement doses <10 mg/day prednisone equivalents are usually permitted.	
Inadequately controlled blood pressure	Inadequately controlled blood pressure or the need of >1 antihypertensive medication
Prior history of hypertensive crisis or hypertensive encephalopathy.	Chronic heart failure of NYHA class >II, unstable angina, myocardial infarction or stroke within 6 months
Chronic heart failure of NYHA class >I, myocardial infarction, or stroke within 3 months.	Arrhythmia requiring medical treatment
Unstable angina.	QTc >480 ms
Unstable arrhythmia	
Significant vascular disease (including recent peripheral arterial thrombosis) within 6 months	
Bleeding diathesis or significant coagulopathy	Bleeding or thrombotic disorders
Recent GI bleeding or haemoptysis	Recent GI bleeding or haemoptysis
Serious, non-healing or dehiscent wound, active ulcer, or untreated bone fracture	
<b>Populations with unknown benefit</b>	
HBV-HCV coinfection	HIV infection
HIV infection	ECOG performance status >1
ECOG performance status >1	Liver transplantation
Liver transplantation	Child-Pugh class B or C
Child-Pugh class B or C	
Current moderate to severe ascites or any history of hepatic encephalopathy	HCC with ≥ 50% liver occupation, invasion into the bile duct, or invasion of the main portal branch (only for lenvatinib)
Fibrolamellar HCC, sarcomatoid HCC, or mixed cholangiocarcinoma and HCC	
Brain or leptomeningeal metastasis	Brain or leptomeningeal metastasis

Contraindications to Atezo/bev Or Len or Sorafenib

# Mr PC

- EGD- no varices, controlled HTN, infection resolved.
- Initiated atezolizumab and bevacizumab in June 2022.
- BP has increased on therapy- meds were increased as BPs are 140-160 systolic.
- Scalp rash since initiation and more oily. Managed.
- Muscle and joint aches.

Uses Tylenol, sparingly ibuprofen  
(although works well).

# MR PC

- CT 2 months post initiation
  - mild FURTHER ENLARGEMENT involving the extrahepatic nodule
    - PET CT from February 2022 was 1.8 → 2.2 cm
  - ablation zone remains clear.
- Plan: continue atezo/bev.  
Repeat CT in 3 mo +q3 mo thereafter.

# At time of progression...

- If stable longer term, HPB review (low volume disease).
- 2<sup>nd</sup> line Lenvatinib or sorafenib.

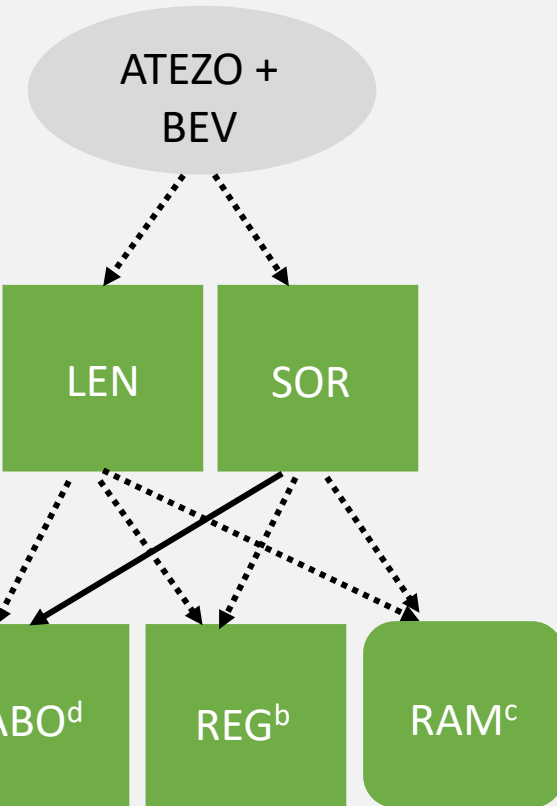
# Optimizing Survival and the Changing Landscape of Targeted Therapy for Intermediate and Advanced Hepatocellular Carcinoma: A Systematic Review

Howard Lim, MD, PhD, FRCPC,<sup>1\*</sup> Ravi Ramjeesingh, MD, PhD, FRCPC,<sup>2</sup> Dave Liu, MD, FRCPC, FSIR,<sup>3</sup> Vincent C. Tam, MD, FRCPC,<sup>4</sup> Jennifer J. Knox, MD, MSc, FRCPC,<sup>5</sup> Paul B. Card, PhD,<sup>6</sup> Brandon M. Meyers, MD, MSc, FRCPC<sup>7</sup>

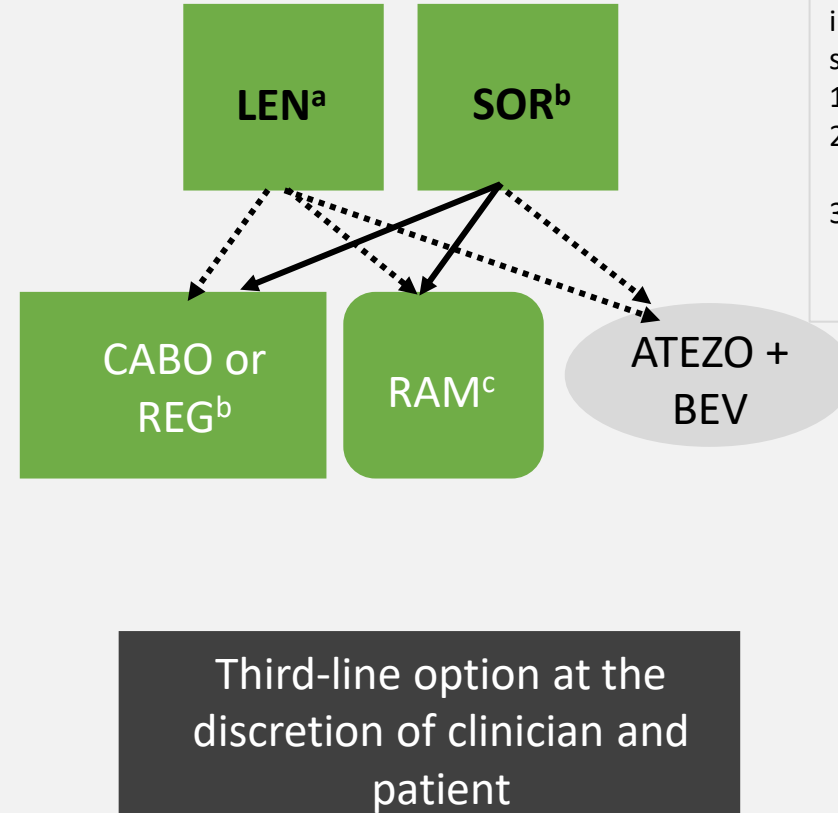
## Treatment sequencing

**For intermediate or advanced HCC patients ineligible for LRT with ECOG PS  $\leq$  1 and Child-Pugh A**

### Preferred Sequence



### Alternate Sequence



### Sequencing principles

- Targeted therapy selections in intermediate or advanced HCC should:
- 1) Optimize survival or HRQoL
  - 2) Consider clinical trial eligibility
  - 3) Allow for exposure to all 3 active classes of agents, TKI, ICI, and V-MoAb

### Legend

ICI + V-MoAb

TKI

V-MoAb

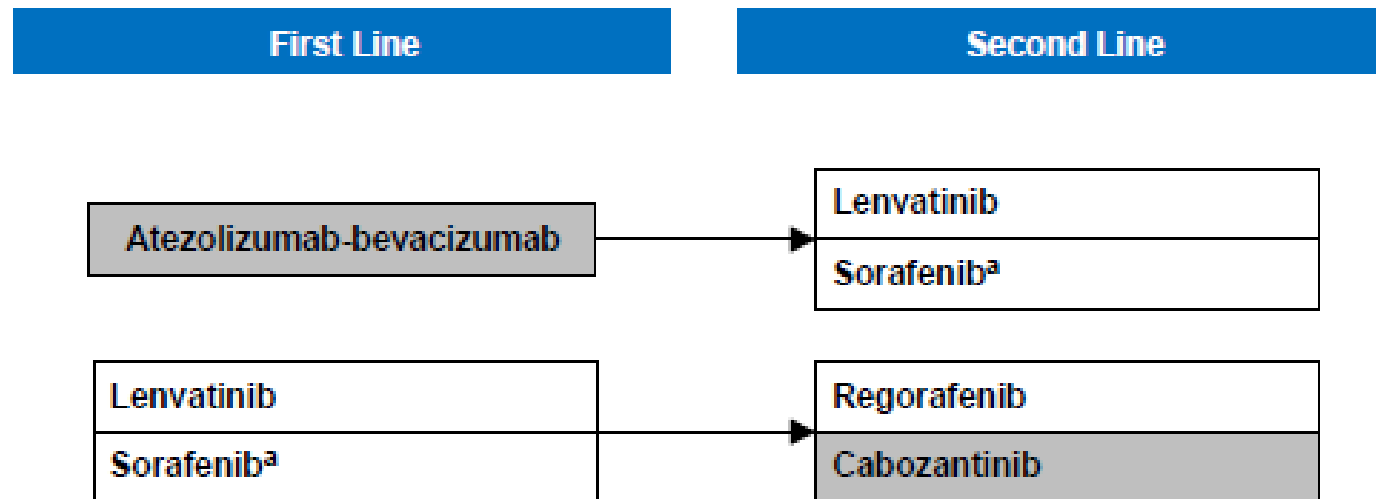
Based on phase III data

Not based on phase III data

# CADTH Algorithm

## Objective

CADTH provisional algorithm for unresectable HCC provided guidance to jurisdictions considering funding of atezolizumab in combination with bevacizumab and the implications to sequencing



<sup>a</sup> Only if intolerant of lenvatinib.

## Legend

Therapy funded across most jurisdictions	Therapy under review for funding (pCPA or province/cancer agency)
--	---

# Questions?

[Janine.davies@bccancer.bc.ca](mailto:Janine.davies@bccancer.bc.ca)



Provincial Health Services Authority