

BC Cancer Colon Screening Program Pathology Standards

Date and Version: September 2022

P

Pathology Standards

Colon Screening Program

This report was produced by the BC Cancer Colon Screening Program.

Preferred citation:

Colon Screening Program Pathology Standards. BC Cancer, 2022.

For more information please contact:

Colon Screening Program

801-686 West Broadway

Vancouver, BC

V5Z 1G5

Web: www.screeningbc.ca/colon

Email: screening@bccancer.bc.ca

Phone: 1-877-70-COLON (26566)

Fax: 1-604-877-6103

Acknowledgements

BC Cancer would like to thank everyone who assisted in the development and refinement of the Colon Screening Program's Pathology Standards.

Author

Dr. David Schaeffer, BC Cancer Colon Screening Program Pathology Lead

Contributors

Dr. Jerry Chen, Pathology Lead Fraser Health Authority

Dr. Katherine Tsang, Pathology Lead Northern Health Authority

Dr. Xiong Wei, Pathology Lead Vancouver Coastal Health Authority

Dr. Cheryl Wright, Pathology Lead Island Health

Dr. Bibi Naghibi Torbati, Pathology Lead Interior Health

Laura Gentile, BC Cancer Agency

About BC Cancer

BC Cancer provides a comprehensive cancer control program for the people of BC in partnership with regional health authorities. This includes prevention, screening and early detection programs, research and education, and care and treatment.

BC Cancer's mandate is a three-fold mission:

- To reduce the incidence of cancer
- To reduce the mortality rate of people with cancer
- To improve the quality of life of people living with cancer

This mission drives everything we do, including providing screening, diagnosis and care, setting treatment standards, and conducting research into causes of, and cures for, cancer.

Table of Contents

Introduction	1.1	Colon Screening Program	6
	1.2	Purpose of the Standards	6
	1.3	Sources of Information	6
	1.4	General Principles	7
Protocol for Handling Pathology Specimens	2.1	Clinical Information	8
Gross Description and Dissection	3.0	Gross Description and Dissection	9
Technical Procedures	4.0	Technical Procedures	10
Diagnosis and Reporting	5.1	Location	11
	5.2	Specimen Type	11
	5.3	Histologic Classification	11
	5.4	Degree of Dysplasia	17
	5.5	Completeness of Removal	17
Required Reporting for Colorectal Polyps	6.1	Reporting of Colorectal Specimens	18
	6.2	Carcinoma Within Polyp	19
	6.3	Medical Record Retention	22
Pathology Review	7.1	Pathology Review Based on Health Authority	23
	7.2	Pathology Review Based on Colon Screening Program	23
Appendix	A	Colonoscopy Reporting Form	24
	B	Protocol for Handling a Polyp Specimen	25
	C	Sample Pathology Report	27
Log Revision History			28

1. Introduction

1.1 Colon Screening Program

Colorectal cancer (CRC) is the third most common cancer in Canada in both women and men.

The primary goals of the Colon Screening Program are to detect and remove precancerous colorectal lesions to reduce the incidence of CRC and to detect asymptomatic CRC at an early clinical stage to decrease CRC mortality.

Pathologists who report colorectal polyps/lesions detected by colonoscopy in patients from a colon screening program provide not only the pathologic diagnosis but also key information for patient surveillance and management decisions. Standardized identification and classification of colon polyps as well as other precursor lesions of CRC is essential. Similarly, the standardized handling and reporting of colectomies for invasive cancer is equally important. By continuing a stringent province-wide uniform specimen handling and reporting protocol, information needed for a multi-site screening program will be provided. The protocols outlined below will permit information gathering and comparisons of results across Canada and internationally.

1.2 Purpose of the Standards

The purpose for developing a pathology reporting guideline for colorectal screening program is to:

- Eliminate variability in diagnosis and nomenclature of colonic precancerous lesions
- Include relevant information needed for patient surveillance
- Include key information for patient management if a malignant lesion is diagnosed

1.3 Sources of Information

This protocol is developed based on the current pathology literature identified from:

- Medline
- National Colorectal Screening Program Quality Determinants Workshop, Vancouver, BC, May 22-23, 2008.
- Quality Determinant Framework for Colorectal Screening in Canada, Toronto, April 2009.
- Pathological reporting of colorectal polyps. Pan-Canadian consensus guidelines. *Can J Pathol* 2012;4:81-90.
- WHO Classification of Tumours Editorial Board. Digestive system tumours. Lyon (France): International Agency for Research on Cancer; 2019. (WHO classification of tumours series, 5th ed.; vol.1).
- Canadian Cancer statistics 2022.
- BCGuidelines.ca

1.4 General Principles

Quality assurance is an essential component of a population-based screening program, and measurements of quality should be applied to all participating laboratories. Uniform provincial standards provide the opportunity to monitor system performance and patient outcomes in a way that supports comparison and learning across jurisdictions.

Consistency in reporting will help to ensure meaningful systems performance and patient outcomes monitoring, and will assist physicians in determining appropriate recall intervals for screening patients.

A centralized consultation service is available for individual pathologists to refer complex and difficult cases prior to final diagnosis.

Quality assurance is a process of education, consultation and collegiality that will optimize patient outcomes.

Laboratory Standards

All participating laboratories must be accredited by the Diagnostic Accreditation Program (DAP) of the College of Physician and Surgeons of BC. Laboratories must comply with reporting standards as outlined in this document.

All pathology reports originating from screening patients will be submitted to a central registry that can be assessed by individual(s) charged with the responsibility for implementing province-wide pathology performance indicators. Selected pathology slides and reports will be made available for forwarding to individuals charged with the responsibility for implementing Pathology Performance Indicators.

Participating Pathologist Standards

It is anticipated that all pathologists participating in the Colon Screening Program will already have experience in the diagnosis of colonic neoplasms. Pathologists are expected to read these Pathology Standards and to familiarize themselves with uniform diagnostic terminology.

Annual Pathology Report cards are distributed to allow for self-assessment and comparison to the rest of the program.

2. Protocol for Handling Pathology Specimens

Colonoscopists will use the Colonoscopy Reporting Form (Appendix A) when documenting the colonoscopy procedure. The Colonoscopy Reporting Form functions as the pathology requisition form. This will provide detailed information to the pathologist regarding each specimen that was removed: size, location, method of removal and whether the specimen was retrieved. The Colonoscopy Reporting Form will also identify patients who are participating in the program to ensure the following pathology reporting is completed for program participants.

The full protocol for handling specimens is outlined in Appendix B.

2.1 Clinical Information

Patient identification required, is similar to any other pathology specimen. This must include the patient's full name, sex, date of birth, personal health number (PHN), name of submitting physician and name of family physician.

In addition, other relevant information must include the location within the colon and the size of the precancerous lesion. A clinical note describing the clinical impression of the completeness of removal is desirable. A Colonoscopy Reporting Form which includes this information can be copied and used as a pathology requisition. It is not necessary to fill out a separate, designated pathology requisition.

Multiple precancerous lesions should not be placed in a single container. They must be submitted separately and identified as to site. The container should contain adequate (ideally, 10 times the volume of the specimen) 10% formalin to ensure appropriate fixation. Each container should have an outside label identifying patient name, date of birth and location of the lesion. Once the specimen is placed in formalin, there is no need to transmit it to the laboratory in an urgent fashion. Nevertheless, reducing the time a specimen is in transit will speed up the delivery of the pathology report. Refrigeration is not required and specimens should not be frozen.

3. Gross Description and Dissection

The specimen should be examined and dissected by a pathologist or a suitably qualified delegate. An anatomical pathology technologist with training and experience in processing pathology specimens is qualified to process the biopsy or precancerous lesional specimen. Processing of large polyps or complex resection specimens may be done by a pathologist, pathology resident or pathologists' assistant.

In addition to recording any clinical information, the number, size and gross appearance of the biopsies or precancerous lesions should be described. It is of particular importance to note the configuration of a polyp (polypoid or villous) and the presence of a stalk (measure its length and diameter). If the polyp is small or consists of small fragments (< 3-5 mm), it can be submitted in toto without further dissection. If the polyp is larger than 5 mm and smaller than 10 mm, it can be bisected perpendicular to the biopsy margin or base of stalk. Polyps that are larger than or equal to 10 mm and have a stalk should be cut longitudinally in 3 mm sections leaving the central section containing an intact stalk. Before dissection of any precancerous lesion, the biopsy margin at the base of the stalk should be inked. The whole of a small polyp or each section of a larger polyp should be placed separately in a unique cassette for embedding.

4. Technical Procedures

Following description and dissection, the specimen should be processed, embedded and sectioned in the usual manner. Sections that are 6 microns or less in thickness are suggested. A minimum of two levels should be obtained with the deepest level approximating to the mid portion of the tissue block. Note that serial sections from the superficial surface of the block are not considered to be equivalent to levels. Obviously, precancerous lesions that present diagnostic difficulty may require deeper or serial sections. All polypectomy specimens showing no abnormality on the initial levels should get deeper levels if the findings would be clinically relevant. Routine hematoxylin and eosin staining procedures that are used in the laboratory will suffice.

5. Diagnosis and Reporting

The format of the report should be completed in a consistent way, using standardized terminology. Examples of standardized reports are available in Appendix C. The report should include, in order, the following five key diagnostic features:

- Location
- Type of specimen (polypectomy or biopsy)
- Histologic classification (see descriptions in Section 5.2)
- Degree of dysplasia (when any adenoma or sessile serrated lesion is diagnosed)
- Completeness of removal (when appropriate)

Using standardized terminology does not preclude the pathologist from adding any other type of description in the free text. Rarely, added free text is desirable to clarify or expand on the standardized terminology that is required for the histologic classification.

5.1 Location

This information will have to be obtained from the requisition provided by the referring physician. The following sites within the colon may be identified: cecum, ascending colon, transverse colon, descending colon, sigmoid colon and rectum.

5.2 Specimen Type

Specimens are either biopsies or polypectomies as reported by the colonoscopist.

The risk of a precancerous lesion becoming malignant is greatest for ‘high risk’ lesions (also known as advanced adenomas), which are defined as having any of the following:

- a) adenomas with villous features
- b) adenomas with high grade dysplasia
- c) adenomas in size ≥ 10 mm (as measured by the colonoscopist at the time of excision)
- d) sessile serrated lesions (SSLs) with cytologic dysplasia
- e) traditional serrated adenomas (TSAs)
- f) hyperplastic polyps ≥ 10 mm (as measured by the colonoscopist at the time of excision)

Since microscopic size measurements often differ following formalin fixation size measurement for the purpose of recall of patients is at the discretion of the attending endoscopist.

5.3 Histologic Classification

The histologic classification must be selected from one of the possible diagnoses provided in the list below. If the precancerous lesion type does not appear on this list, the specimen must be classified as “other”. Further explanation about the histologic classification and explanation of the “other” diagnosis can be described in the free text comment section of the report.

Colonoscopists may occasionally submit precancerous lesions that histologically consist of entirely normal large bowel mucosa. These biopsies should be diagnosed as “normal mucosa” although a comment may be added to the free text portion of the report indicating that they may represent a prominent mucosal fold.

From time to time, precancerous lesions will be encountered where the diagnosis is problematic. These may be submitted to a reference centre(s) for consultation.

A. Adenoma

- Tubular adenoma (can contain up to 25% of villous component)
- Tubulovillous adenoma (contains 25-75% villous component)
- Villous adenoma (contains > 75 % villous component)
- Flat adenoma (variant of tubular adenoma)
- Sessile serrated lesion
- Traditional serrated adenoma
- Mixed hyperplastic-adenomatous polyps
- Adenoma with misplaced epithelium/torsion effect

B. Other benign polyps

- Hyperplastic polyp
- Juvenile polyp
- Peutz-Jeghers polyp
- Polypoid mucosal prolapse
- Inflammatory polyp
- Lymphoid polyp
- Mesenchymal polyp (includes lipoma, leiomyoma etc.)
- Other polyps

C. Malignant and potentially malignant polyps

- Carcinoma within polyp (“malignant polyp”)
- Invasive carcinoma
- Neuroendocrine tumour

Hyperplastic Polyps

Hyperplastic polyps are typically small and measure less than 5 mm in diameter. They are most common in the distal colon. The colonic crypts are elongated and contain reduced numbers of goblet cells with excess columnar absorptive cells. A variable degree of proliferation may be seen at the crypt base, but the cells are regular with no cytologic dysplasia. The superficial portion of the crypts shows a serrated appearance. The architecture at the base of the crypts is U-shaped.

Polyps that superficially resemble hyperplastic polyps but are greater than 5 mm in diameter and present in the proximal colon may be sessile serrated lesion (SSL) (see Section 2.2.9 below).

The Colon Screening Program does not require that hyperplastic polyps be subtyped into microvesicular, goblet cell rich or mucin poor subtypes. However, this information may be added to the free text portion of the report.

High Risk Polyps

Histologically high risk precancerous lesions or advanced adenomata are polyps with: a) villous features, b) high grade dysplasia, c) size ≥ 10 mm as measured by the colonoscopist at the time of excision, e) sessile serrated lesions ≥ 10 mm in diameter, e) sessile serrated lesions with cytologic dysplasia, and f) traditional serrated adenoma. Patients with five or more low risk adenomas/sessile serrated lesions are also considered as “high risk”.

High risk polyps require surveillance colonoscopy at a shorter interval.

Adenoma

By definition all colonic adenomas (with the exception of sessile serrated lesions) consist of dysplastic epithelium and are classified as benign neoplasms. Depending on the extent of the villous component, an adenoma may fall into one of three subtypes: tubular, villous or tubulovillous.

A villous component of less than 25% is acceptable within in tubular adenomas. Exactly what constitutes a villus is difficult to define. Three forms are recognized: classical villi, palmate villi and foreshortened villi.

- Classical villi are composed of slender up-growths of epithelium on a thin non-branching stromal core. Typically they have parallel sides. When sampled as a complete longitudinal section their base extends down to the muscularis mucosae. The tip may be pointed or bulbous.
- Palmate villi resemble the morphology of a palm tree. They are composed of broader branching leaf-like structures. Tubular glands may be present at the base and even within the stromal core.
- Foreshortened villi are slender non-branching extensions that protrude from the surface of an otherwise typical tubular adenoma.

Flat or depressed adenomas are rare. As the name suggests, they are not really polypoid in configuration but are disc-shaped. They are typically about 10 mm in diameter. Histologically, they are a tubular adenoma variant (Soetikno R, Friedland S, Caltenbach T, et al. *Gastroenterology* 2006;130:566-576).

Correctly identifying flat adenomata is desirable but not critical for screening patients as this does not influence patient follow up protocols. Small adenomas containing only a few dysplastic crypts or fragmented small adenoma are sometimes difficult to classify into one of the three morphologic subtypes.

In the past, some pathologists have classified these as “adenomatous polyp”. For the purpose of Colon Screening Program data management, it is necessary to classify these “adenomatous polyps” into one of the three adenoma subtypes. If the dysplastic focus just consists of tubules, it should be diagnosed as tubular adenoma. If the dysplastic epithelium contains villous component greater than 25%, then it should be classified as tubulovillous adenoma. Adenomas with villous features are considered high risk and have a shorter surveillance interval.

Adenoma with Misplaced Epithelium

Epithelial misplacement, previously termed ‘pseudoinvasion’, is relatively common in larger adenoma particularly those that have a long stalk and those present in the sigmoid colon. Misplacement is usually considered to be secondary to polyp torsion and ulceration with re-growth of epithelium below the level of the muscularis mucosae. On occasion this may be confused with early invasive adenocarcinoma. The terminology of ‘pseudoinvasion’ should be avoided given the possibility of confusion with ‘invasion’.

Histologic features that may help in distinguishing misplaced epithelium from carcinoma include:

- the presence of lamina propria surrounding the misplaced crypts,
- a degree of dysplasia in the misplaced crypts that is similar to the dysplasia in adjacent non-displaced crypts,
- hemosiderin in the polyp stroma,
- mucin pools in the stroma that may be associated with surviving attenuated epithelial elements.

In cases of diagnostic difficulty, the slides may be referred to a reference centre for consultation.

Traditional Serrated Adenoma (TSA)

Traditional serrated adenomas are polyps with a serrated architecture but with crypts lined by cells with dysplastic nuclei. They are therefore an adenoma variant, not a hyperplastic polyp variant. Generally this type of polyp demonstrates only low-grade dysplasia. Nevertheless, the degree of dysplasia present should be recorded. Previously, these polyps had several other names: serrated adenoma; sessile serrated adenoma with dysplasia and tubular adenoma with overt serrated features. The terminology “traditional serrated adenoma” is now preferred.

Sessile Serrated Lesion (SSL)

Up to 30% of all colorectal carcinomas arise via the serrated neoplasia pathway and both TSA and SSL are known precursor lesions. There is now strong evidence that microvesicular hyperplastic polyps (MVHP) give rise to SSL, but there remains no necessity within the Colon Screening Program to subtype

hyperplastic polyps. The progression from SSL to serrated colonic neoplasia usually follows the development of epithelial dysplasia.

The distinction of SSL from HP is challenging at times. Superficially, they resemble hyperplastic polyps but may be distinguished from them by their architectural abnormalities. These consist of irregular crypts, dilated crypts and serrated crypts present in the bottom half of the mucosa. The proliferative zone at the base of the crypts may extend half way up the crypt length (normally the proliferative zone is one third or less of the crypt length). Crypt irregularity often consists of a lateral proliferation of the crypts along the muscularis mucosae (boot-shaped crypts). These appearances should be contrasted with the smoothly rounded, non-dilated tubular crypt base that characterizes hyperplastic polyps. The superficial portion of the crypts in SSLs and hyperplastic polyps are similar morphologically. As per recent studies, and as summarized in the 5th edition of the WHO for Digestive Disease Tumours, the presence of ≥ 1 unequivocal architecturally distorted serrated crypt is sufficient for the diagnosis of SSL. Clinical features such as large size (≥ 10 mm) and right-sided location within the colon are more commonly seen in SSLs but, importantly, these features are not by themselves diagnostic, especially as the endoscopic size may be difficult to ascertain given the problems with delineating these lesions.

Dysplasia in SSLs show cytological changes resembling conventional dysplasia in adenomas and is usually sharply demarcated from the non-dysplastic area. Stratification into low-grade vs high-grade should not be done given the lack of reproducibility. Sessile serrated lesions with dysplasia (SSLD) are considered high risk and have a shorter surveillance interval than a SSL with no dysplasia.

Mixed Hyperplastic Polyp/Adenoma

These polyps are regarded as being entirely separate but physically adjacent lesions that have grown together. They represent an intermingling of polyp types. The components of mixed polyps should be separately identified and reported in the free text portion of the report. Be careful: do not confuse a mixed polyp with a SSLD. The follow-up of patients with this type of polyp will depend on the microscopic features of the adenomatous component.

Neuroendocrine Tumours

Many of these tumours were previously called carcinoid tumours. The term “carcinoid tumour” is now replaced by “low-grade/well-differentiated neuroendocrine tumour”. The majority of these neoplasms will be present in the rectum. High-grade neuroendocrine carcinomas are rare in the colon. They can be subdivided into large cell and small cell types. TNM staging of neuroendocrine tumours is available and should be quoted in pathology reports.

Hamartomas

Most hamartomatous bowel polyps are either Peutz-Jeghers polyps or juvenile polyps (retention polyp). If a Peutz-Jeghers polyp is diagnosed, then a clinical search for other features of the syndrome should be undertaken. It may also be advisable to test the patient for the germ-line mutations that typically characterize this condition. The majority of juvenile polyps are isolated and sporadic. Only rarely is

juvenile polyposis present.

Inflammatory Polyps

There are a wide variety of types of inflammatory polyps. These range from “(pseudo)polyps” found in inflammatory bowel disease to isolated granulation tissue polyps complicating diverticular disease. Subclassification of these polyps is not required by the Colon Screening Program. Nevertheless subclassification should be described in the comment section of the report when it is of clinical relevance.

Mesenchymal Polyps

A wide range of other types of mesenchymal polyp may be encountered. These include lipomas, leiomyomas, ganglioneuromas, gastrointestinal stromal tumour and vascular lesions. The diagnosis of one of these polyps does not generally trigger ongoing patient screening.

Others

There are many other types of colonic polyps although most of these are rare. The usual diagnostic criteria will apply.

Adenoma Containing an Invasive Carcinoma (‘malignant polyp’)

In order for carcinoma to be present within an adenoma, there must be definite evidence of a carcinoma invading into the submucosa. Carcinoma-like glands involving only the epithelium and lamina propria are referred to as high-grade dysplasia, rather than intramucosal carcinoma. As far as colonic polyps are concerned, the terms “carcinoma in situ” and “intramucosal carcinoma” should not be used as they are clinically misleading and may lead to inappropriate surgical over-treatment. Malignant polyps are often removed during colonoscopy without their malignant nature being apparent. Detailed reporting guidelines for this type of polyp are presented in Section 6.2. These are based on five criteria: the depth of invasion (polyp head or stalk), proximity to the resection margin (distance measured in millimeters), presence or absence of lympho-vascular invasion, histologic grade of the carcinoma and presence or absence of high grade tumour budding.

Suspicious for Carcinoma

For cases where high-grade dysplasia is present but unequivocal identification of submucosal invasion is lacking, report the diagnosis as an adenoma with high-grade dysplasia. Further description outlining the suspicion of carcinoma can be described in the free text component of the report.

5.4 Degree of Dysplasia

Adenoma may be either low-grade or high-grade. Adenoma with intermediate grades of dysplasia (moderate dysplasia) are now included in the low-grade category. The reason for this is that their clinical behavior and prognostic significance are similar to adenoma with low-grade dysplasia. Therefore, the majority of adenomas detected will have low-grade dysplasia. High-grade dysplasia should only be diagnosed in adenomas that display both high-grade cytologic atypia and high-grade structural complexity. These high-grade changes must involve more than two crypts.

High-grade cytologic dysplasia is characterized by marked elongation and enlargement of nuclei extending to involve more than 65% of the cell cytoplasm, loss of polarity and nuclear stratification, a dispersed chromatin pattern with prominent nucleoli, atypical mitoses and prominent apoptosis that gives the epithelium a “dirty” appearance.

High-grade architectural dysplasia is characterized by complex crypt crowding and irregularity, prominent budding, a cribriform appearance with “back to back” tubules (no lamina propria between crypts) and intraluminal tufting.

It should be recognized that low-grade and high-grade dysplasia are not completely separate entities and that some polyps will be encountered that have features straddling the above descriptions. Architectural high-grade dysplasia is usually obvious on low-power microscopic examination of the slide. Beware of confusing crush artifact with high-grade dysplasia. Crushing by biopsy forceps can produce an artificial apposition of glands as well as induce loss of polarity and nuclear stratification on the surface of an adenoma that otherwise shows only low-grade dysplasia. In cases of diagnostic difficulty, the slides may be referred to the reference centre for consultation.

The National Colorectal Screening Pathology Workshop recommends describing dysplasia as either:

- negative for high grade dysplasia; or,
- positive for high grade dysplasia.

Adenomas with high grade dysplasia are considered high risk lesions and have a shorter surveillance interval.

5.5 Completeness of Removal

Completeness of removal of neoplastic polyps especially those polyps defined as advanced adenoma should be reported if this is possible. This is particularly important in cases where a carcinoma is present within the adenoma (“malignant polyp”). However, assessment of incomplete removal is primarily endoscopic rather than pathologic. Reporting of completeness of excision is only required for high grade risk lesions. The default position is that it cannot be assessed.

6. Required Reporting for Colorectal Polyps

6.1 Reporting of Colorectal Specimens

For each specimen, the following (**bolded**) information must be recorded.

Specimen type and location (select one of the following):

- Ascending colon
- Cecum
- Descending Colon
- Ileum
- Other/Random
- Rectum
- Sigmoid
- Transverse colon

Diagnosis (select one of the following classifications from one of the following groups for each submitted specimen):

Adenoma group:

- Tubular adenoma
- Tubulovillous adenoma
- Villous adenoma
- Traditional serrated adenoma
- Mixed polyps
- Adenoma with misplaced epithelium
- Flat adenoma
- Sessile serrated lesion

Degree of conventional dysplasia:

For adenomas (except sessile serrated lesion), the phrase “positive for high grade dysplasia” should be used to indicate the presence of high grade dysplasia. The phrase “negative for high grade dysplasia” implies that low grade dysplasia is present. The diagnosis of “low grade dysplasia” can also be used.

For sessile serrated lesion, the phrase “positive for dysplasia” should be used to denote the presence of dysplasia.

The default position for completeness of excision (only required for high-grade lesions or above) is that it cannot be assessed by the pathologist in most instances.

Other polyp group:

- Hyperplastic polyp
- Juvenile polyp
- Inflammatory polyp
- Polypoid mucosal prolapse
- Peutz-Jeghers polyp
- Mesenchymal polyp
- Lymphoid polyp
- Other polyp

Non-polypoid lesion group:

- Normal mucosa
- Inflammatory bowel disease
- Other type of colitis
- Other

Non-diagnostic group:

- Cauterized tissue
- No specimen submitted

Carcinoma Group:

- Carcinoma within polyp (additional information is required, see Section 6.1 for details)
- Invasive carcinoma (see Section 6.2)
- Neuroendocrine tumours (use TNM staging)

6.2 Carcinoma Within Polyp ('Malignant polyp')

Mandatory Reporting Elements

For any polyp with a carcinoma within polyp histologic classification, the following five components must also be provided in the pathology report, in the following order:

1. Histologic grade (differentiation) of any amount of invasive component (select one of the following)

- Well-differentiated
- Moderately differentiated
- Poorly differentiated
- Undifferentiated

2. Lymphatic/vascular invasion

- present
- absent
- suspicious

3. Distance of carcinoma to (deep) resection margin (select one of the following):

____ mm

- present at deep margin
- cannot be assessed

4. High Grade Tumour budding

- present
- absent

High grade tumour budding has been shown to be a prognostic indicator of lymph node metastasis in pT1 lesions. Tumour budding has been defined as the presence of single cells or small clusters of less than five cells at the advancing front of the tumour. Numerous studies have shown that high tumor budding in adenocarcinoma arising in polyp is a significant risk factor for nodal involvement, with tumor budding being the most significant factor in some studies.

An international tumor budding consensus conference (ITBCC) in 2016 recommended the following criteria for evaluating tumor budding: (1) Tumor budding counts should be done on H&E sections. In cases of obscuring factors like inflammation, immunohistochemistry for keratin can be obtained to assess the advancing edge for tumor buds, but the scoring should be done on H&E sections. (2) Tumor budding should be reported by selecting a “hotspot” chosen after review of all available slides with invasive tumor. The total number of buds should be reported in an area measuring 0.785 mm², which corresponds to 20x field in some microscopes (objective magnification of 20); otherwise a conversion factor must be applied – see CAP guidelines for Colon Rectum 4.0.1.0 (2020), note F. (3) Both total number of buds and a three-tier score (based on 0.785 mm² field area) should be reported: low (0-4 buds), intermediate (5-9 buds) and high (10 or more buds).

References:

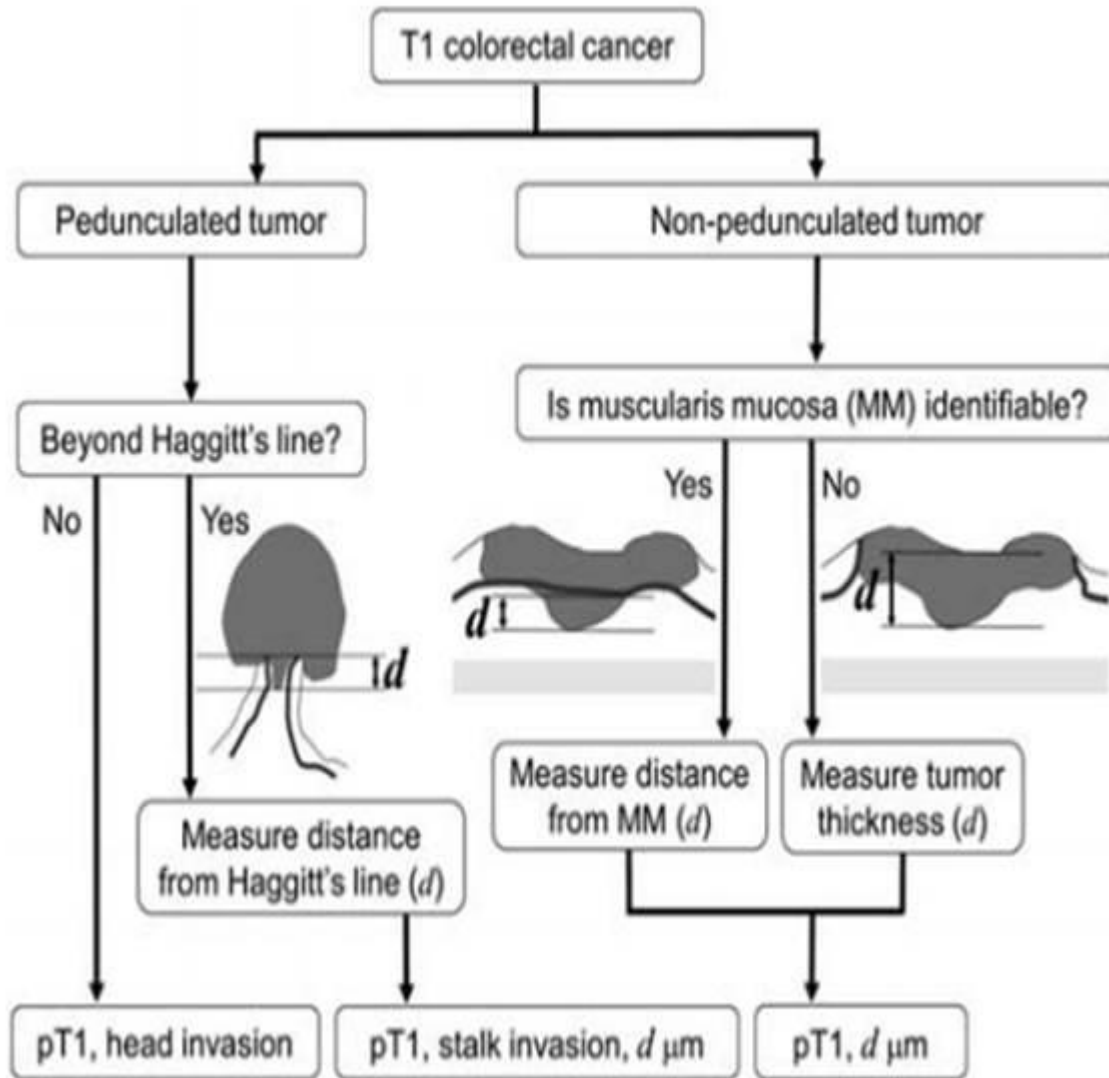
- 1) Bosch SL, Teerenstra S, de Wilt JH, Cunningham C, Nagtegaal ID. Predicting lymph node metastasis in pT1 colorectal cancer: a systematic review of risk factors providing rationale for therapy decisions. *Endoscopy*. 2013;45(10):827-834.
- 2) Ueno H, Mochizuki H, Hashiguchi Y, et al. Risk factors for an adverse outcome in early invasive colorectal carcinoma. *Gastroenterology*. 2004 ;127(2):385-394.
- 3) Choi DH, Sohn DK, Chang HJ, Lim SB, Choi HS, Jeong SY. Indications for subsequent surgery after endoscopic resection of submucosally invasive colorectal carcinomas: a prospective cohort study. *Dis Colon Rectum*. 2009;52(3):438-445.
- 4) Petrelli F, Pezzica E, Cabiddu M, et al. Tumour Budding and Survival in Stage II Colorectal Cancer: a Systematic Review and Pooled Analysis. *J Gastrointest Cancer*. 2015;46(3):212-218.
- 5) Graham RP, Vierkant RA, Tillmans LS, et al. Tumor budding in colorectal carcinoma: confirmation of prognostic significance and histologic cutoff in a population-based cohort. *Am J Surg Pathol*. 2015;39(10):1340-1346.
- 6) Koelzer VH, Zlobec I, Lugli A. Tumor budding in colorectal cancer-ready for diagnostic practice? *Hum Pathol*. 2016;47(1):4-19.
- 7) Lugli A, Kirsch R, Ajioka Y, Bosman F, et al. Recommendations for reporting tumor budding in colorectal cancer based on the International Tumor Budding Consensus Conference (ITBCC) 2016. *Mod Pathol*. 2017 Sep;30(9):1299-1311.

5. Arising within subtype of background polyp

- Tubular adenoma
- Tubulovillous adenoma
- Villous adenoma

Depth/Level of invasion (in mm) within a malignant polyp

Depth of invasion is a newer independent marker of high risk behavior in malignant polyps but recapitulates the notion of previously recognized increased risk of regional lymph node metastasis in association with the depth of submucosal invasion (e.g. Haggitt levels). Depth of submucosal invasion of greater than 1 mm is an independent marker for the risk of regional lymph node metastasis. Despite this, the assessment of depth of invasion can be challenging in day-to-day surgical practice and not every lesion is amenable to this assessment. Below is a diagram to help guide the assessment of depth of invasion.



Kawachi H, et al. Mod Pathol. 2015 Jun;28(6):872-9.

Given the variability in applying this criterion the Colon Screening Program recommends capturing this information in every report with a malignant polyp but recognizes that it may not be applicable in every lesion given either the orientation or overall size of the tissue fragment.

6.3 Medical Record Retention

The facility completing the pathology reporting is the primary record holder for documentation pertaining to pathology. Each facility follows internal policies with respect to record retention and documentation. The Colon Screening Program is a secondary user of the forms and records that are completed for program participants. Patients and providers requesting copies of their screening record will be directed to obtain copies from the facility where the interaction occurred.

7. Pathology Review

7.1 Pathology Review by the Health Authority

It is expected that pathology review for the purposes of quality assurance is undertaken by the Health Authority on a random sampling of cases as well as specific difficult diagnoses. It is recommended that this be performed externally and include assessment of diagnosis accuracy as well as completeness of the pathology report (see Section 6: Required Reporting for Colorectal Polyps).


7.2 Pathology Review by the Colon Screening Program

Annual pathology quality reports will be generated and distributed to pathologists participating in the Colon Screening Program individually and in aggregate form at a Health Authority and provincial level.

Annual audit of all reports of malignant polyps will be undertaken to assess for compliance with reporting of high-risk features. In addition, other audits may be undertaken based on reviews and recommendations of the Quality Management Committee.

Colon Screening Program pathology data is reviewed regularly by the Colon Screening Program Pathology Lead and will be shared with the pathology representatives from each health authorities as appropriate.

Appendix A – Colonoscopy Reporting Form



COLONOSCOPY REPORTING FORM

PRESS FIRMLY TO ENSURE LEGIBILITY FOR MULTIPLE COPIES
FAX TOP COPY TO COLON SCREENING PROGRAM: 1 (604) 297 9340
GREY SECTIONS TO BE COMPLETED AS REQUIRED

DO NOT PLACE LABEL ABOVE LINE

AFFIX CLIENT LABEL HERE

EXAM DATE (YYYYMMDD) _____

FACILITY NAME _____

COLONOSCOPIST (MSC) _____

START TIME (HRS) _____

AMENDED DATE (YYYYMMDD) _____

COLONOSCOPIST LAST, FIRST _____

PHN _____

PATIENT NAME LAST _____

PRIMARY PROVIDER (MSC) _____

DATE OF BIRTH (YYYYMMDD) _____

PATIENT NAME FIRST _____

PRIMARY PROVIDER LAST, FIRST _____

Reason for Colonoscopy (select one):

FIT Family History Surveillance Deviation

Reason Colonoscopy did not occur (select one):

No Show for Colonoscopy Medically unfit day of procedure

1. BOWEL PREPARATION

Excellent Good

Fair (adequate to visualize all polyps > 5mm)

Poor (inadequate to visualize all polyps > 5mm)

2. CECAL INTUBATION (or ileocolonic anastomosis reached)

Yes → Photo documentation? No Yes

No Uncertain Flexible Sigmoidoscopy

3. UNPLANNED EVENTS None

Perforation Admit to hospital

Bleeding Reversal agents

Cardiovascular Death

Respiratory Other (specify): _____

4. SPECIMENS TAKEN: Yes No → **WITHDRAWAL TIME:** _____ (Minutes)

5. COMMENTS TO PATHOLOGIST:

	Specimen Type	Location	Size (mm)				Morphology	Primary Removal Mode	Submucosal Injection (Y/N)	Piecemeal (Y/N)	Complete Removal (Y/NU)	Complete Retrieval (Y/NU)	Specimen Sent (Y/N/#)	Time	Initials
			≤ 5	6-9	10-19	≥ 20									
Example	P	T		✓			P	HS	Y	Y	Y	Y	Y	14:00	AB
1/A															
2/B															
3/C															
4/D															
5/E															

6. Additional specimens recorded on Page 2

7. Repeat Colonoscopy Required

COMPLETE COLONOSCOPY REPORTING FORM FOR NEXT SCOPE

Specimen Type	Location	Morphology	Removal Mode
B = biopsies P = polypectomy	A = ascending colon C = cecum D = descending I = ileum L = left colon O = other/random R = rectum S = sigmoid T = transverse colon	F = flat M = mass O = other P = pedunculated S = sessile	BF = biopsy forceps CS = cold snare HB = hot biopsy forceps HS = hot snare
Y = yes N = no U = uncertain			

MD NAME: _____ SIGNATURE: _____

RN NAME: _____ SIGNATURE: _____

SEND COPIES OF PATHOLOGY REPORT TO:

1. BC Cancer Colon Screening 2. _____ 3. _____ 4. _____
 Fax#: 1 (604) 297 9340 Primary Provider (Name & MSC#) Other (Name & MSC#) Other (Name & MSC#)

Specimen tracking required by facility? No Yes →

Number of samples sent to collection area: _____ INITIALS _____ DATE: _____


Number of samples transported to lab: _____ INITIALS _____ DATE: _____

Number of samples received by lab: _____ INITIALS _____ DATE: _____

PATHOLOGY COPY | FAX THIS COPY TO 1 (604) 297 9340

INFORMATION ON THIS FORM IS CONFIDENTIAL. IF YOU RECEIVE THIS IN ERROR PLEASE FAX TO QUALITY DEPT: 1 (604) 675 7223

20220



Appendix B – Protocol for Handling a Polyp Specimen

Examine the specimen promptly. The specimen is typically received in 10% buffered formalin. If unfixed, add fixative and leave overnight to fix. Small polyps can be fixed intact. Sessile lesions can be pinned out on a thin paper board or on any suitable smooth surface before fixing.

1. Check and dictate the patient's name on the specimen container, matching with the name on the requisition form.
2. Dictate the time stamp when the specimen was taken. If there is no time stamp on the container, this should be noted.
3. Dictate clinical details recorded on the request form.
4. Dictate the site of the specimen, type of the endoscopic procedure, biopsy, or a excision of polyp and any description of the specimen as labeled on the specimen container.
5. Count and dictate number of pieces of tissue in each container.
6. Measure the size of the specimen in mm.
7. Examine the specimen to determine if it is a biopsy tissue fragment; polypoid; or sessile, and describe it.
8. If the specimen is a small fragment or polypoid but less than 5 mm and without stalk, submit in toto without dissection.
9. If the specimen is polypoid and larger than 5 mm but smaller than 10 mm, ink the biopsy margin or base of the stalk and then bisect the polyp at right-angles the biopsy margin or stalk. Embed the section on cut surface
10. If the specimen is polypoid and larger than 10 mm and with a stalk, ink the base of the stalk and then section the specimen at right-angles to the inked margin with 3 mm slices and leave the central section containing the intact stalk. Embed all sections on cut surface and submit sequentially in cassettes for histology.
11. If the specimen is sessile, ink the base of the biopsy/resection and section the specimen at right-angles through the base of the specimen with 3 mm sequential slices. Embed the tissue on the cut surface and submit sequentially in cassettes for histology.
12. All of the tissue within the container, including the fragmented pieces should be submitted for histology.
13. If the specimen is large or "complicated", the attending pathologist should be consulted prior to processing.
14. At least two H&E sections should be routinely cut on each embedded tissue block. Additional (deeper) sections may be required for polyps containing pseudoinvasion or invasive carcinoma ("malignant polyp").

15. When embedding histological sections, orientate the tissue (polyp) or tissue fragments like other GI biopsy specimens prior to cutting.

Appendix C – Sample Pathology Report

Patient Identifiers:

Specimens Received

- A. Colon, Sigmoid, Biopsies
- B. Colon, Cecum, Biopsies
- C. Colon, Ascending, Polyp
- D. Colon, Rectum, Biopsies
- E. Colon, Transverse, Biopsies
- F. Colon, Transverse, Biopsies

Gross Description

This description should follow the usual convention of the facility's pathology report.

Histologic Classification

This should follow the standard format of:

Specimen location and type/identification: Diagnosis

For example:

A. Sigmoid biopsies:

- Tubular adenoma, negative for high grade dysplasia (or showing low grade dysplasia)

B. Cecal biopsies:

- Sessile serrated lesion, negative for dysplasia

C. Ascending colon polyp:

- Tubulovillous adenoma, positive for high grade dysplasia, fully excised

D. Rectal biopsies:

- Hyperplastic polyps

E. Transverse colon polypectomy:

- Tubulovillous adenoma, negative for high grade dysplasia (or showing low grade dysplasia)

F. Left Colon Polypectomy

- Invasive colonic adenocarcinoma, low-grade, arising within a tubular adenoma:

- See synoptic report for additional histologic parameters

Comments

Further description regarding any or all of the specimens submitted. This could relate to a more specific histologic classification or description or could provide further information on the size of the polyp or the reason for not being able to assess the completeness of excision.

Log Revision History

Version	Date	Action	Sections affected	Details
1.0	05 November 2013	Created	All	New release
1.1	7 Dec 2015	Updated		
1.2	9 Oct 2018	Updated	1.4, 5.3 (Adenoma with Misplaced Epithelium), 6.1, 6.2 (removed), 7.2.	BC Cancer Branding Change, terminology updates, reporting requirement updates, reference updates.
	20 Nov 2018	Updated	6.2	Reporting of malignant polyps updated to reflect current standards and feedback from pathologists.
	November 2019	Updated	5.3	Major revision - sessile serrated lesion terminology change throughout. Minor revisions throughout.
	July 2020	Updated	Appendix B	Removed all instances of "Mucosal resection specimen (EMR)"
	July 2022	Updated	All	Updated GPAC Guidelines.