

# Familial Brain Tumour Syndromes

Stephen Yip, M.D., Ph.D., FRCPC

Vancouver General Hospital  
BC Cancer

2018

---

## Objectives

1

Review basic genomic pathology of CNS tumours

2

List the common familial brain cancer syndromes

3

Describe their clinical presentations and underlying genetic features

## Some Familial Brain Tumour Syndromes

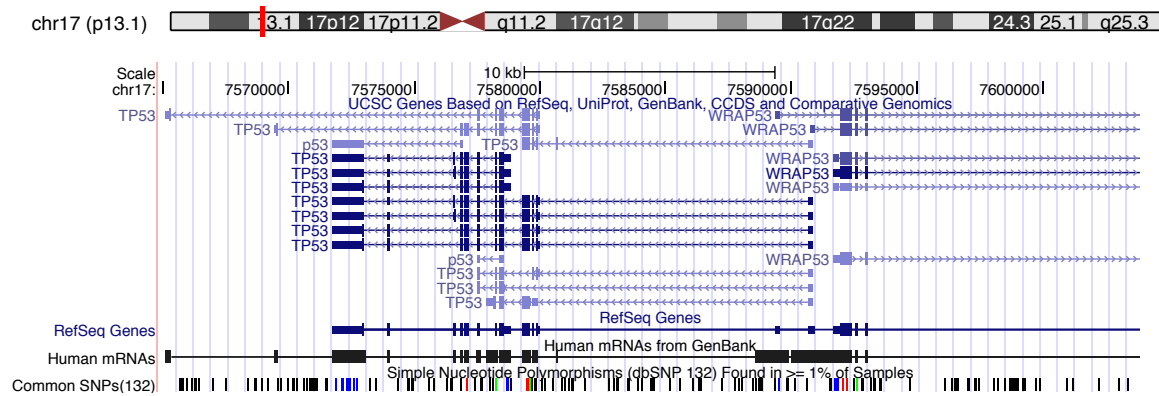
Tumour	Known genetic defects	Syndrome if germline ?
Neurofibroma	<i>NF1</i>	Neurofibromatosis 1
Multiple meningiomas, bilateral vestibular schwannomas	<i>NF2</i>	Neurofibromatosis 2
Hemangioblastoma	<i>VHL</i>	Von Hippel Lindau
Glioma (predisposition)	<i>P53, MSH2, MSH6</i>	Li-Fraumeni, Turcot
AT/RT, MRT, peripheral schwannoma	<i>SMARCB1</i>	Rhabdoid tumour predisposition, Familial schwannomatosis
Medulloblastoma (desmoplastic/nodular)	<i>PTCH</i>	Gorlin
Dysplastic gangliocytoma	<i>PTEN</i>	Lhermitte-Duclos
SEGA	<i>TSC1/2</i>	Tuberous Sclerosis
Glioma	<i>L2HGDH (IDH1/2)</i>	L-2-hydroxyglutaric aciduria
Pituitary adenoma (3 Ps)	<i>MEN1</i>	MEN (Werner Syndrome)
Psammomatous melanotic schwannoma	<i>PRKAR1A</i>	Carney Complex

## Phakomatoses

- Neurocutaneous syndromes
- CNS disorders with concurrent skin and eye lesions
- Common ectodermal origin
  - Neurofibromatosis
  - Tuberous sclerosis
  - Ataxia telangiectasia
  - Sturge-Weber syndrome
  - Von Hippel-Lindau syndrome
  - Incontinentia pigmenti
  - Nevoid basal cell carcinoma syndrome (Gorlin)

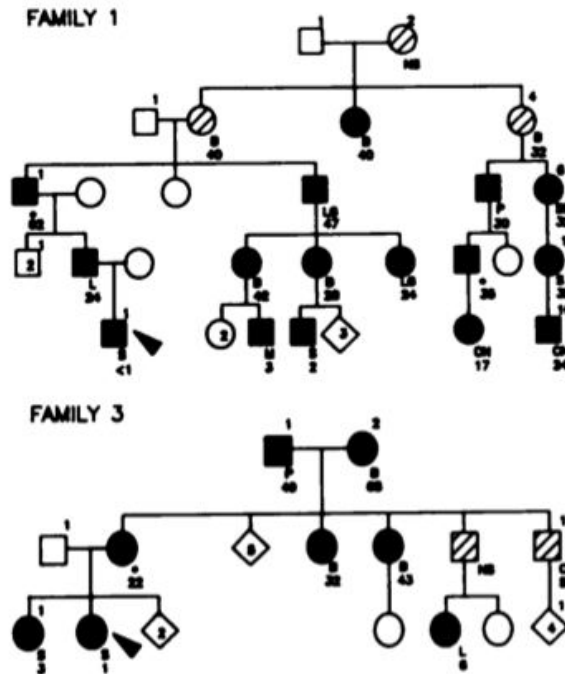
# Cancer susceptibility syndromes

- Li- Fraumeni (TP53)
  - 17p13

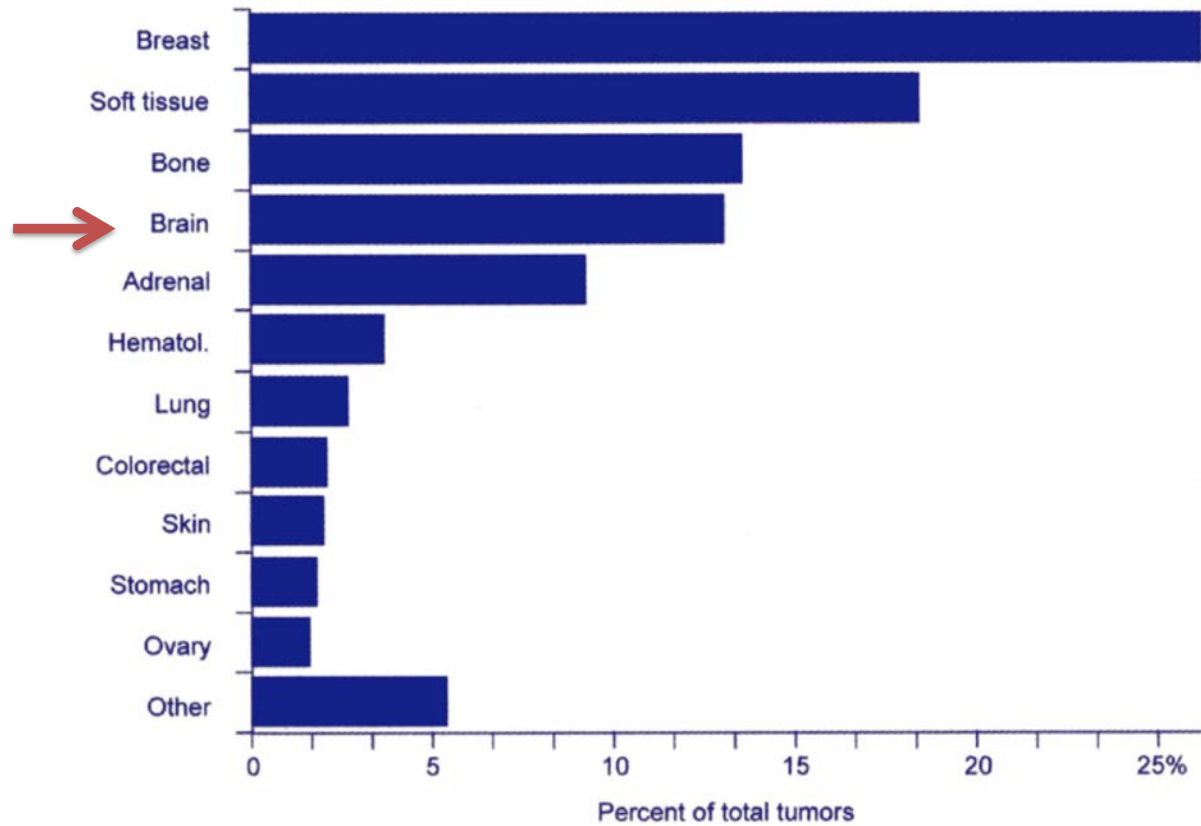


# Li-Fraumeni Syndrome

- Autosomal dominant transmission pattern

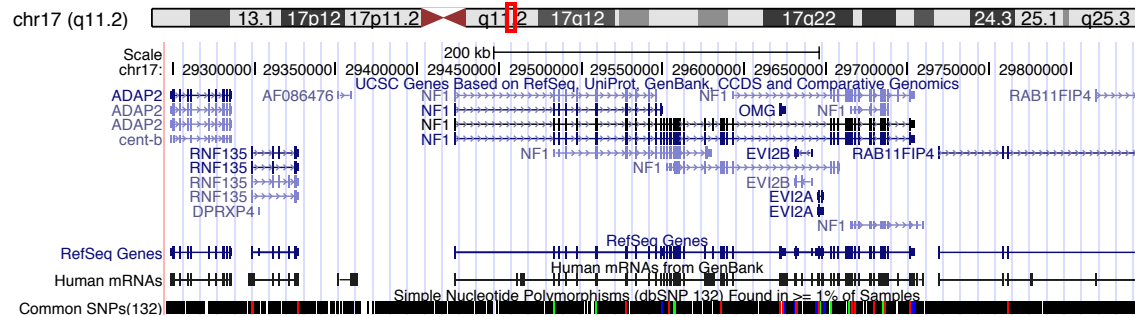


## Distribution of cancers in Li-Fraumeni Syndrome



# Neurofibromatosis 1 (NF1)

- Neurofibromin - 17q11



- Autosomal dominant
- De novo mutation, mosaicism
- 13kb
  - 3 alternatively spliced isoforms
  - No hot spot mutations, >300 identified (E10a-10c), pseudogenes

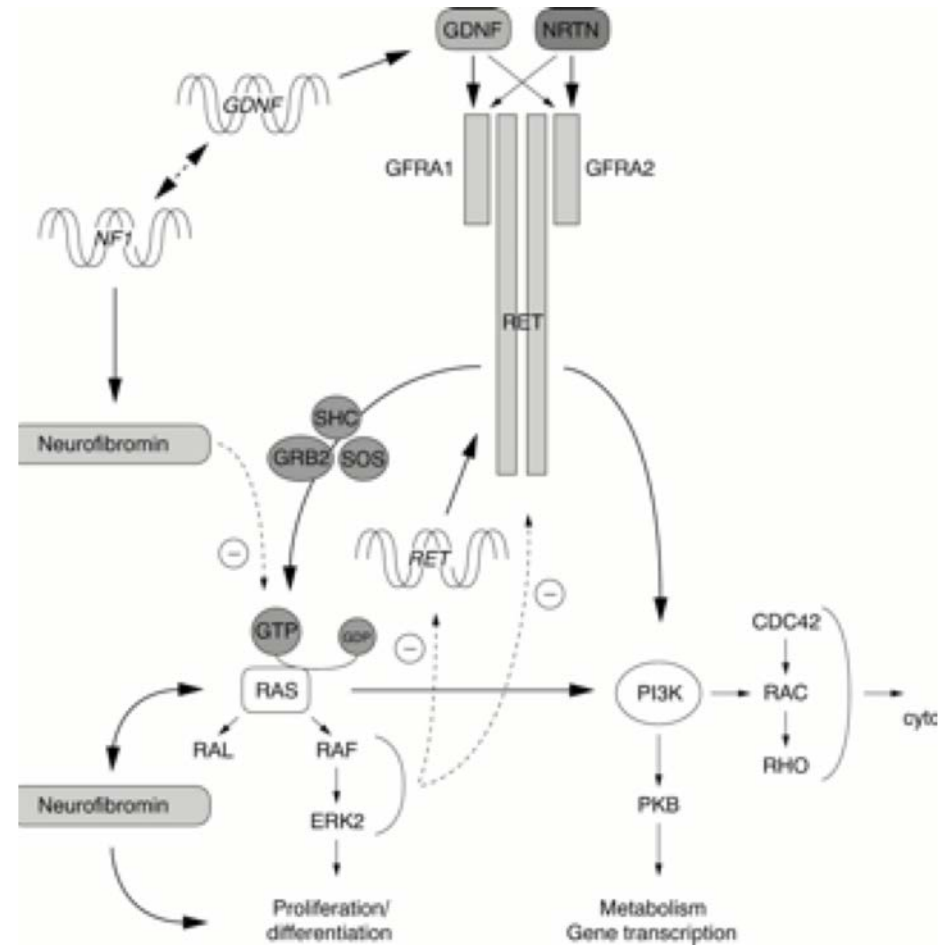


## Neurofibromatosis 1 (NF1)

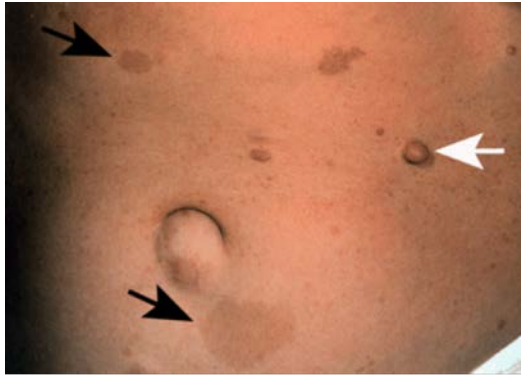
- Prevalence 1:3000
- Higher in Arab-Israeli subpopulations
- Dermal neurofibroma
  - Well- circumscribed, non- encapsulated
  - Schwann cells and fibroblasts, endothelial cells, lymphocytes, and mast cells
- Plexiform neurofibroma
  - Diffuse enlargement of major nerve trunks and branches “ropey”
  - 10% lifetime risk of malignant progression
- Gliomas
  - Pilocytic astrocytomas along the optic pathway
- Others
  - Macrocephaly, ADHD, epilepsy, hydrocephalus, aqueductal stenosis

# Neurofibromin

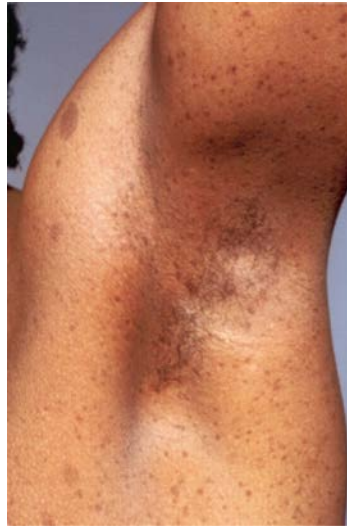- 220- 250 kD
- RasGTPase – activating protein
- Loss of function leads to activation of RAS isoforms and downstream growth and survival pathway



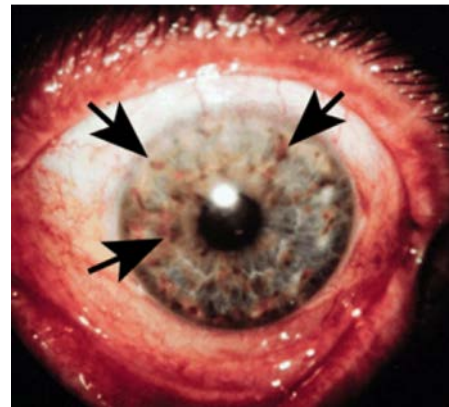
# Neurofibromatosis 1 (NF1)



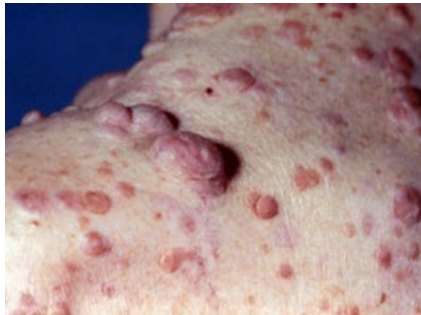Café au lait spots  
Sessile cutaneous neurofibroma



Axillary freckling



Lisch Nodule

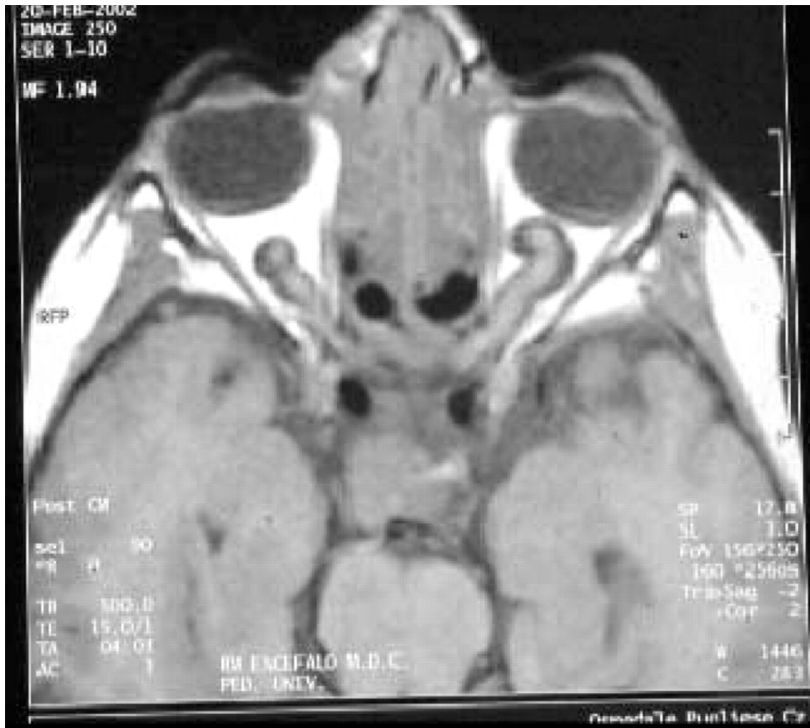

Cutaneous neurofibroma

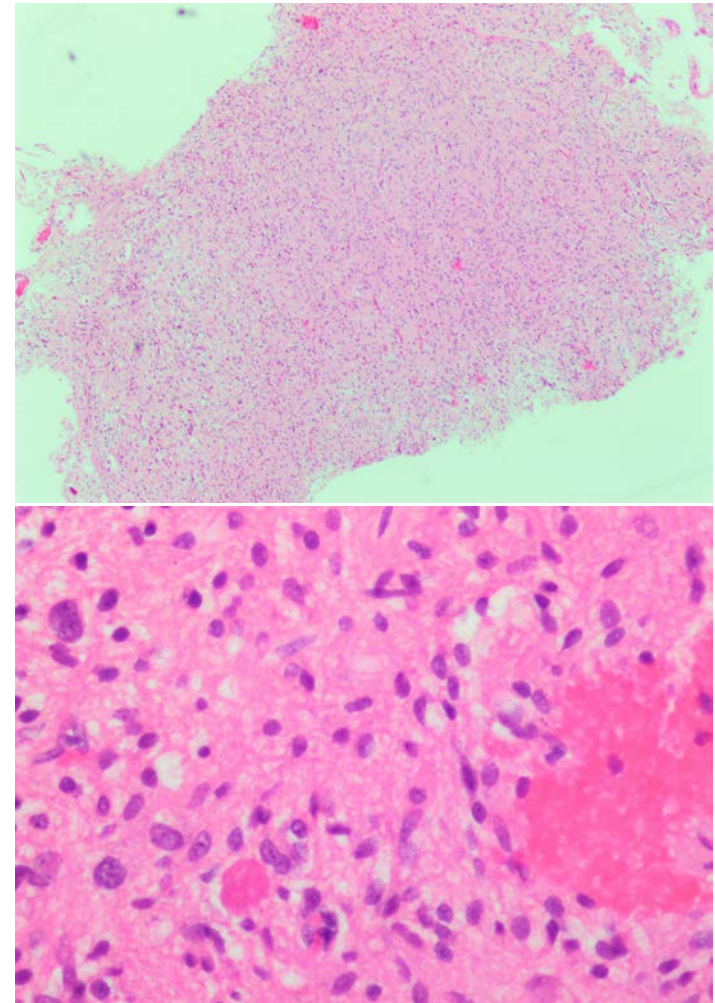
Levy AD, Patel N, Dow N, et al: From the archives of the AFIP: abdominal neoplasms in patients with neurofibromatosis type 1: radiologic-pathologic correlation. Radiographics 25:455-80, 2005

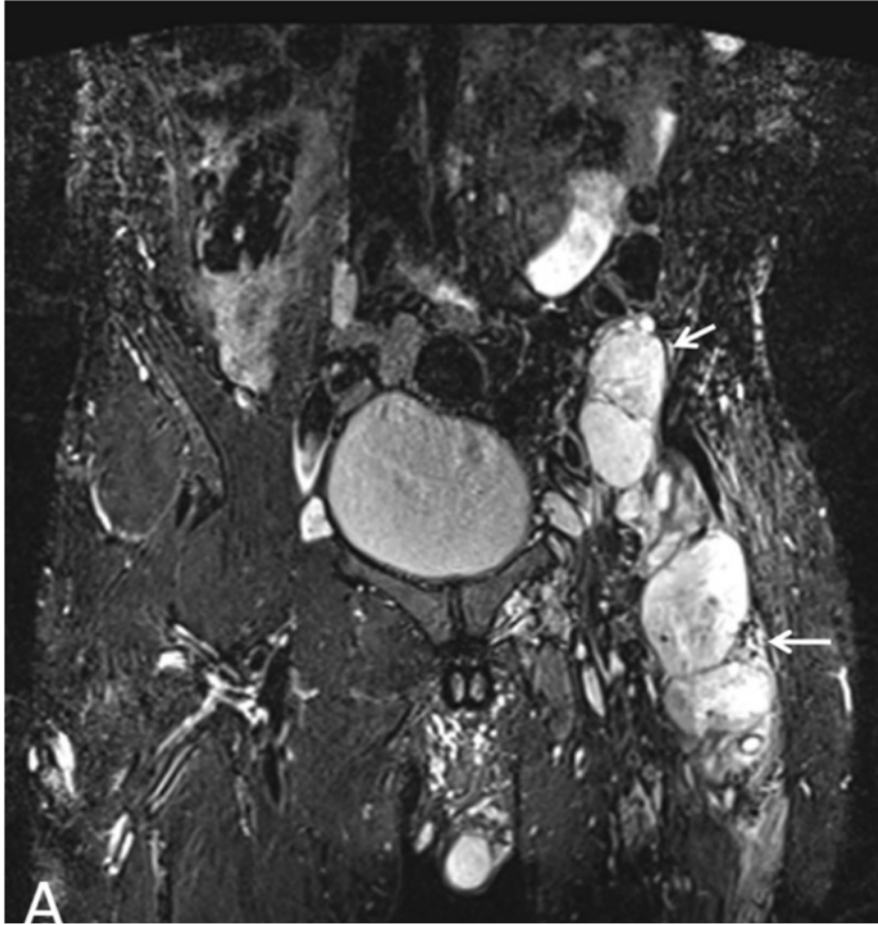
Jones J, Brenner C, Chinn R, et al: Radiological associations with dermatological disease. Br J Radiol 78:662-71, 2005

## Optic pathway glioma – pilocytic astrocytoma

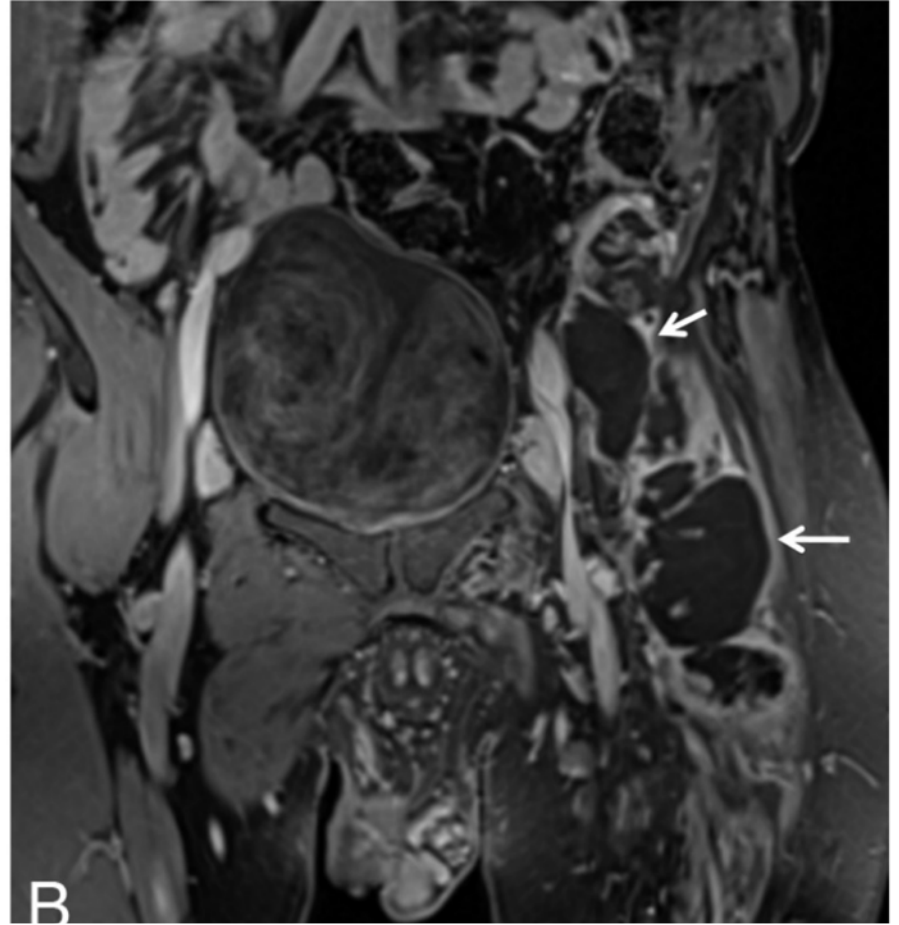


<http://dx.doi.org/10.1136/bjo.2004.043802>



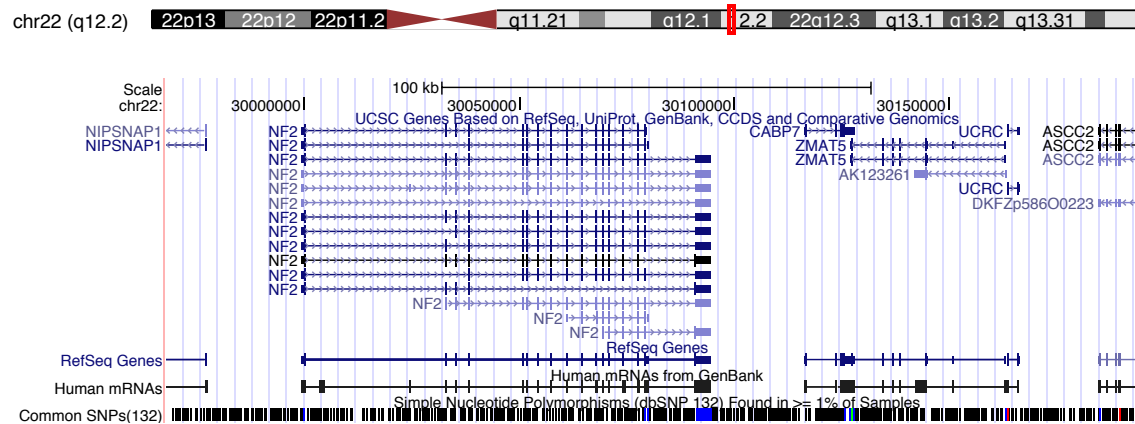


<https://doi.org/10.3174/ajnr.A2257>



# Neurofibromatosis 2 (NF2)

- Merlin - 22q12

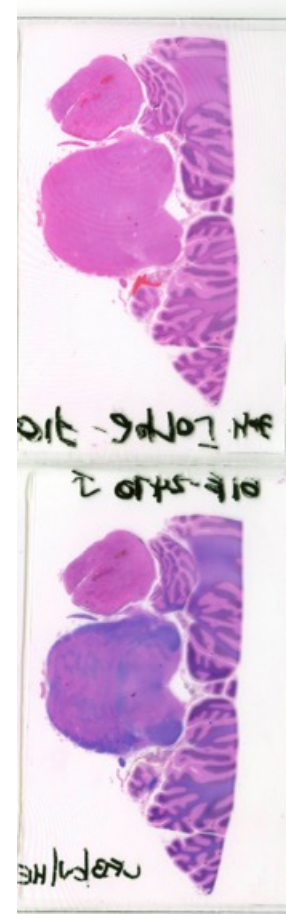
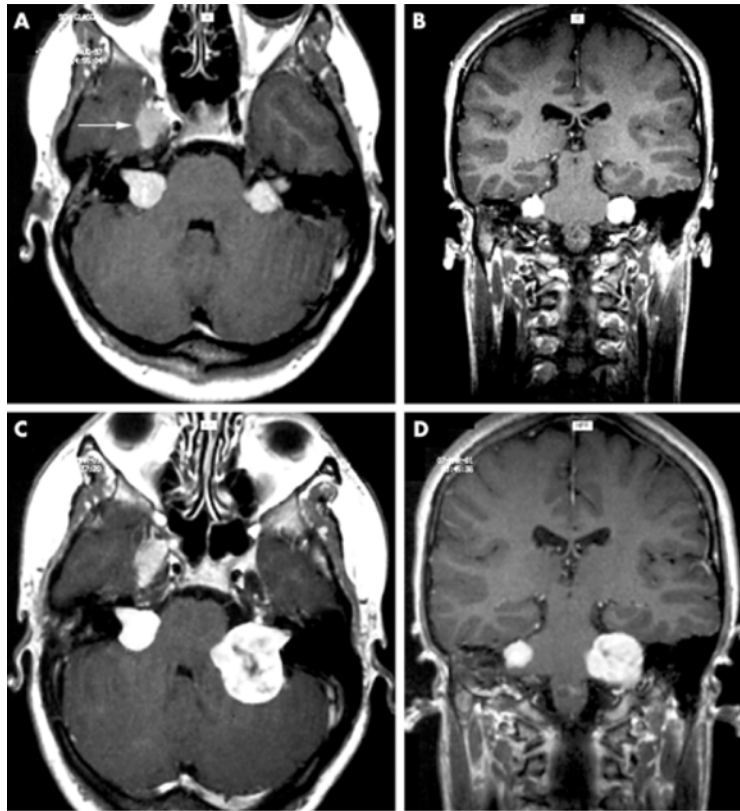


- Autosomal dominant
- 110 kb
  - 17 exons, 2 alternatively spliced isoforms

## Neurofibromatosis 2 (NF2)

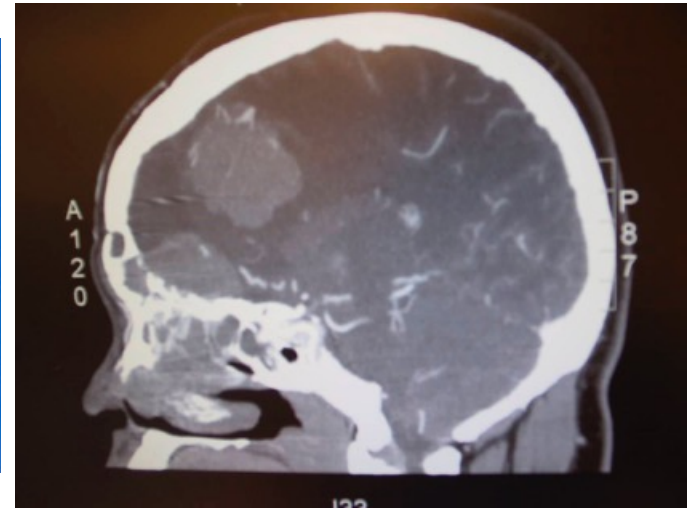
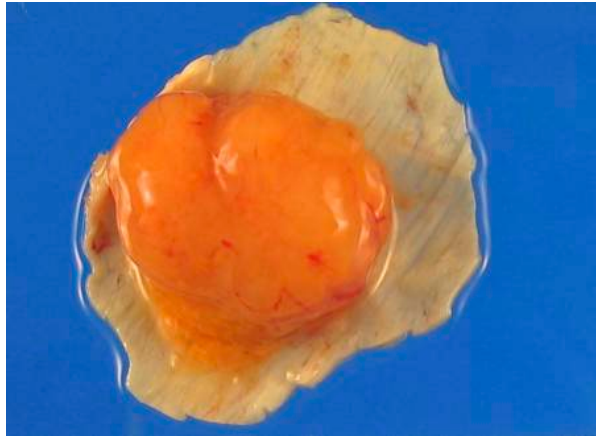
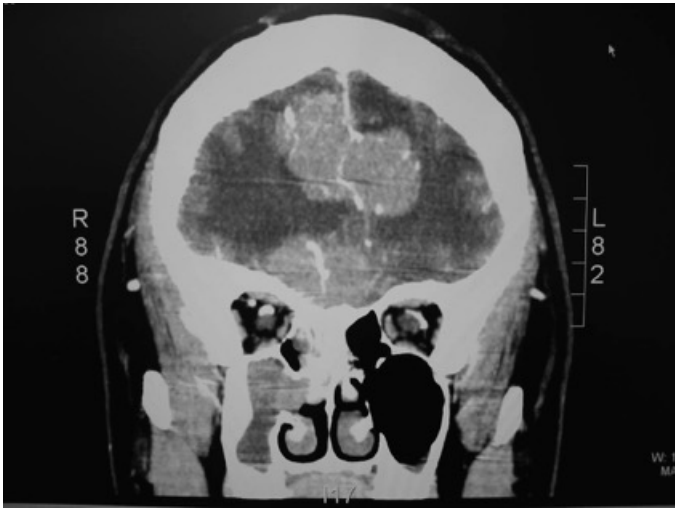
- Incidence 1:25000- 40000
- 50% are de novo germline mutations (founders)
- Schwannoma (WHO I)
  - Earlier onset, bilateral vestibular schwannomas
  - Also can affect other CNs including V, VII, XII
- Meningioma (WHO I)
  - Earlier onset, might behave more aggressively
- Glioma
  - 80% are spinal intramedullary/cauda equina tumours – can present as multiple masses
  - 10% intramedullary
  - 65-75% are ependymomas
- Others
  - Schwannosis, meningoangiomas

## Neurofibromatosis 2 (NF2)





## Neurofibromatosis 2 (NF2)



# Neurofibromatosis 2 (NF2)

ORIGINAL ARTICLE

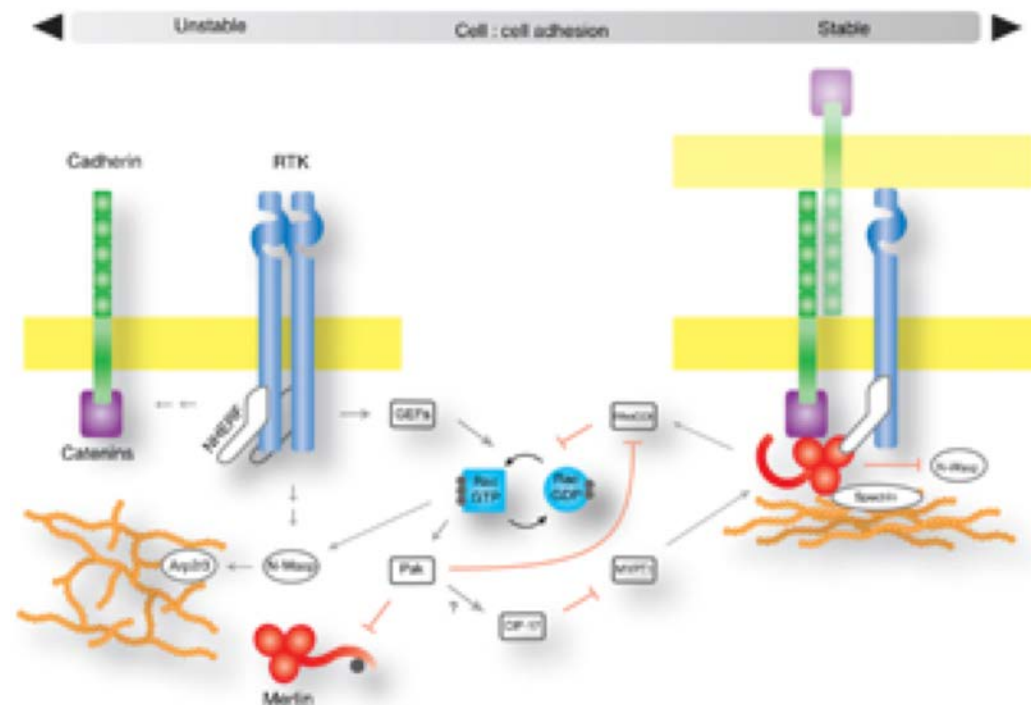
## Hearing Improvement after Bevacizumab in Patients with Neurofibromatosis Type 2

Scott R. Plotkin, M.D., Ph.D., Anat O. Stemmer-Rachamimov, M.D.,  
Fred G. Barker II, M.D., Chris Halpin, Ph.D., Timothy P. Padera, Ph.D.,  
Alex Tyrrell, Ph.D., A. Gregory Sorensen, M.D., Rakesh K. Jain, Ph.D.,  
and Emmanuelle di Tomaso, Ph.D.

ABSTRACT

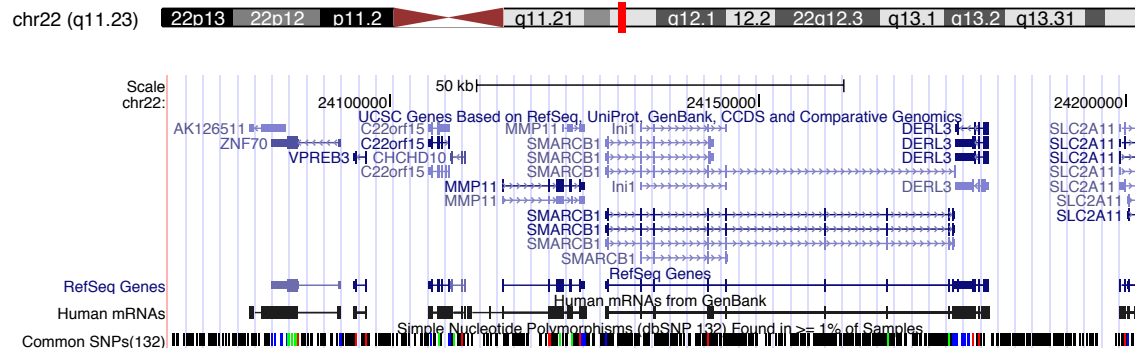
# Neurofibromatosis 2 (NF2)

- Germ line mutations
  - Affecting splice junctions, nonsense mutations
  - Found throughout gene but concentrating in E1-8
  - Position 169 (E2) C->T at CpG
- Merlin
  - Regulates signal transductions from membrane associated proteins via interaction with actin cytoskeleton



# Familial Schwannomatosis

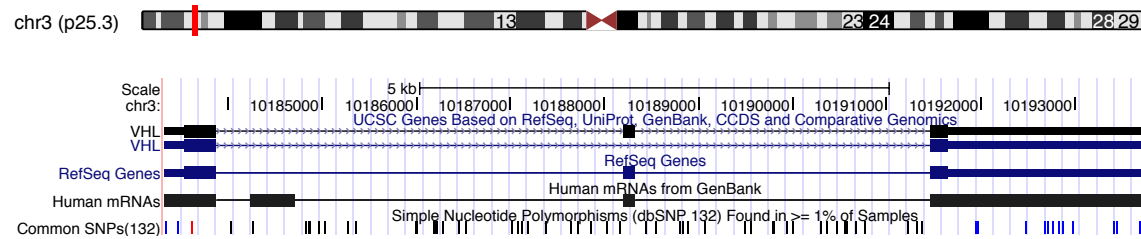
- SMARCB1 – 22q11



- Neurilemmomatosis, multiple schwannomas
- Not affecting vestibular nerves or have other manifestations of NF2
- Autosomal dominant, sporadic

# Von Hippel Lindau Syndrome (VHL)

- VHL - 3p25

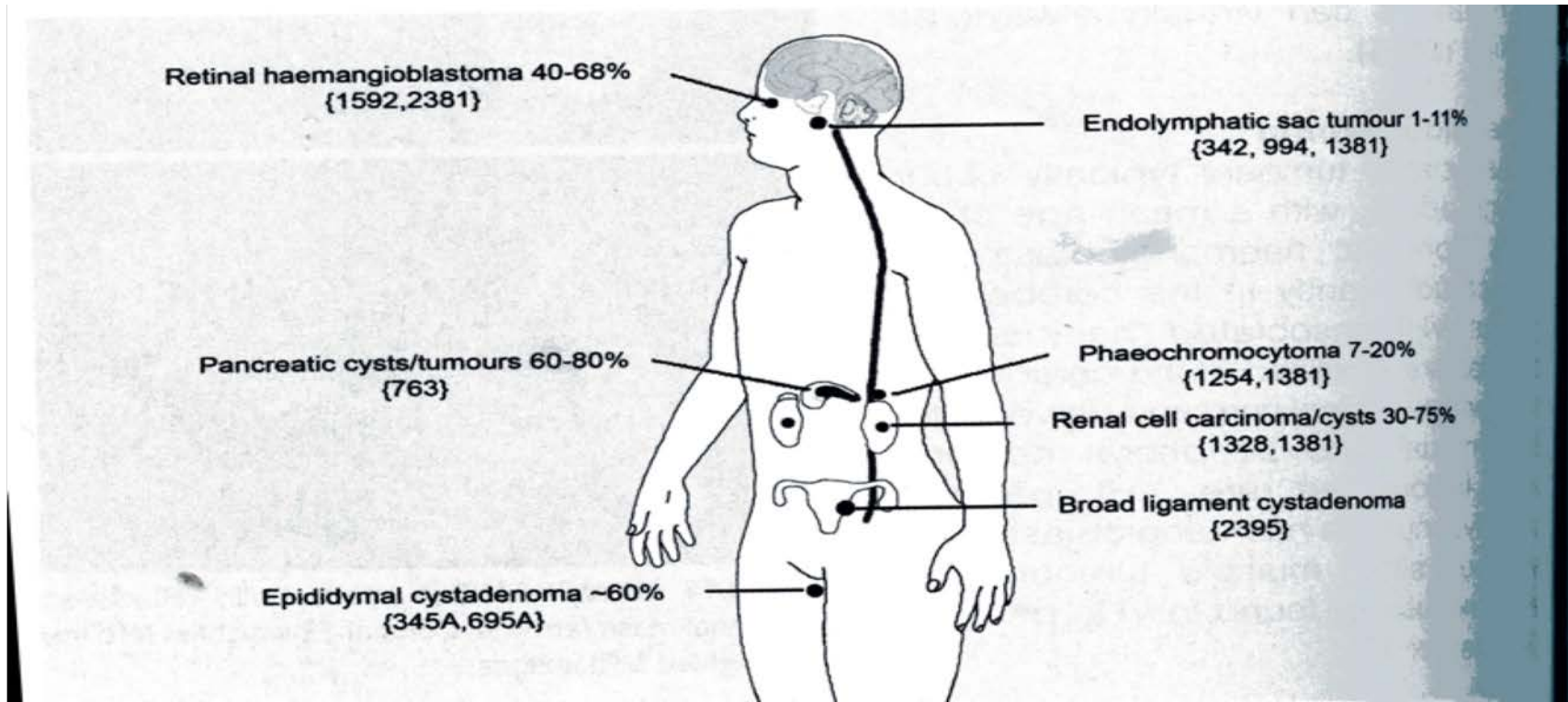


- Autosomal dominant
- 639 nucleotides

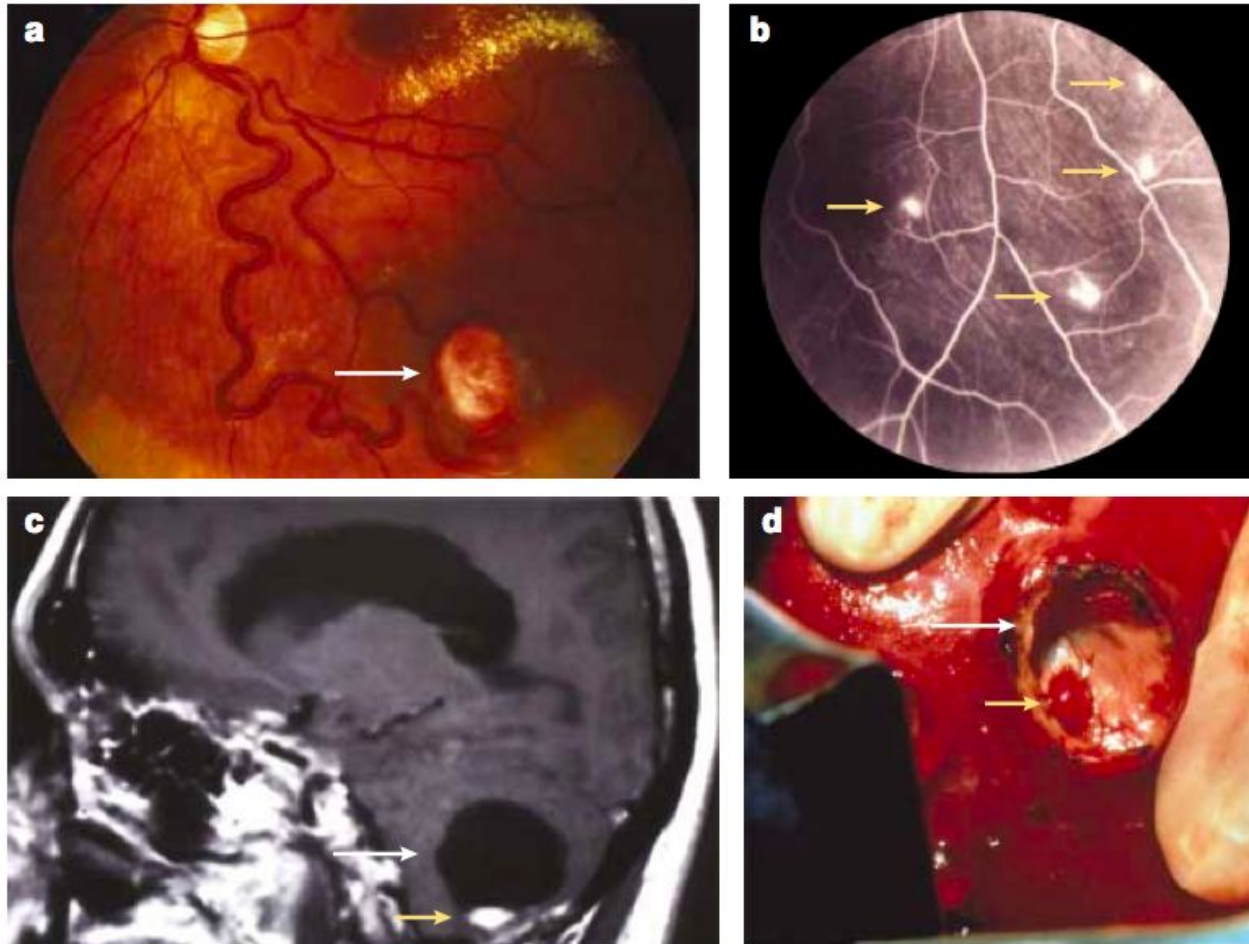
## Von Hippel-Lindau Disease (VHL)

- Incidence 1:36000- 45500
- Hemangioblastoma
  - CBx, BS, SC, nerve roots
  - ***Multiple and recurrent***
  - Vascular & stromal cells
- Extra CNS manifestations
  - Retinal angiomas
  - Clear cell RCC, Pheochromocytoma
  - ELST, pancreatic lesions (cysts, serous cystadenomas, neuroendocrine tumours)

# Von Hippel-Lindau Disease (VHL)



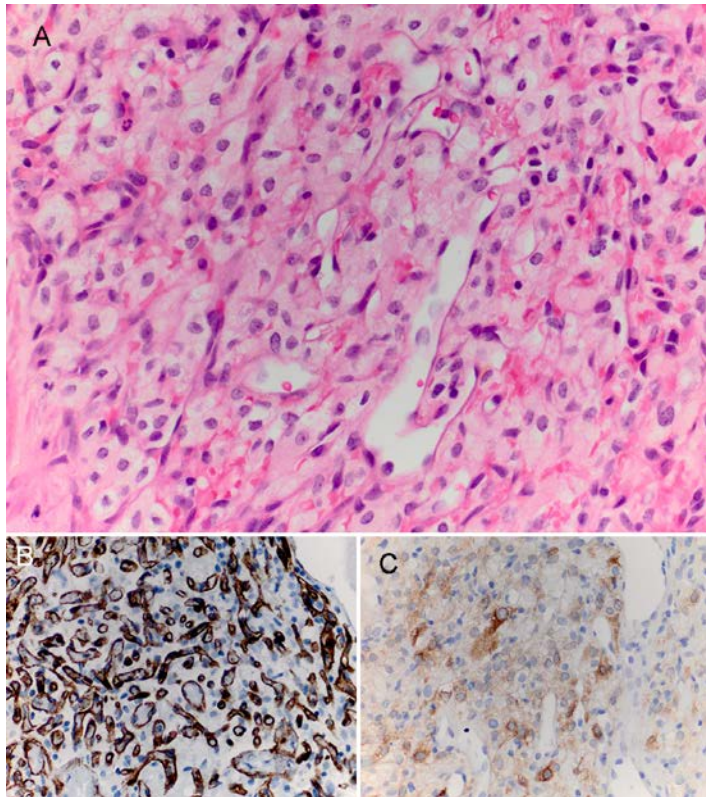
## Von Hippel-Lindau Disease (VHL)



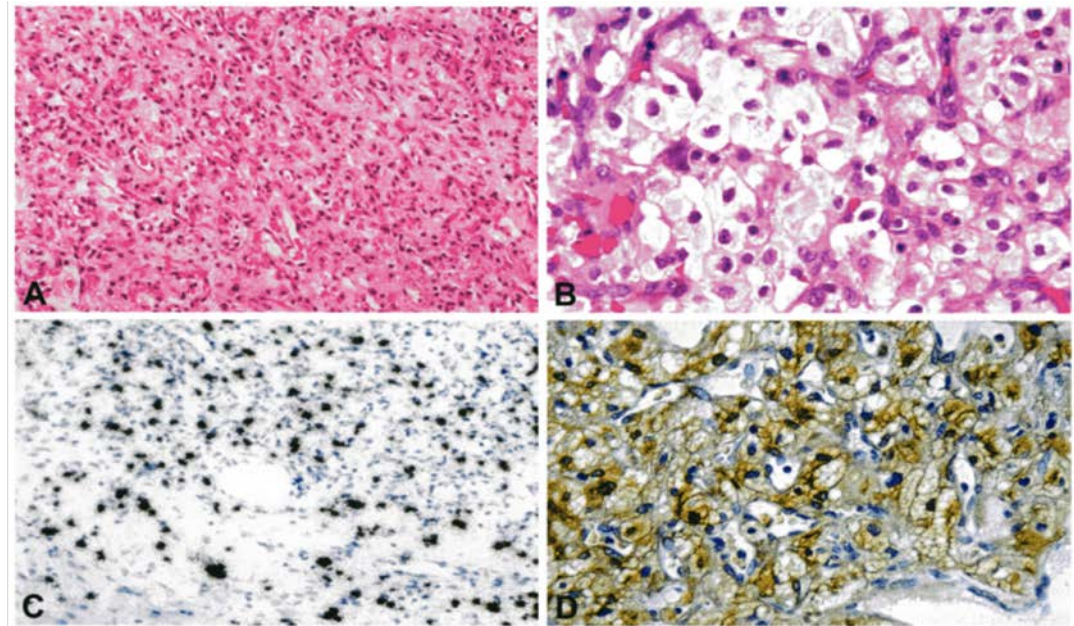
Kaelin WG, Jr.: Molecular basis of the VHL hereditary cancer syndrome. *Nat Rev Cancer* 2:673-82, 2002



## Hemangioblastoma



## Clear cell RCC



PMID26086055

# Von Hippel-Lindau Disease (VHL)

Table 1 | **Characteristics of different types of VHL disease**

Type of VHL disease	VHL mutation type	Molecular defect	Clinical manifestation
Type 1	Loss of <i>VHL</i> or a mutation that affects protein folding	Upregulation of HIF- $\alpha$ and HIF target genes	Haemangioblastomas Diminished risk of pheochromocytoma Renal-cell carcinoma
Type 2A	<i>VHL</i> missense mutation	Upregulation of HIF- $\alpha$ and HIF target genes	Haemangioblastomas Pheochromocytoma Low risk of renal-cell carcinoma
Type 2B	<i>VHL</i> missense mutation	Upregulation of HIF- $\alpha$ and HIF target genes	Haemangioblastomas Pheochromocytoma High risk of renal-cell carcinoma
Type 2C	<i>VHL</i> missense mutation	pVHL retains ability to degrade HIF- $\alpha$ ; decreased binding to fibronectin — fibronectin-matrix-assembly defect	Pheochromocytoma only

HIF, hypoxia-inducible factor; VHL, von Hippel-Lindau.

## Von Hippel-Lindau Disease (VHL)

- Promotes degradation of HIF1 complex that is normally assembled in hypoxic conditions
- Constitutive expression of VEGF
- No hot spots (throughout all 3 exons) but genotype:phenotype correlation
- CNS hemangioblastoma & RCC major cause of mortality
- Average life expectancy 40-50 yr
- Genetic testing for young patient w CNS hemangioblastoma

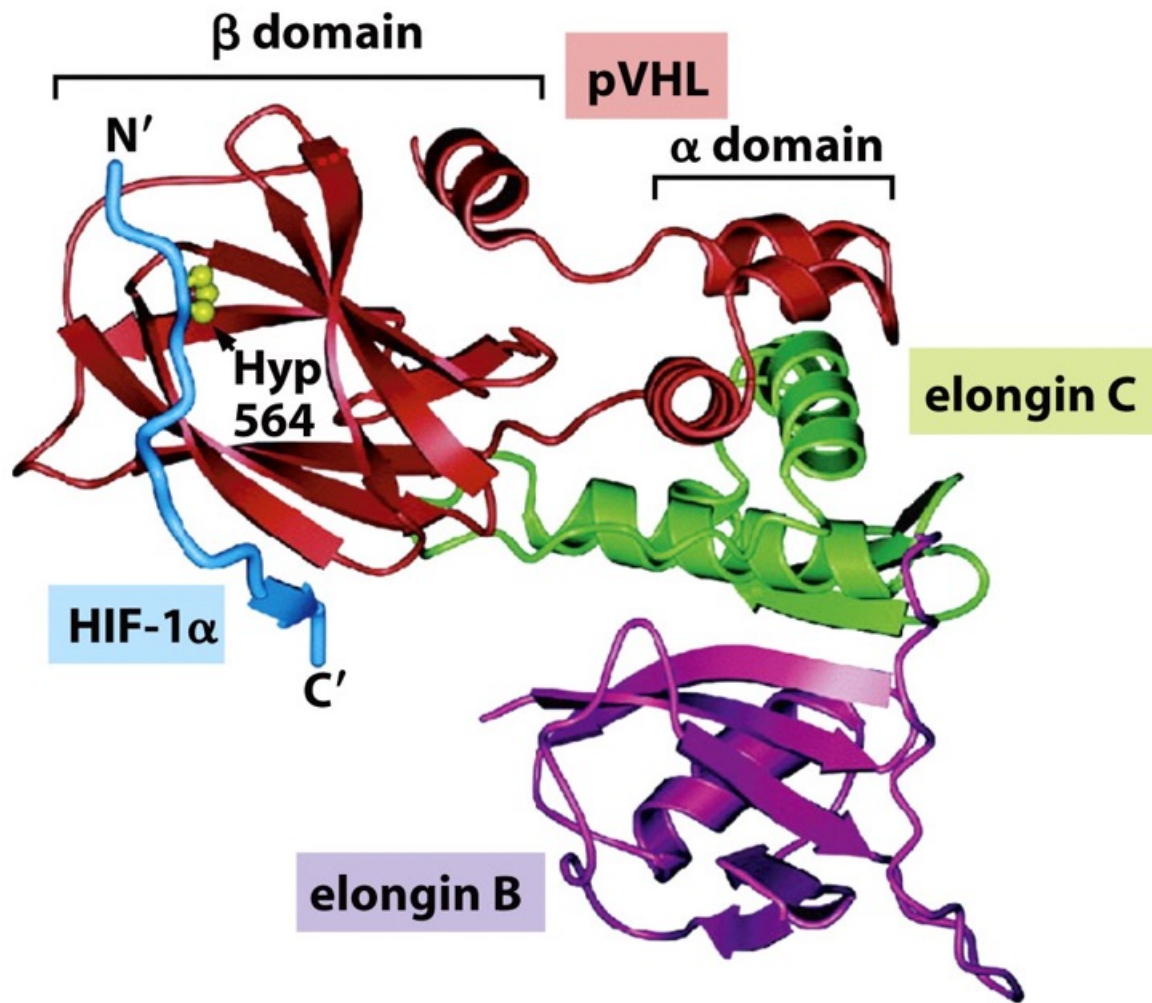


Figure 7.29b *The Biology of Cancer* (© Garland Science 2007)

# Von Hippel-Lindau Disease (VHL)

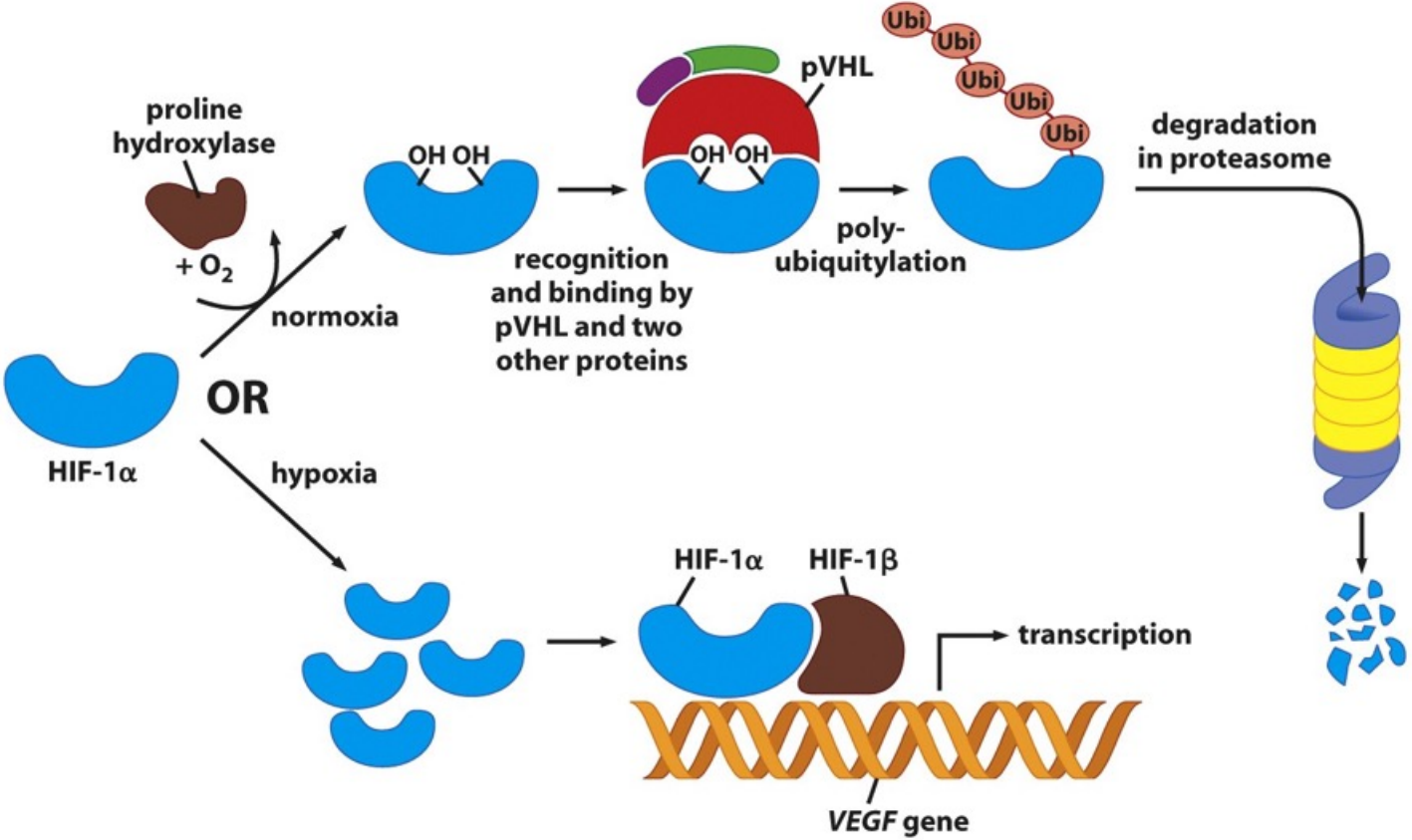
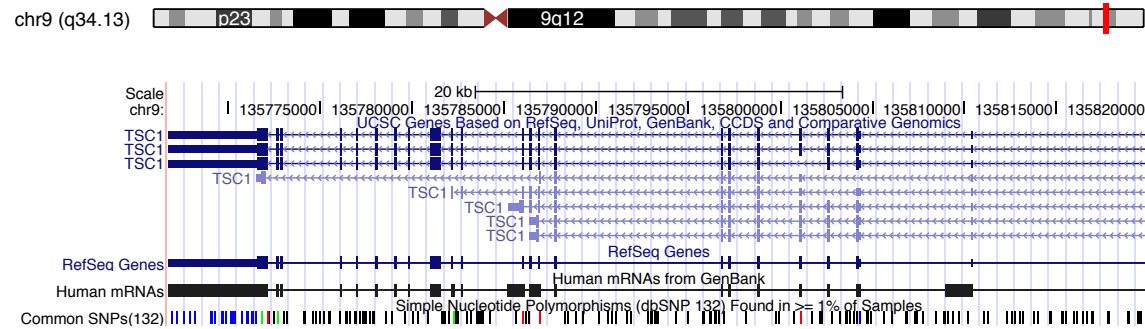


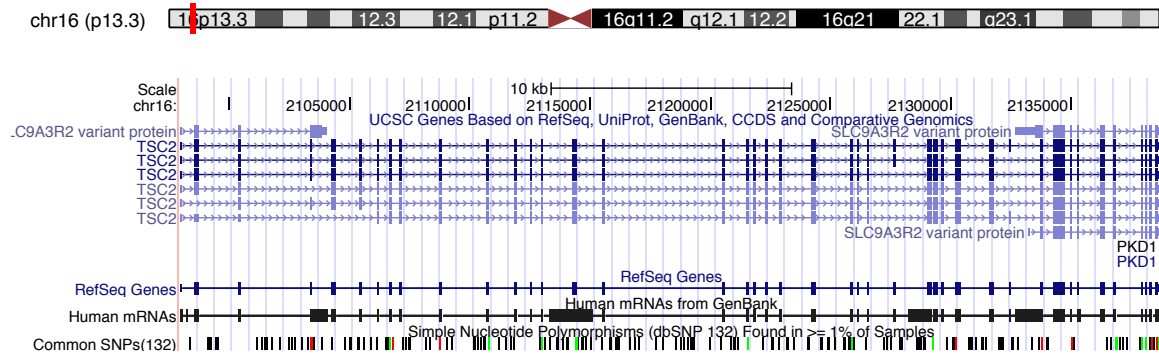
Figure 7.28a *The Biology of Cancer* (© Garland Science 2007)

# Tuberous Sclerosis (TSC)

## TSC1 – 9q34



## TSC2 – 16p13



## Tuberous Sclerosis (TSC)

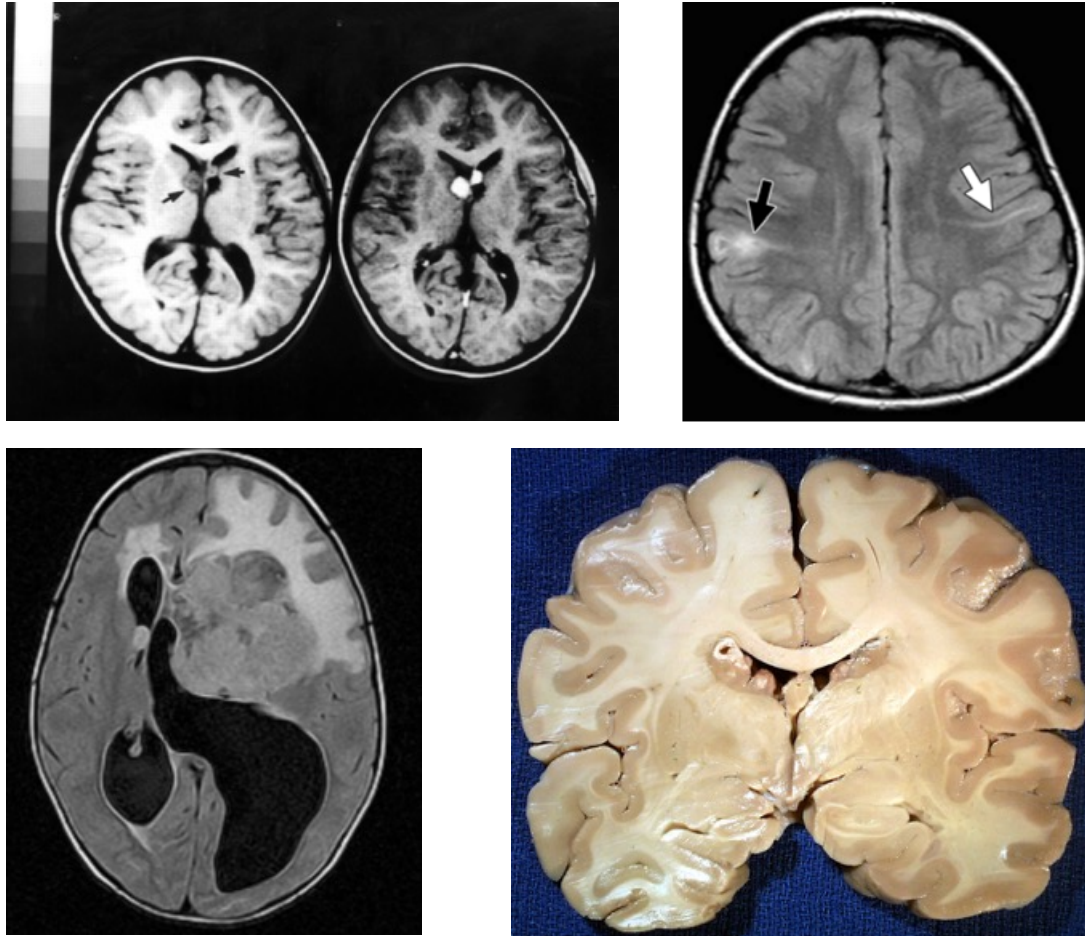
- De novo mutations
- Autosomal dominant
- Gonadal mosaicism (blood test will not reveal mutation)

# Tuberous Sclerosis (TSC)

- Brain
  - Cortical tubers
  - Subependymal nodules
  - SEGA
- Renal
  - Cysts & angiomyolipomas (70-80% patients)
  - RCC, oncocytomas
  - Bleeding from cysts and AML
- Cardiac rhabdomyomas
- Skin
  - Hypomelanotic macules (ash leaf spots)
  - Facial angiofibromas (also called adenoma sebaceum)
  - Forehead plaques
  - Shagreen patches (lower back or nape of neck)
  - Ungual or subungual fibromas (can cause bleeding)
- Other organs affected
  - Liver, lung, pancreas, bone cysts, rectal polyps, gum fibromas, dental pits



## Tuberous Sclerosis (TSC)



## Tuberous Sclerosis (TSC)

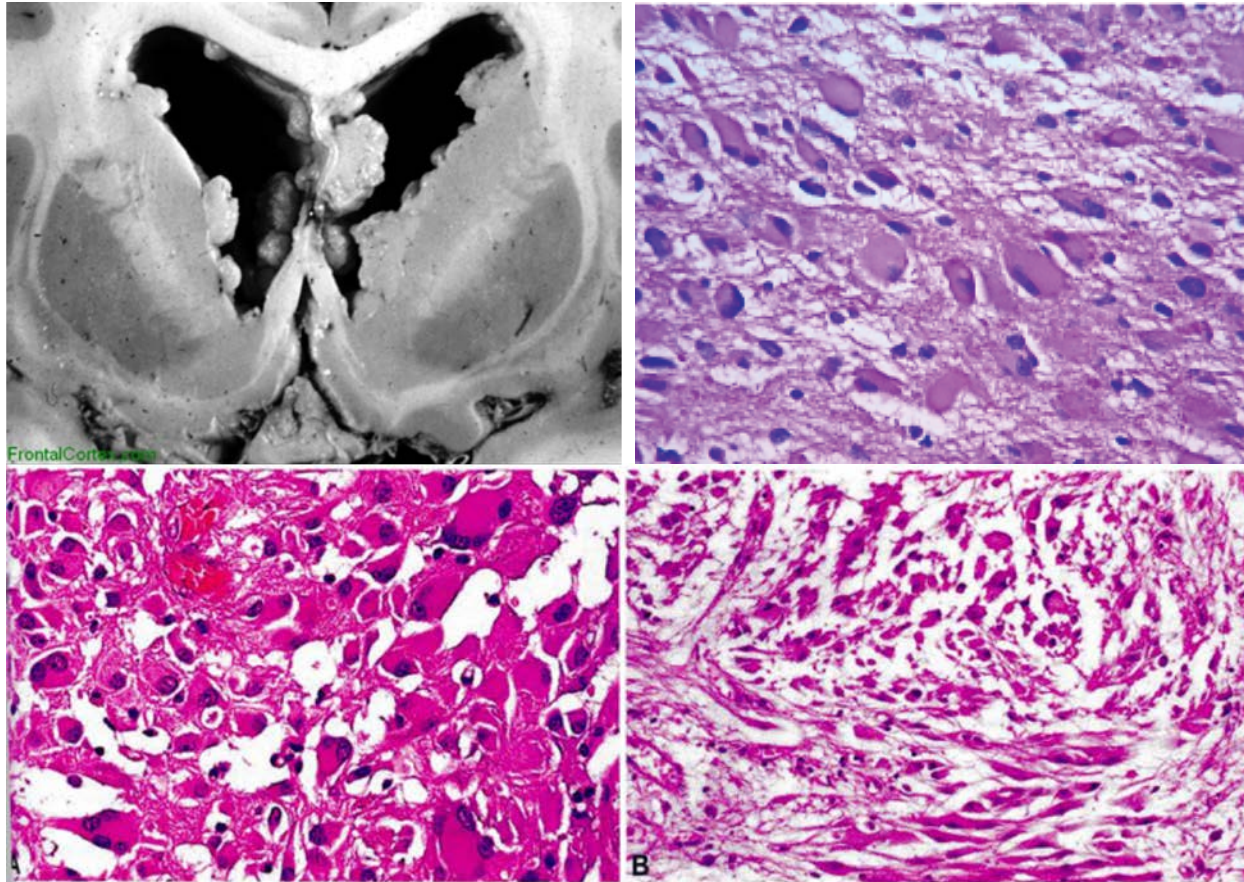
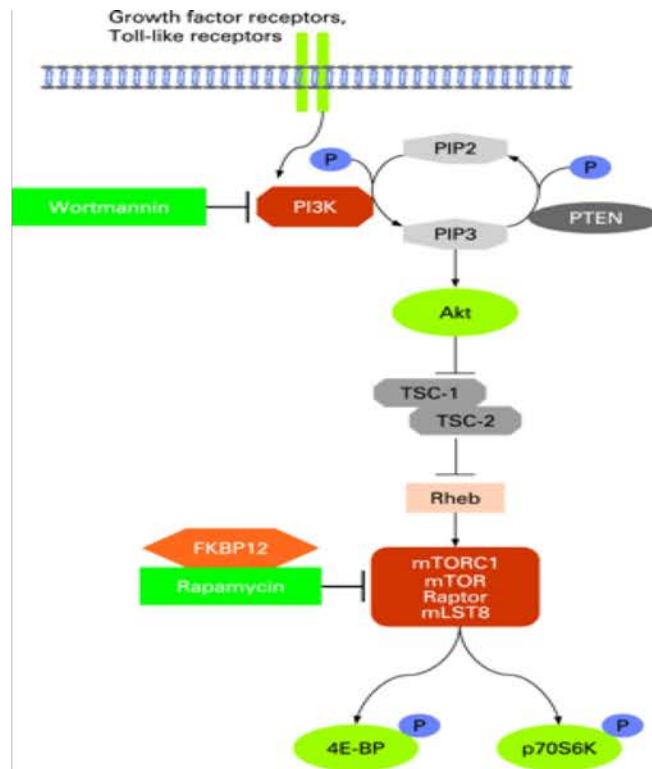


Fig. 13.23 Histological features of subependymal giant cell astrocytoma. **A** Pleomorphic multinucleated eosinophilic tumour cells. **B** Elongated tumour cells forming streams.

# Tuberous Sclerosis (TSC)



# Tuberous Sclerosis (TSC)

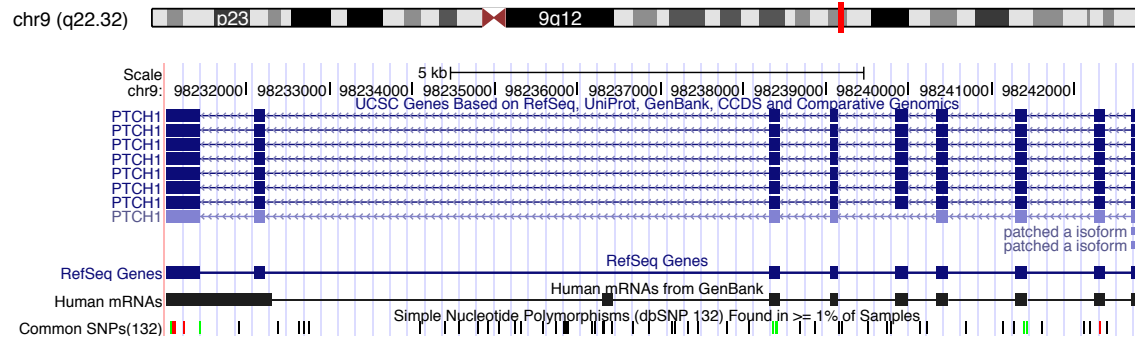
ORIGINAL ARTICLE

## Everolimus for Subependymal Giant-Cell Astrocytomas in Tuberous Sclerosis

Darcy A. Krueger, M.D., Ph.D., Marguerite M. Care, M.D.,  
Katherine Holland, M.D., Ph.D., Karen Agricola, F.N.P., Cynthia Tudor, P.N.P.,  
Prajakta Mangeshkar, M.S., Kimberly A. Wilson, M.S., Anna Byars, Ph.D.,  
Tarek Sahmoud, M.D., Ph.D., and David Neal Franz, M.D.

# Gorlin Syndrome (Nevoid Basal Cell Carcinoma Syndrome - NBCCS)

- PTCH1 - 9q22

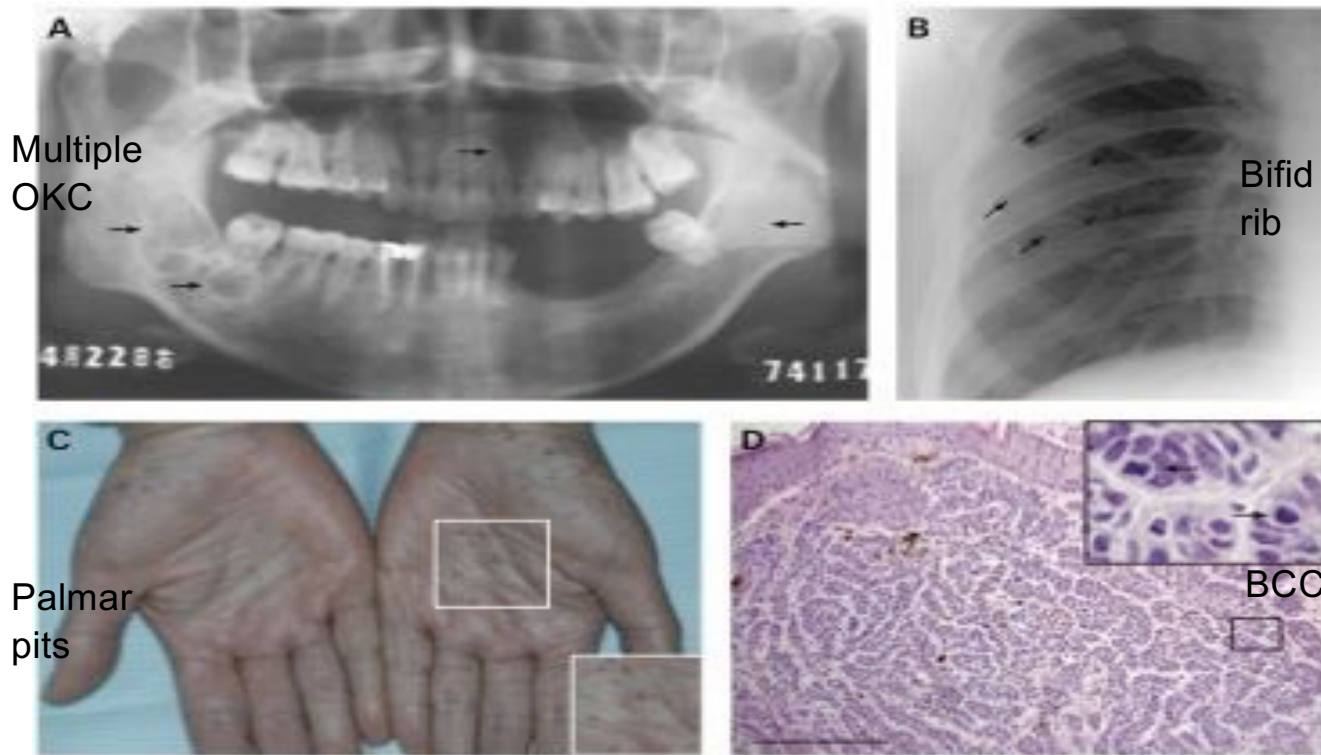


- Autosomal dominant
- 160kd

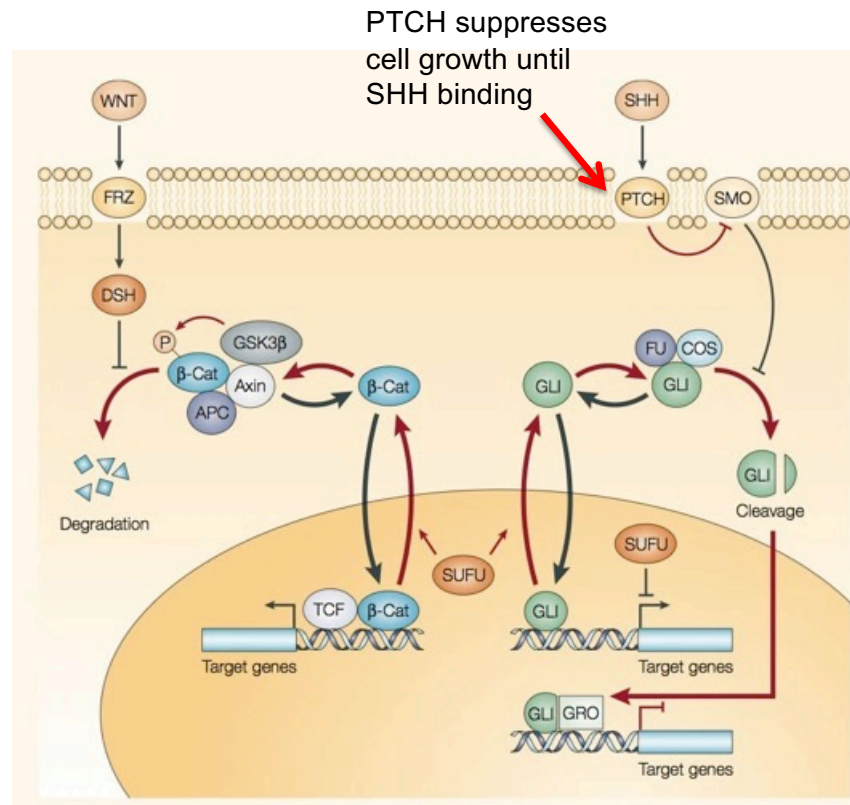
## Gorlin Syndrome (NBCSS)

- Prevalence 1:57000
- Medulloblastoma (desmoplastic variant)
- Basal cell carcinomas
  - Face, chest, back
  - Number of tumour varies between affected patients
- Keratocystic odontogenic tumours of the jaw
- Ovarian fibromas (fertility)
- Cardiac fibromas
  - Outflow obstruction, arrhythmia

# Gorlin Syndrome - NBCCS



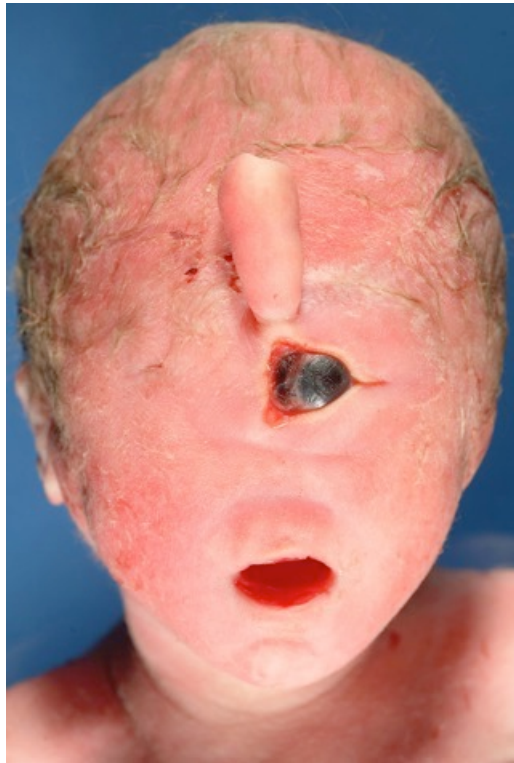# Gorlin Syndrome - NBCCS





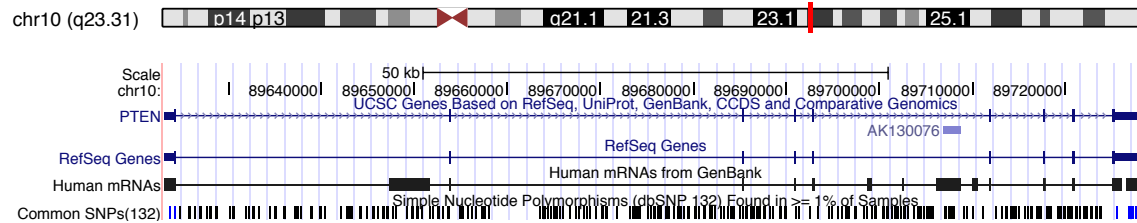
## PTCH1 is also involved in holoprosencephaly

Cyclopia, proboscis, nasal agenesis



## Lhermitte- Duclos Syndrome (Cowden disease)

- PTEN – 10q23

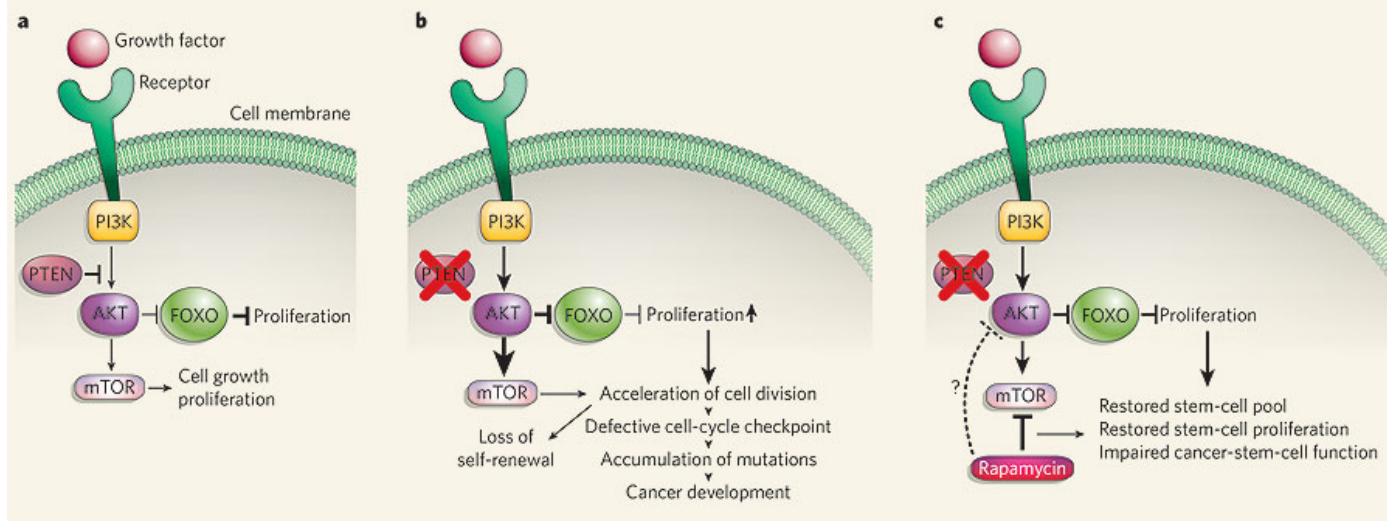


- Autosomal dominant
- Bannayan-Riley-Ruvalcaba Syndrome
  - Triad of macrocephaly, lipomatosis, angiomas
- Macrocephaly

## Lhermitte- Duclos Syndrome (Cowden disease)

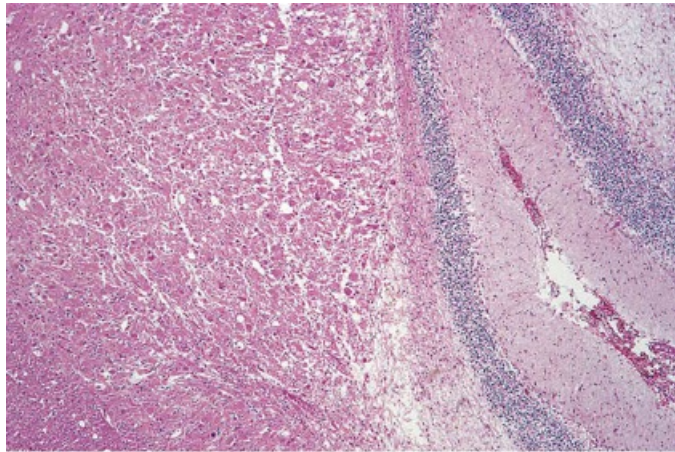
- Incidence of Cowdon syndrome is 1: 250,000
- Multiple hamartomas in tissues from all 3 germ layers
- Trichilemmoma, **adult-onset dysplastic gangliocytoma of CBx** are pathognomonic for germline mutations in *PTEN*
- Increased risks of cancers
  - Breast, non- medullary thyroid, endometrial
- 1.2 kb transcript – 47 kd
- 30-40% germline mutations in exon5 – abrogate PTPase function (65% mutations in exons 5, 7, 8)

## Lhermitte-Duclos disease (PTEN)

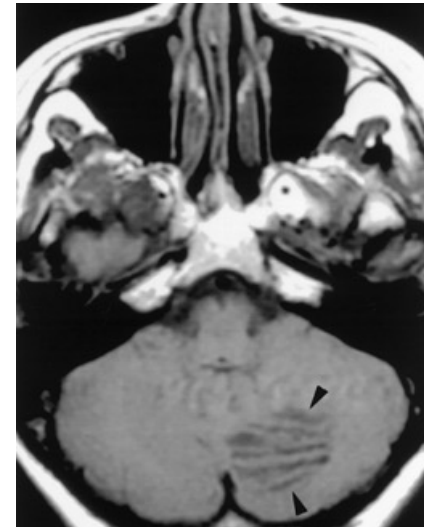
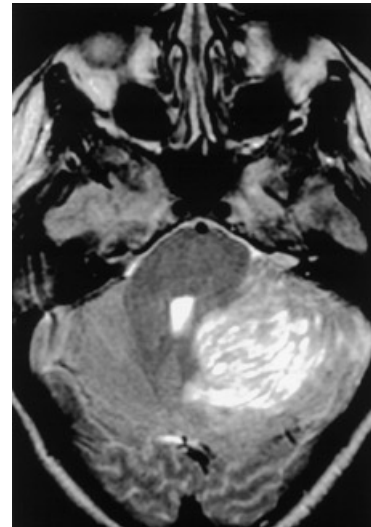


PTEN normally regulates signals promoting cell growth and proliferation

## Lhermitte-Duclos disease (PTEN)



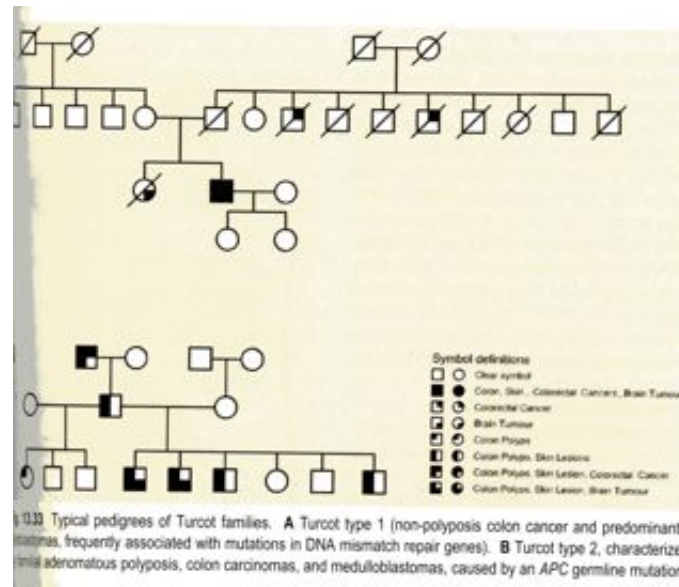
© 2006 Elsevier Inc.



### WHO I

- Distortion but not destruction of CBx architecture
- Loss of PTEN expression (IHC)
- Increased pAKT and S6
- Hypertrophy rather than hyperplasia

## Mode of transmission of Turcot Disease



### Turcot Type 1

*MSH* genes

NPCC

Colorectal Ca & GBM

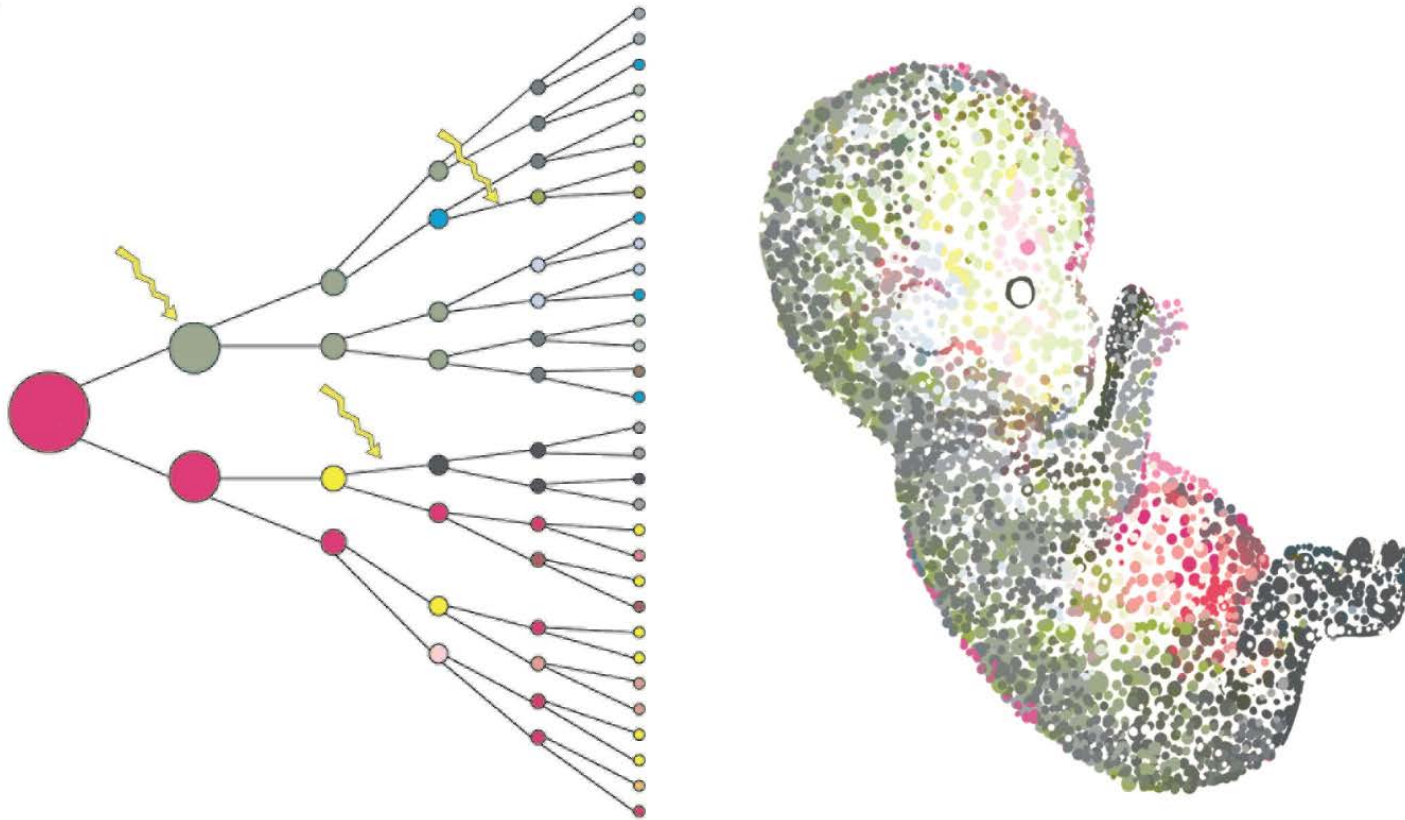
### Turcot Type 2

*APC* gene

FAP, Colorectal Ca,

Medulloblastoma

# Somatic mosaicism



### Parents

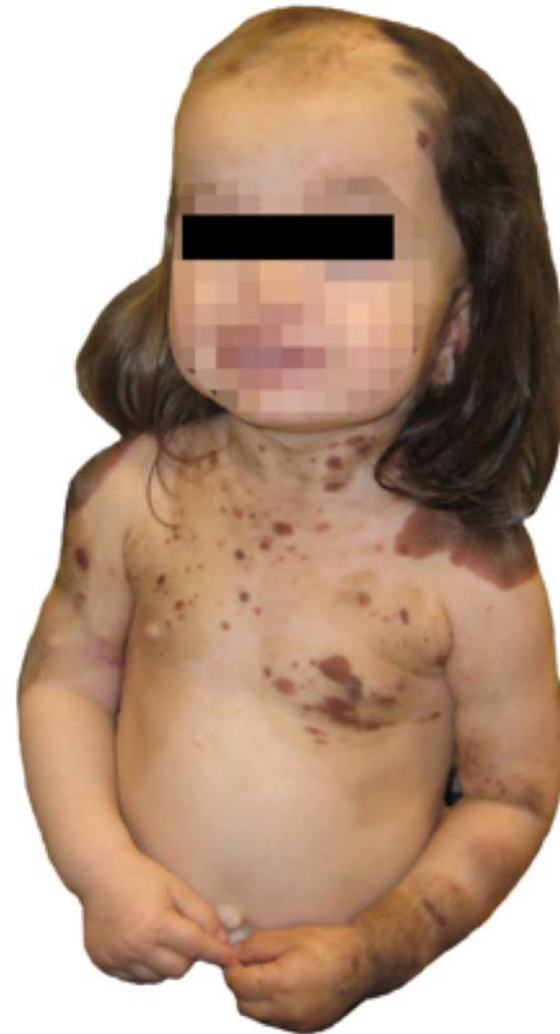- Healthy, non-consanguineous couple
- Uneventful full-term pregnancy

### At birth

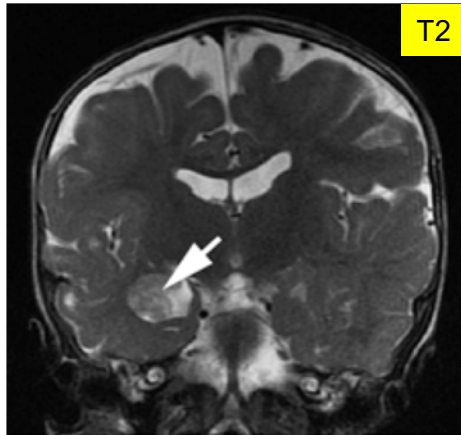
- Multiple hairy melanocytic lesions
- Intradermal and compound nevi with congenital features

### 2 months of age

- Macrocephalic (97<sup>th</sup> percentile)
- Episodes of seizure
- MRI show multiple solid and cystic intracerebral lesions some with features of melanin deposition

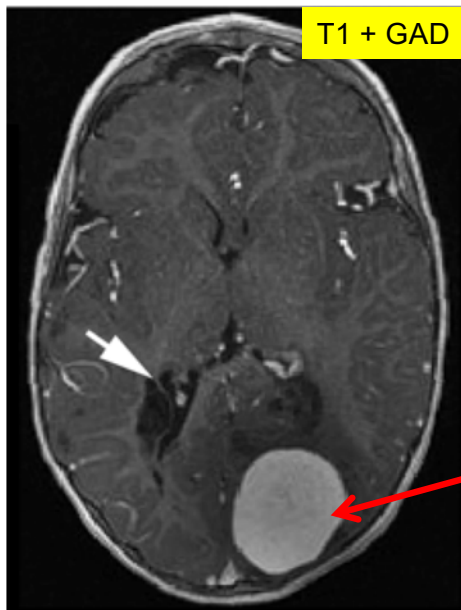






14 months of age

- Right choroid plexus tumour



23 months of age

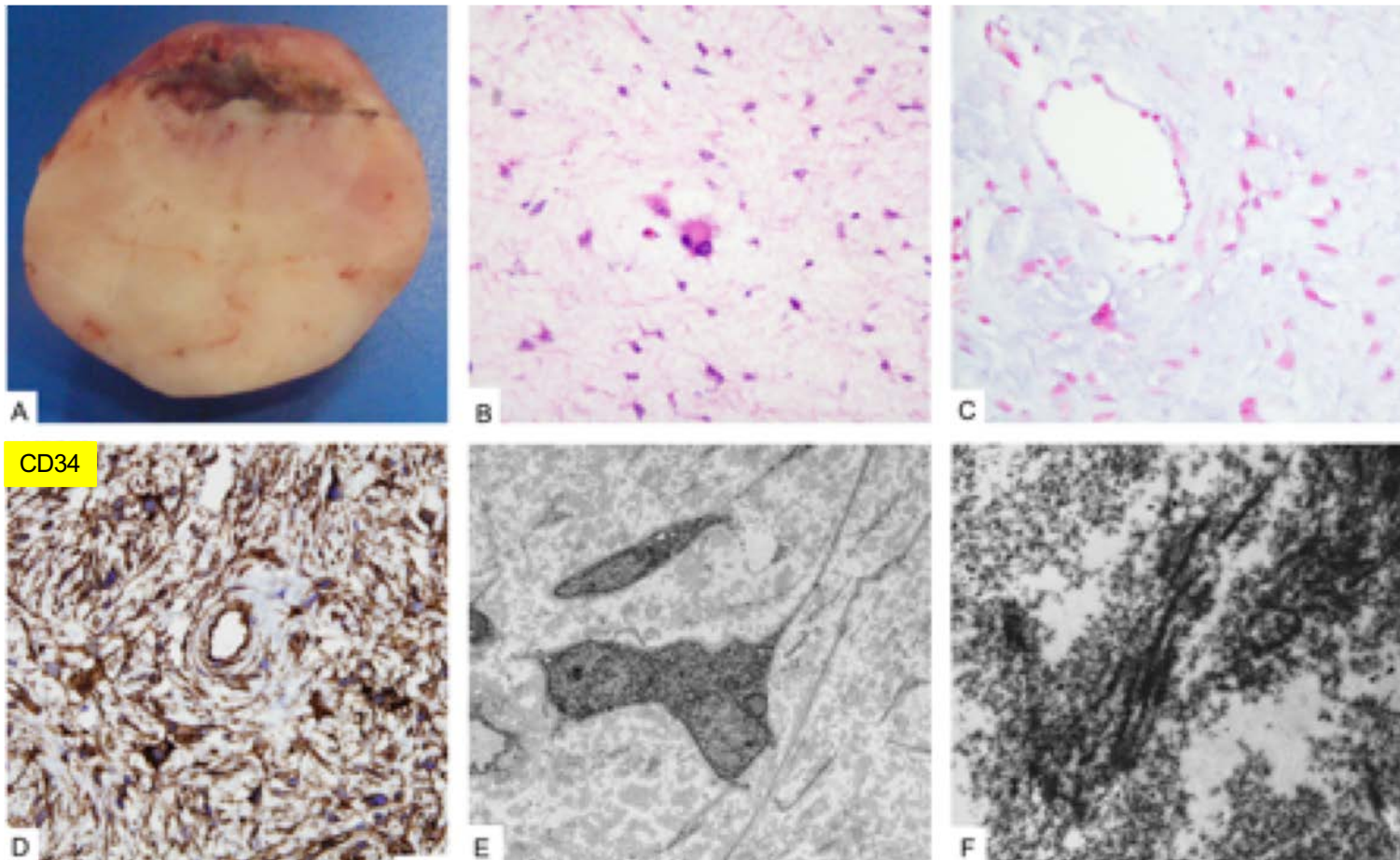
- Left occipital lobe tumour, expanding
- Right periventricular cysts adjacent to occipital horn

24.5 months of age

- Left occipital craniotomy
- Tumour away from dura, single vascular pedicle
- Easily defined tumour/brain interface

Shih F, Yip S, McDonald PJ, Chudley AE, Del Bigio MR. Oncogenic codon 13 NRAS mutation in a primary mesenchymal brain neoplasm and nevus of a child with neurocutaneous melanosis. *Acta neuropathologica communications*. 2014;2(1):140.

## Left occipital tumour resected at 24.5 months of age



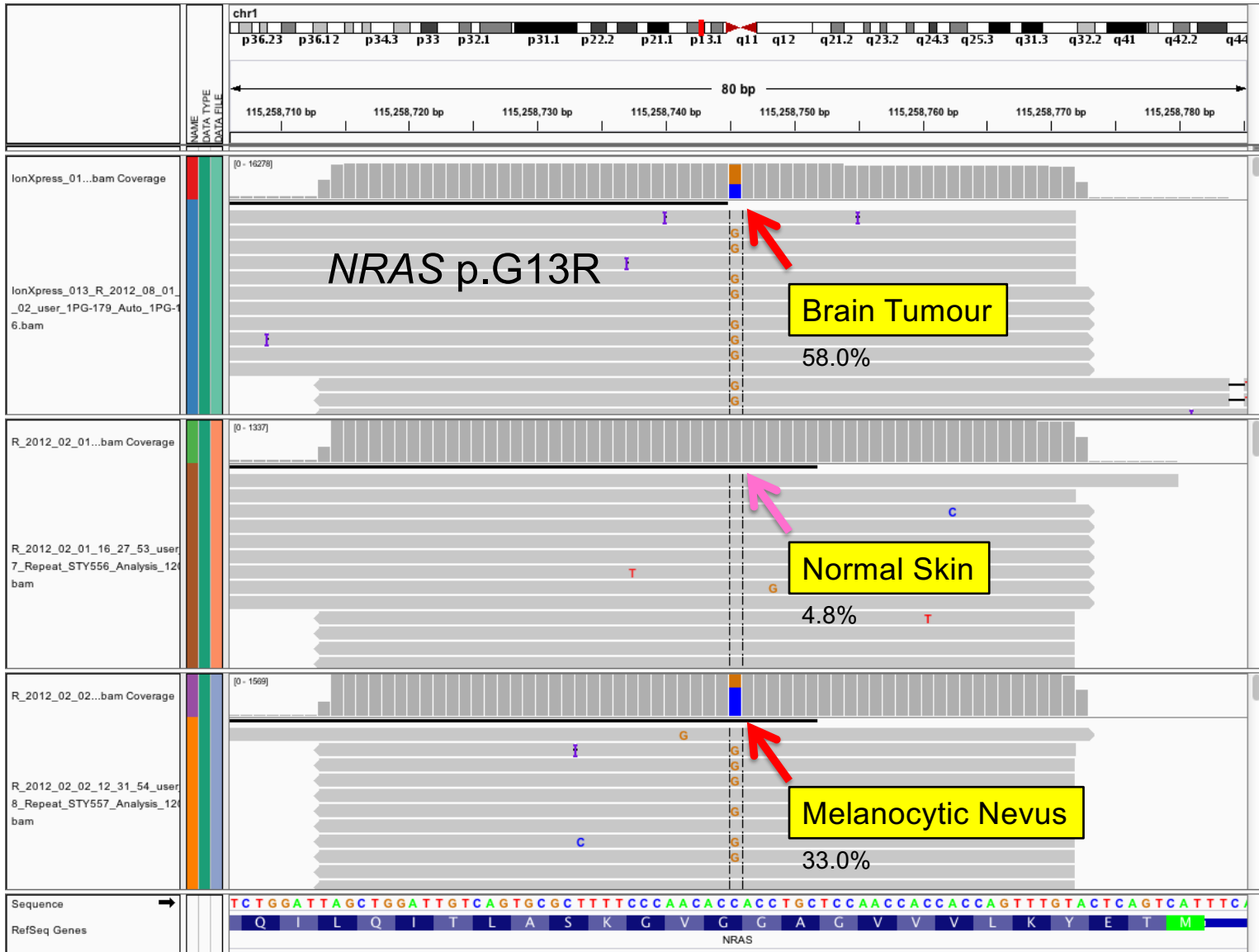
Shih F, Yip S, McDonald PJ, Chudley AE, Del Bigio MR. Oncogenic codon 13 NRAS mutation in a primary mesenchymal brain neoplasm and nevus of a child with neurocutaneous melanosis. *Acta neuropathologica communications*. 2014;2(1):140.

## Left occipital tumour resected at 24.5 months of age

- Stellate and elongated cells in a myxoid background
- NO PIGMENTED CELLS
- Immunopositive for CD34 and vimentin
  
- Dx – Myxoid mesenchymal brain tumour of uncertain growth potential

## Neurocutaneous Melanosis

- Multiple giant cutaneous melanocytic nevi with 5% lifetime risk of transformation
- Extensive leptomeningeal melanosis (30%)
- Epilepsy (50%)
- Dandy Walker Malformation
  
- Approximately 100 cases described in literature
  
- Somatic *NRAS* codon 61 mutation
- Activation of RAS/MAPK pathway




# Allelic frequency of *NRAS* mutation

Gene	<i>NRAS</i>	<i>BRAF</i>
Chr: Position (hg19)	1:115258745	7:140481411
Nucleotide change	c.37G>C	c.1397G>T
Amino Acid change	p.Gly13Arg	p.Gly466Val
Brain Tumour	58.00	0.00
Melanocytic Nevus	33.00	32.00
Normal Skin	4.76	0.00
Patient buccal swab	2.69	0.00
Mother buccal swab	0.00	0.00
Father buccal swab	0.00	0.00

Shih F, Yip S, McDonald PJ, Chudley AE, Del Bigio MR. Oncogenic codon 13 NRAS mutation in a primary mesenchymal brain neoplasm and nevus of a child with neurocutaneous melanosis. *Acta neuropathologica communications*. 2014;2(1):140.

## Allelic frequency of *BRAF* mutation

Gene	<i>NRAS</i>	<i>BRAF</i>
Chr: Position (hg19)	1:115258745	7:140481411
Nucleotide change	c.37G>C	c.1397G>T
Amino Acid change	p.Gly13Arg	p.Gly466Val
Brain Tumour	58.00	0.00
Melanocytic Nevus	33.00	32.00
Normal Skin	4.76	0.00
Patient buccal swab	2.69	0.00
Mother buccal swab	0.00	0.00
Father buccal swab	0.00	0.00



# Somatic mosaicism

- Not all cells in the body are genetically identical
- Assaying one tissue will not reflect the genetic state of the diseased tissue
- Can be a mechanism of disease with characteristic features (syndromic)
  - Proteus, Maffucci, CLOVES, Sturge-Weber
- Genomic
  - Mutations and copy number changes
- Epigenomic
  - Methylation, chromatin marks
- Low frequency events can be difficult to resolve using traditional techniques



## Familial brain tumour syndromes

---

Autosomal dominant transmission

---

Tumour suppressor gene – Dominant negative effect

---

Often involves other systems esp. phakomatosis

---

General cancer vs brain tumour predisposition syndromes

---

Unique pathways affected could be targeted with selective inhibitors